

Intrapericardial teratoma excision in a preterm infant following in-utero pericardiocentesis

Intrauterin perikardiyosentez sonrası prematür bebekte intraperikardiyal teratom eksizyonu

Zeynep Eyileten,¹ Anar Aliyev,¹ Fikri Demir,² Acar Koç,³ Ercan Tutar,² Semra Atalay,² Adnan Uysalel¹

Departments of ¹Cardiovascular Surgery, ²Pediatric Cardiology and ³Obstetrics and Gynecology, Medical Faculty Ankara University, Ankara, Turkey

We present a multidisciplinary treatment approach for a preterm case of a giant intrapericardial teratoma accompanied by significant pericardial effusion, who was managed in prenatal and neonatal period. Identical twin sibling of the patient was healthy. The infant required in-utero pericardiocentesis for signs of tamponade before delivery by cesarean section. The preterm infant had surgical removal of the tumor during cardiac surgery on the second day of the life. The pathological examination was reported as an immature teratoma. The patient was uneventful postoperatively.

Key words: Intrapericardial; pericardiocentesis; prenatal; preterm infant; teratoma.

Fetal ve yenidoğan döneminde multidisipliner yaklaşımla tedavi edilen, önemli perikardiyal efüzyonun eşlik ettiği dev intraperikardiyal teratom olgusu sunuldu. Hasta, ikiz eşi olup, diğer kardeş sağlıklıydı. Fetüse sezeryan ile doğum öncesinde tamponad bulguları nedeniyle intrauterin perikardiyosentez gereksinimi oldu. Prematür bebek, yaşamın ikinci gününde kalp ameliyatına alınarak tümör eksize edildi. Patolojik inceleme sonucu immatür teratom olarak bildirildi. Hasta ameliyat sonrası sorunsuzdu.

Anahtar sözcükler: İntraperikardiyal; perikardiyosentez; prenatal; prematür bebek; teratom.

Teratomas are the second most common intrapericardial tumors after rhabdomyomas, accounting for 23% of the tumors identified in the fetus.^[1] They can be found in 5 out of every 10,000 children, but this could be an underestimation since many children remain asymptomatic.^[2] Since Joel^[3] first described cardiac teratomas in 1890, intrapericardial teratomas have been classically identified during the postpartum period by the presence of neonatal cardiovascular and respiratory distress. However, technical advances in fetal ultrasonography (USG) have led to earlier identification over the course of prenatal development.

CASE REPORT

A fetal ultrasound of a 35-year-old primigravida at the 29th gestational week revealed a cardiac mass in

one of the twin fetuses that was associated with a large pericardial effusion. This was found even though the initial ultrasound revealed a normal pregnancy (Figure 1). The 4x4x3 cm intrapericardial soft tissue mass with small cystic components was in close proximity to the external wall of the right atrium. In addition, it was shifting structurally from the normal heart to the left in the mediastinum. Since the enlarged pericardial area virtually filled approximately 80% of the fetal chest and was causing marked compression of the fetal lungs, severe cardiopulmonary distress in the immediate neonatal period was anticipated. Therefore, in-utero pericardiocentesis (PC) was performed to prevent or delay the development of cardiac tamponade and hydrops fetalis. This yielded 30 ml of serous fluid, which resulted in full pulmonary reexpansion. Furthermore, the cytology of the fluid showed only mesothelial cells. One week after the administration



Available online at
www.tgkdc.dergisi.org
doi: 10.5606/tgkdc.dergisi.2014.7595
QR (Quick Response) Code

Received: August 17, 2012 Accepted: November 24, 2012

Correspondence: Zeynep Eyileten, M.D. Ankara Üniversitesi Tıp Fakültesi Kalp ve Damar Cerrahisi Anabilim Dalı, 06100 Sıhhiye, Ankara, Turkey.

Tel: +90 312 - 595 60 84 e-mail: zeyileten@gmail.com

of corticosteroids, the infant was delivered by cesarean section. The 1500 g female newborn was stable with an Apgar score of 8/9 after one minute. Her echocardiogram demonstrated a large, cystic intrapericardial mass to the right of the right atrium attached to the ascending aorta. Additionally, a serum alpha-fetoprotein (AFP) level of 54,000 $\mu\text{g/L}$ was detected at birth preoperatively, and this was used as a tumor marker.

The infant was brought to the operating room on the second day of life. After sternotomy and pericardiectomy, a large amount of pericardial effusion and a huge (4x5x5 cm), well encapsulated, multicystic mass was found at the right side of the heart. Moreover, it was severely adhered to the base of the ascending aorta above the right coronary artery (Figure 2).

The tumor was completely resected using electrocautery with cardiopulmonary bypass (CPB) on standby. The postoperative course was uneventful, and a histopathological examination of the specimen confirmed the presence of a grade 1 immature teratoma. In the follow-up, the AFP levels progressively decreased (46,996 $\mu\text{g/L}$ on postoperative day seven and 864 $\mu\text{g/L}$ after three months), and were normalized six months later. Echocardiography at the postoperative fifth and 15th months were normal, and chest CT five months after the resection revealed no signs of tumor recurrence. At the 17-month follow-up, the infant continued to be asymptomatic with a serum AFP level of 24 $\mu\text{g/L}$, and she remained free of recurrence on echocardiography.

DISCUSSION

Teratomas in newborns usually occur in the sacrococcygeal area, testis, ovaries, neck, or

intracranium. Intrapericardial teratomas are a rare but potentially fatal occurrence and are usually associated with an increased amount of pericardial effusion. The tamponade that can occur because of the pericardial effusion and/or the mass effect that often results from the tumor itself can lead to fetal cardiovascular compromise, resulting in early intrauterine fetal hydrops in the majority (77%) of affected fetuses. Diagnosing the problem in the early stages and making a quick decision regarding treatment can save lives because intrapericardial teratomas are frequently missed on the routine second trimester scan because of their rapid growth between the gestational 20th and 40th weeks.^[4] Despite technical advances in intrauterine echocardiography, diagnosis these teratomas is difficult before the 23rd gestational week. Our patient was diagnosed at the 29th week. If hydrops develops early in the gestational period, the placement of a pericardioamniotic shunt is an alternative treatment option, but PC is the most frequently used antenatal intervention because it can be used to treat cardiac tamponade. In addition, it allows for fetal development and can be used in the diagnosis of this type of tumor. To date, 14 out of 49 cases in the literature used fetal PC to treat prenatally-diagnosed intrapericardial teratoma. In our case, PC was performed at the 31st gestational week to prevent the development of tamponade and confirm the diagnosis. Only one of the 14 cases who underwent PC died perinatally, and this was due to progressive, severe hydrops. In addition, another had to be aborted immediately after the procedure. The results of PC are promising, but there is limited available data; hence, further evaluation of its efficacy is needed. Because a rise in cardiac

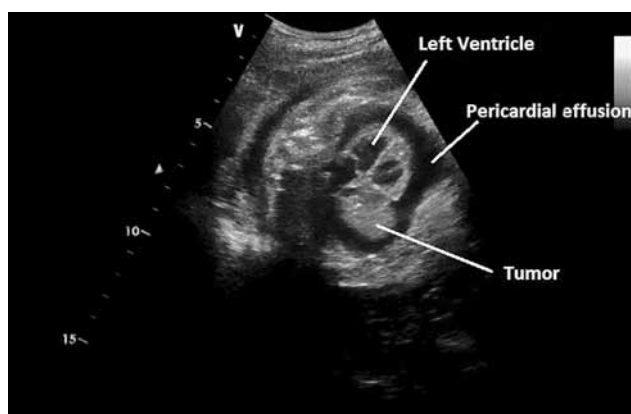


Figure 1. Fetal echocardiography showing the intrapericardial cystic mass and effusion.

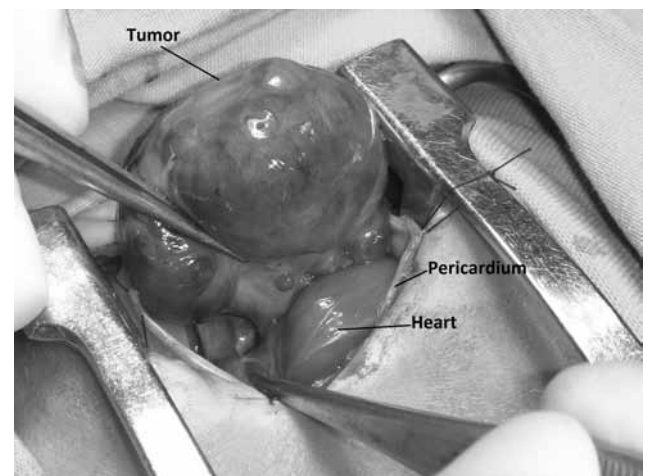


Figure 2. Operative picture, showing the large intrapericardial tumor at the base of the heart.

compression during vaginal delivery may result in fatal chest and heart compression, we delivered the infant by cesarean section one week after the procedure because of preterm labor.

This case is also unusual because the patient was a twin and needed careful management to balance the requirements of the other twin. A search of Pubmed revealed nine other cases of intraperitoneal teratoma that involved multiple pregnancies. Of the nine, one was pregnant with twins, and another with identical triplets. Although there was no mention of the zygosity in those twins, our twins were identical.^[5]

Fetal surgery has also been attempted in cases of intrapericardial teratoma, but the treatment of choice is surgical removal of the tumor in the neonatal period, which has had excellent results. Intrapericardial teratomas are frequently seen in the anterior mediastinum, with the majority of them (90%) attached to the heart or great vessels by a pedicle. Complete surgical excision can usually be accomplished easily, and CPB is not required due to the lack of myocardial involvement, as was the case with our patient.^[6] Pericardiocentesis for tamponade secondary to a fetal intrapericardial teratoma, even when complicated by a twin pregnancy, may prevent fetal death and allow for elective postnatal surgery.

Alpha-fetoprotein is a valid tool for both diagnosis and postoperative monitorization of a possible recurrence. In our case, although the surgical removal was complete, the histological aspects warranted continued measurements of the serial AFP during the long-term follow-up.

This case involved the successful treatment of intrapericardial teratoma using a multidisciplinary approach. Therefore, the follow-up and delivery of such babies should be induced in a third-level center with a pediatric cardiac surgery team on standby.

Declaration of conflicting interests

The authors declared no conflicts of interest with respect to the authorship and/or publication of this article.

Funding

The authors received no financial support for the research and/or authorship of this article.

REFERENCES

1. Holley DG, Martin GR, Brenner JI, Fyfe DA, Huhta JC, Kleinman CS, et al. Diagnosis and management of fetal cardiac tumors: a multicenter experience and review of published reports. *J Am Coll Cardiol* 1995;26:516-20.
2. Sepulveda W, Gómez E, Gutiérrez J. Intrapericardial teratoma. *Ultrasound Obstet Gynecol* 2000;15:547-8.
3. Joel VJ. Ein teratoma auf der arteria pulmonalis innerhalb des herzbeutels. *Anatomie* 1890;122:382.5.
4. Devlieger R, Hindryckx A, Van Mieghem T, Debeer A, De Catte L, Gewillig M, et al. Therapy for foetal pericardial tumours: survival following in utero shunting, and literature review. *Fetal Diagn Ther* 2009;25:407-12.
5. Levin SE, Harrisberg JR, Govendrageloo K. Intrapericardial teratoma in a twin with severe failure to thrive. *Cardiovasc J S Afr* 2002;13:237-40.
6. Oto O, Güzeloğlu M, Kir M, Metin K, Cakmakç H, Albayrak G, et al. Intrapericardial teratoma in a newborn: a case report. *Turk J Pediatr* 2012;54:71-3.