

Fragmented sternum

Parçalı sternum

Nurettin Yiyit,¹ Hasan Saygın²

Departments of ¹Thoracic Surgery, ²Radiology, GMMA Haydarpaşa Training Hospital, İstanbul, Turkey

Twenty-one-year-old two patients with blunt chest trauma history due to traffic accident were admitted to our hospital on different dates. Both patients were evaluated with plain radiographs and computed tomography. Multiple fissure lines on corpus sternum were revealed in the lateral radiographs of each patient (Figure 1a, 2a). Two transverse fissures dividing corpus sternum to three parts were observed in

the computed tomography images of both patients (Figure 1b-d, 2b-d).

Sternal cleft is the fusion defect of the sternum that separates the sternum partially or completely into two vertical parts. Fragmented sternum has not been defined previously. Two sternal cartilaginous bars fuse between 7th and 10th weeks of the fetal life. The cartilaginous sternum ossifies from six

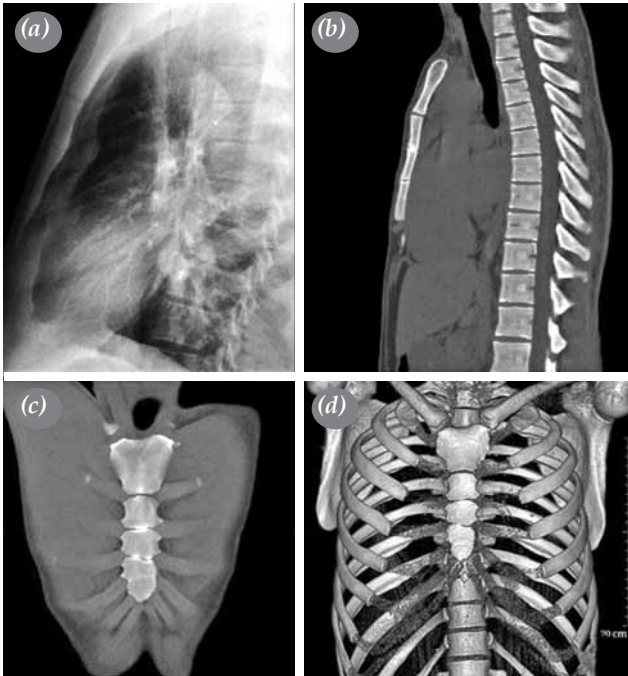

Figure 1. (a) Lateral chest radiograph of first patient demonstrating fissure lines on corpus sternum. (b) Sagittal, (c) coronal (d) and three-dimensional computed tomography images demonstrating transverse fissures dividing corpus sternum to parts.

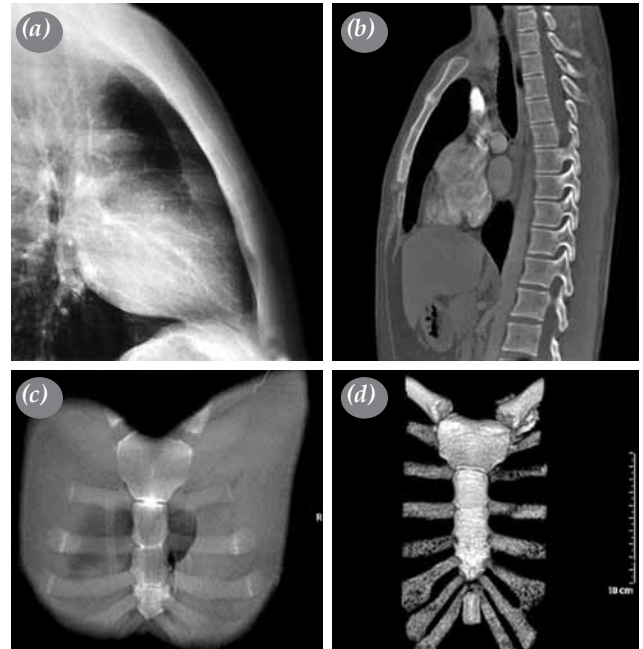


Figure 2. (a) Lateral chest radiograph of second patient demonstrating fissure lines on corpus sternum. (b) Sagittal, (c) coronal and (d) three-dimensional computed tomography images demonstrating transverse fissures dividing corpus sternum to parts.



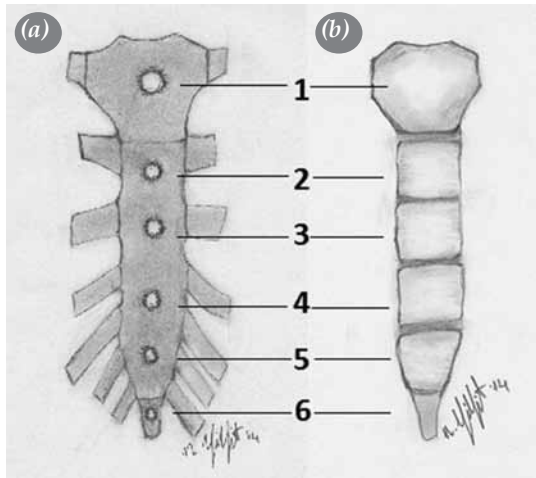


Figure 3. (a) Appearance of six ossification centers of cartilaginous sternum. (b) Appearance of bone segments formed from ossification centers of sternum.

different centers. Two of the six ossification centers are localized in the manubrium and xiphoid process. Other four centers are placed in the corpus sternum

(Figure 3a). The union of bone segments formed from ossification centers of corpus sternum proceeds until the age of 25.^[1] Therefore, the corpus of the sternum might be seen as separated into parts in radiological examinations under the age of 25 (Figure 3b). This finding is not a pathological condition which requires additional treatment or operation. To avoid misdiagnosis especially in trauma patients, fragmented sternum should be known as a normal manifestation of sternal ossification.

Declaration of conflicting interests

The authors declared no conflicts of interest with respect to the authorship and/or publication of this article.

Funding

The authors received no financial support for the research and/or authorship of this article.

REFERENCES

1. Gatzoulis MA. Thorax. In: Standring S, editor. Gray's Anatomy. China: Elsevier; 2008. p. 917-8.