

## Long-term results of surgical repair of congenital heart defects in children with severe pulmonary arterial hypertension treated with perioperative inhaled iloprost

*Perioperatif inhale iloprost ile tedavi edilen ciddi pulmoner arteriyel hipertansiyonlu çocuklarda doğuştan kalp hastalıklarının cerrahi onarımının uzun dönem sonuçları*

Mustafa Paç,<sup>1</sup> Doğan Emre Sert,<sup>1</sup> Sinan Sabit Kocabeyoğlu,<sup>1</sup> İrfan Taşoğlu,<sup>1</sup>  
Ahmet Vedat Kavurt,<sup>2</sup> Feyza Ayşenur Paç<sup>2</sup>

Departments of <sup>1</sup>Cardiovascular Surgery, <sup>2</sup>Pediatric Cardiology,  
Türkiye Yüksek İhtisas Training and Research Hospital, Ankara, Turkey

### ABSTRACT

**Background:** This study aims to evaluate the long-term outcomes of patients with pulmonary arterial hypertension associated with congenital heart disease treated with inhaled iloprost perioperatively.

**Methods:** Between 2008 and 2011, 16 children (10 boys, 6 girls; mean age 4.97 years; range 8 months to 17 years) with a ventricular septal defect and associated severe pulmonary arterial hypertension who had a positive vasoreactivity were administered inhaled iloprost for a mean duration of 40 (range 7 to 90) days before the surgical repair. Inhaled iloprost was used for five days postoperatively. Pulmonary arterial hypertension was diagnosed by right and left heart catheterization and evaluated with echocardiography immediately before the operation, 30 days postoperatively, and annually for five years.

**Results:** The mean systolic and mean pulmonary artery pressures at the initial presentation were 81 (range 51 to 104) mmHg and 60 (range 41 to 77) mmHg, respectively. After the administration of inhaled iloprost, there was a decline of about 18 mmHg according to the echocardiographic findings ( $p<0.05$ ). After surgery, the mean pulmonary arterial pressure additionally decreased by 14 mmHg ( $p<0.05$ ). There was mortality in two patients perioperatively. The remaining patients recovered well and were uneventfully discharged. There was no increase in the postoperative pulmonary artery pressures in discharged children for five years.

**Conclusion:** Inhaled iloprost-induced pulmonary vasodilator response varies among children. The use of inhaled iloprost before and after the surgical repair assures a reduction in pulmonary arterial pressure and decrease cardiovascular complications.

**Keywords:** Acute vasodilator testing; congenital heart disease and surgery; inhaled iloprost; pulmonary vasoreactivity.

### ÖZ

**Amaç:** Bu çalışmada perioperatif inhale iloprost ile tedavi edilen doğuştan kalp hastalığı ilişkili pulmoner arteriyel hipertansiyonu olan hastaların uzun dönem sonuçları değerlendirildi.

**Çalışma planı:** 2008 - 2011 yılları arasında, ventriküler septal defekt ve ilişkili şiddetli pulmoner arteriyel hipertansiyonu olan, vazoreaktivite testi pozitif toplam 16 çocuğa (10 erkek, 6 kız; ort. yaş 4.97 yıl; dağılım 8 ay-17 yıl), cerrahi onarım öncesinde ortalama 40 (dağılım 7-90) gün süreyle inhale iloprost uygulandı. İnhaler iloprost, ameliyat sonrasında beş gün süreyle kullanıldı. Pulmoner arteriyel hipertansiyon tanısı, sağ ve sol kalp kateterizasyonu ile konuldu ve ameliyattan hemen önce, sonrasında 30. günde ve beş yıl boyunca yıllık olarak ekokardiyografi ile değerlendirildi.

**Bulgular:** İlk başvuru esnasında ortalama sistolik ve ortalama pulmoner arter basınçları sırasıyla 81 (dağılım 51-104) mmHg ve 60 (dağılım 41-77) mmHg idi. İnhaler iloprost uygulamasından sonra, ekokardiyografik bulgulara göre, yaklaşık 18 mmHg düşüş izlendi ( $p<0.05$ ). Ameliyattan sonra ortalama pulmoner arter basıncı 14 mmHg daha düştü ( $p<0.05$ ). Ameliyat sırası dönemde iki hastada mortalite gözlemlendi. Geri kalan hastalar iyileşti ve sorunsuz olarak taburcu edildi. Taburcu edilen hastalarda beş yıl boyunca ameliyat sonrası pulmoner arter basınçlarında yükselme gözlemlenmedi.

**Sonuç:** İnhaler iloprost ile elde edilen pulmoner vazodilatör yanıt çocuklar arasında değişkendir. Cerrahi onarımdan önce ve sonra inhale iloprost kullanımı, pulmoner arter basıncında düşüş sağlar ve kardiyovasküler komplikasyonları azaltır.

**Anahtar sözcükler:** Akut vazodilatör test; doğuştan kalp hastalığı ve cerrahisi; inhale iloprost; pulmoner vazoreaktivite.



Available online at  
www.tgkdc.dergisi.org  
doi: 10.5606/tgkdc.dergisi.2017.14198  
QR (Quick Response) Code

Received: December 01, 2016 Accepted: March 29, 2017

Correspondence: Doğan Emre Sert, MD, Türkiye Yüksek İhtisas Eğitim ve Araştırma Hastanesi, Kalp ve Damar Cerrahisi Kliniği, 06230 Altındağ, Ankara, Turkey.

Tel: +90 555 - 319 45 89 e-mail: dodosert@gmail.com

©2017 All right reserved by the Turkish Society of Cardiovascular Surgery.

Pulmonary arterial hypertension (PAH) is an important factor for morbidity and mortality in children with ventricular septal defects.<sup>[1,2]</sup> Due to the increase of pulmonary blood flow, progressive and serious structural changes in the vessel wall can occur including extensive intimal changes, adventitial fibrosis, and loss of intra-acinar arteries. Thus, pulmonary artery pressure (PAP) increases, which can lead to progressive heart failure and death.<sup>[3]</sup> Pulmonary hemodynamic parameters are, therefore, used to decide whether surgical correction is indicated. In some cases, despite surgical repair, pulmonary vascular disease continues to progress or the overall operative risk is associated with a very poor outcome.<sup>[4]</sup> Prior to surgery, the medical team must assess the pulmonary vasoreactivity and reversibility to choose the optimal way for patients with serious PAH who are at the edge of inoperability, and administer agents such as nitric oxide, prostacyclin, and bosentan to make them eligible for surgery.<sup>[3-5]</sup>

Prostacyclin is a pulmonary vasodilator and can be administered intravenously or via a nebulizer. It affects through a secondary messenger system and decreases calcium levels intracellularly with subsequent vasodilatation. Inhaled iloprost is a stable prostacyclin and can be used in children with pulmonary arterial hypertension.<sup>[3,4,6]</sup>

In the present study, we aimed to evaluate the long-term outcomes of patients with PAH and congenital heart disease (CHD) treated with inhaled iloprost perioperatively.

## PATIENTS AND METHODS

A total of 16 children (10 boys, 6 girls; mean age 4.97 years; range 8 months to 17 years) with a ventricular septal defect and associated severe PAH who had a positive vasoreactivity were administered inhaled iloprost before the surgical repair.<sup>[7,8]</sup> Pulmonary arterial hypertension was defined as a mean PAP of >25 mmHg and severe PAH was defined as a systolic PAP higher than 75% of the systolic aortic pressure.<sup>[8]</sup> Inhaled iloprost (Ventavis™, Bayer Schering Pharma AG, Germany) was administered via a nebulizer for a mean duration of 40 (range 7 to 90) days prior to surgery. The initial dose was 2.5 µg. Dose was increased to 5 µg in those with minimal to no side effects. It was diluted in 0.9% saline and administered in six equal doses using a facial mask, and an OMRON NE-C28 CompAIR Nebulizer (OMRON Healthcare Inc., Lake Forest, IL, USA) for 20 min. During iloprost treatment, echocardiographic measurements were made routinely, and the medical team decided whether

the patient was eligible for surgery. The study protocol was approved by the Ethics Committee of Türkiye Yüksek İhtisas Training and Research Hospital. The study was conducted in accordance with the principles of the Declaration of Helsinki.

Surgery and anesthesia were carried out according to routine practice. We kept on administering inhaled iloprost postoperatively and planned to re-evaluate PAH with echocardiography at the postoperative first week and first month. Pulmonary hypertensive crisis (PHC) was defined as an abrupt increase in systolic pulmonary artery pressure higher than 60% systolic blood pressure associated with cardiopulmonary compromise as reflected by hypoxia and the requirement of immediate medical intervention. During routine follow-up, all patients were assessed with detailed physical examination. Mean time between the first postoperative echocardiographic examination to the first routine detailed follow-up was 35 days. All patients were followed every three months in the first year, every six months for the second year, and annually thereafter up to five years.

## Statistical analysis

The SPSS for Windows version 14.0 (SPSS Inc., Chicago, IL, USA) software package was used for statistical analysis. Continuous variables were expressed in median ± standard deviation (SD), while categorical variables were expressed in percentages. For normally distributed data, the paired samples t-test was used to compare pre- and post-treatment values. The Kaplan-Meier plot was used for the overall survival. A *p* value of <0.05 was considered statistically significant.

## RESULTS

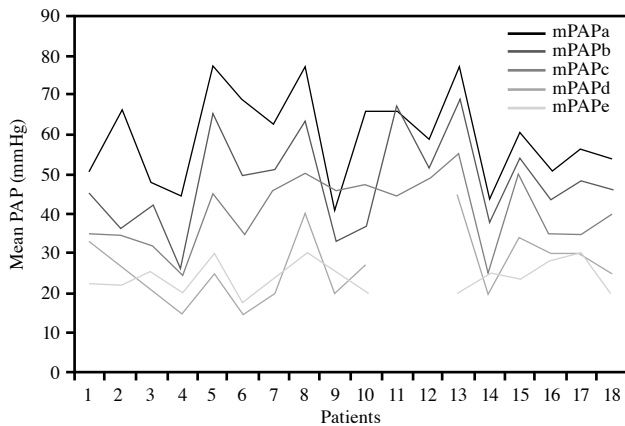
The mean bodyweight was 15.84 (range 4 to 45) kg. At the catheterization lab, the mean baseline PAP was 59.4±11.5 mmHg, the mean pulmonary vascular resistance (PVR) was 6.7±2.8, and the mean ratio of pulmonary to systemic resistance (Rp/Rs) was 0.4±0.2. Baseline characteristics of the patients are shown in Table 1.

The mean PVR decreased from 6.9 to 4.3 (*p*<0.001) and the mean Rp/Rs decreased from 0.4 to 0.2±0.2 (*p*<0.001) after iloprost vasoreactivity testing. All patients were administered inhaled iloprost after catheterization, until surgery was performed. Prior to surgery, the mean PAP decreased to 41.9±8.2 mmHg (*p*<0.001) (Figure 1). Postoperatively, the patients continued to use inhaled iloprost for five days. At 30 days, the mean PAP was 24±4.2 mmHg (*p*<0.001).

**Table 1. Baseline characteristics of patients**

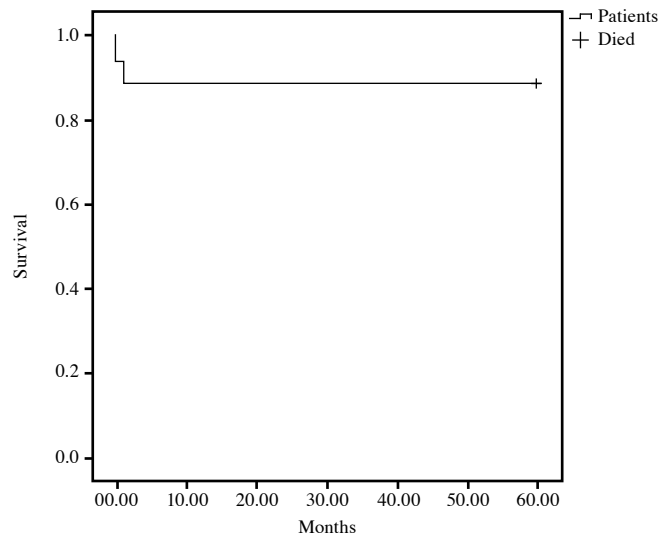
Patient	Age (years)	Weight (kg)	Type of CHD	sPAP(a) mmHg	dPAP(a) mmHg	mPAP(a) mmHg	PVR(a) Wood	sPAP(b) mmHg	dPAP(b) mmHg	mPAP(b) mmHg	PVR(b) Wood	mPAP(c) mmHg	mPAP(d) mmHg	mPAP(e) mmHg	Duration of iloprost therapy (days)
1	9	23	VSD	77	28	51	7.3	66	30	45	6.1	35	33	22	60
2	3	12	VSD	65	30	48	3.6	67	27	42	3.2	32	20	25	60
3	3	11.5	VSD	55	34	45	6.7	30	20	25	4.7	25	15	20	7
4	4	11	VSD	86	66	77	13.1	81	52	65	6.42	45	25	30	30
5	1.5	6	VSD	88	49	69	7.3	74	29	50	5.3	35	15	18	7
6	2	8	VSD	96	36	63	7.4	70	34	51	4.9	46	20	24	7
7	6	22	VSD	93	60	77	8.1	74	51	63	5.48	50	40	30	90
8	8 months	4	VSD	51	31	41	4	53	11	33	0.8	46	20	25	7
9	9	23	VSD	94	39	66	6.3	63	16	37	3.8	47	27	20	60
10*	6	25	VSD	104	32	66	11.5	96	53	67		45			90
11*	7	18	VSD	85	28	59	4.8	74	25	52		49			30
12	3	10	VSD	92	69	77	10.8	81	57	69	7.1	55	45	20	7
13	2.5	11	VSD	88	37	60	6.54	81	36	54	3.2	50	34	24	30
14	17	45	VSD	77	28	51	4.1	68	23	44	1.95	35	30	28	90
15	2.5	12	VSD	82	25	56	5.8	74	20	48	3.4	35	30	30	45
16	3.5	12	VSD	75	35	54	2.79	64	25	46	1.87	40	25	20	21

CHD: Congenital heart disease; sPAP: Systolic pulmonary artery pressure; dPAP: Diastolic pulmonary artery pressure; mPAP: Mean pulmonary artery pressure; PVR: Pulmonary vascular resistance; VSD: Ventricular septal defect; \* Exitus; (a) Denotes to pre-acute vasodilator response test; (b): Post-acute vasodilator response test; (c) Preoperative final echocardiographic data; (d) Postoperative 30<sup>th</sup> day; (e) 5<sup>th</sup> year.



**Figure 1.** Mean pulmonary artery pressures.

PAP: Pulmonary artery pressure; a: Pre-acute vasodilator test; b: Post-acute vasodilator test; c: Preoperative final echocardiography; d: Postoperative first month; e: Postoperative fifth year.



**Figure 2.** Kaplan Meier curve showing survival of patients.

One of the patients died intraoperatively due to PHC. He was followed for 90 days before surgery with inhaled iloprost and the mean PAP decreased from 66 mmHg to 45 mmHg preoperatively. Another patient died at the first month postoperatively during cardiac catheterization due to the pulmonary hypertensive symptoms following surgery. The patient was followed for a month with inhaled iloprost and his initial PAP of 59 mmHg decreased to 49 mmHg before surgery. Fourteen patients recovered well and uneventfully discharged from the hospital. The mean length of hospital stay was 7 days. The Kaplan-Meier survival curve is shown in Figure 2. None of the survivors had any cardiac or respiratory problems throughout follow-up.

## DISCUSSION

Pulmonary arterial hypertension is a severe disease in which pulmonary artery remodeling leads to an increase in the PVR and PAP, eventually resulting in the right ventricular failure and death.<sup>[9]</sup> Despite evolving treatment guidelines and the availability of PAH-targeted therapies, PAH prognosis remains very unfavorable in children.<sup>[10]</sup> On the other hand, in assessing operability in PAH-CHD, there is no established protocol for acute vasodilator testing (AVT) or proven criteria to assess the response with respect to either operability or long-term outcomes.<sup>[11]</sup> Although many studies examined retrospective criteria for operability, such as PVR/systemic vascular resistance (SVR), there is no solid evidence to support the absolute mean PAP, PVR index, or PVR/SVR in response to AVT which determines operability with an adequate sensitivity and specificity to predict a favorable long-term outcome.<sup>[11-13]</sup>

Our study group consisted of adolescents with PAH-CHD who were unable to reach an early medical treatment related to the lower social-economic status. Since PAH was severe in these cases, it was critical to determine if they were eligible for surgery. The use of acute vasodilator challenge has been strongly encouraged, if baseline PVR index is between 6 and 9 Wood units  $\times$   $m^2$  in the presence of a PVR/SVR ratio of about 0.3 to 0.5.<sup>[14]</sup> Our patients had a mean PVR of  $6.7 \pm 2.8$ , and the mean Rp/Rs was  $0.4 \pm 0.2$ . For the assessment of the operability of an individual patient with a CHD and high PVR, there is no consensus as to whether vasoreactivity testing is accurate enough to discriminate between patients who would or would not have a good surgical outcome.<sup>[14]</sup> At this point, our study emphasizes the importance of inhaled iloprost treatment during the medical decision process. Formal hemodynamic assessment with vasoreactivity testing is also important, as patients with lower preoperative PVR and evidence of significant vasoreactivity are likely to be better surgical candidates. Sung *et al.*<sup>[15]</sup> strongly recommended pretreatment with advanced therapies such as iloprost and tolerance to long-term administration before surgery.

In the present study, we administered inhaled iloprost to all patients. Duration of iloprost treatment before surgery varied among the patients, and medical team decided to the time of a surgical approach during regular echocardiographic examinations: if pulmonary hypertension regressed to an acceptable level, surgical correction was allowed.

On the other hand, common adverse effects of inhaled iloprost include cough, headache, flushing, and jaw pain. In their study, Krug et al.<sup>[16]</sup> showed serious side effects such as syncope, tachycardia, pneumonia, and dyspnea in 2 to 5% of the patients. In our study, no acute toxicities related to the inhalation of aerosolized iloprost and no systemic side effects were observed.

Both aerosolized and intravenous infusions of iloprost cause a significant decrease in the mean PAP and PVR. Although intravenous infusion can cause a large decrease in the mean systemic arterial pressure, this is only slightly affected by aerosolized iloprost.<sup>[17]</sup> This is the reason why we preferred inhaled iloprost to intravenous infusion in our study.

The mortality rate associated with PAH has constantly declined over time. Since inhaled nitric oxide (iNO) is established as an additional therapeutic option, the mortality rate of PAH has further declined.<sup>[4,18,19,20]</sup> Despite relatively high mortality rates reported in the literature, two deaths occur in our study population. However, this finding should be confirmed in further large-scale studies, before we conclude that the use of aerosolized iloprost reduces the mortality rates. In addition, one patient had PHC after weaning from cardiopulmonary bypass intraoperatively and died. Another patient was discharged without any complications, but had an increase in PAP values and arrested at the exploratory catheterization; however, the patient did not respond to resuscitation at the first month postoperatively. Since most complications such as PHC and prolonged ventilation occur at the first couple of days after surgery, we continued administering inhaled iloprost for five days following surgery to minimize the risk. All other patients continued to use inhaled iloprost postoperatively for five days. Despite the fact that we observed a generalized decrease in the mean PAP values even below the level immediate after surgery with use of inhaled iloprost, the mean PAP mostly benefits from corrective surgery, and inhaled iloprost surely is an adjunct therapy. There was no increase in the postoperative PAP in discharged children for five years. These data suggest that the majority of children with PAH who undergo surgical repair adjunct with iloprost are likely to have a mean PAP which returns to normal in the long-term. This finding suggests us that high PAP is related to the increased blood flow and concomitant response of pulmonary vascular bed to this flow.

Nonetheless, our study was retrospectively designed and performed at a single center. In addition, inhaled iloprost was not compared with other comparatives

or placebo. Also, although our follow-up duration was satisfactory, further long-term, large-scale, multi-center studies are required to assess the hemodynamic effects of inhaled iloprost and confirm our findings.

In conclusion, aerosolized iloprost treatment significantly reduced the pulmonary arterial pressure in the patients with pulmonary arterial hypertension before repair for congenital heart defects. Aerosolized iloprost may also contribute to a decreased mortality rate. However these results are needed to be confirmed with further well-designed clinical trials.

#### **Declaration of conflicting interests**

The authors declared no conflicts of interest with respect to the authorship and/or publication of this article.

#### **Funding**

The authors received no financial support for the research and/or authorship of this article.

#### **REFERENCES**

1. Olschewski H, Walmrath D, Schermuly R, Ghofrani A, Grimminger F, Seeger W. Aerosolized prostacyclin and iloprost in severe pulmonary hypertension. *Ann Intern Med* 1996;124:820-4.
2. Olschewski H, Ghofrani HA, Walmrath D, Schermuly R, Temmesfeld-Wollbruck B, Grimminger F, et al. Inhaled prostacyclin and iloprost in severe pulmonary hypertension secondary to lung fibrosis. *Am J Respir Crit Care Med* 1999;160:600-7.
3. Hoeper MM, Schwarze M, Ehlerding S, Adler-Schuermeyer A, Spiekerkoetter E, Niedermeyer J, et al. Long-term treatment of primary pulmonary hypertension with aerosolized iloprost, a prostacyclin analogue. *N Engl J Med* 2000;342:1866-70.
4. Rimensberger PC, Spahr-Schopfer I, Berner M, Jaeggi E, Kalangos A, Friedli B, et al. Inhaled nitric oxide versus aerosolized iloprost in secondary pulmonary hypertension in children with congenital heart disease: vasodilator capacity and cellular mechanisms. *Circulation* 2001;103:544-8.
5. Hu Z, Xie B, Zhai X, Liu J, Gu J, Wang X, et al. Midterm results of "treat and repair" for adults with non-restrictive ventricular septal defect and severe pulmonary hypertension. *J Thorac Dis* 2015;7:1165-73.
6. Sung KW, Jeon YB, Kim NY, Park KY, Park CH, Choi CH, et al. The effects of perioperative inhaled iloprost on pulmonary hypertension with congenital heart disease. *Cardiology* 2013;126:224-9.
7. Limsuwan A, Khosithseth A, Wanichkul S, Khowsathit P. Aerosolized iloprost for pulmonary vasoreactivity testing in children with long-standing pulmonary hypertension related to congenital heart disease. *Catheter Cardiovasc Interv* 2009;73:98-104.
8. Ari ME, Örun UA, Karademir S, Özgür S, Ceylan Ö, Kayalı Ş, et al. Pulmonary vasoreactivity testing with inhaled iloprost in children with pulmonary hypertension

- related to congenital heart disease. *Turk Gogus Kalp Dama* 2015;23:222-8.
9. Zijlstra WM, Douwes JM, Rosenzweig EB, Schokker S, Krishnan U, Roofthoof MT, et al. Survival differences in pediatric pulmonary arterial hypertension: clues to a better understanding of outcome and optimal treatment strategies. *J Am Coll Cardiol* 2014;63:2159-69.
  10. Douwes JM, Humpl T, Bonnet D, Beghetti M, Ivy DD, Berger RM. Acute Vasodilator Response in Pediatric Pulmonary Arterial Hypertension: Current Clinical Practice From the TOPP Registry. *J Am Coll Cardiol* 2016;67:1312-23.
  11. Ivy DD, Abman SH, Barst RJ, et al. Pediatric pulmonary hypertension. *J Am Coll Cardiol* 2013;62:117-26.
  12. Balzer DT, Kort HW, Day RW, Corneli HM, Kovalchin JP, Cannon BC, et al. Inhaled Nitric Oxide as a Preoperative Test (INOP Test I): the INOP Test Study Group. *Circulation* 2002;106:76-81.
  13. Giglia TM, Humpl T. Preoperative pulmonary hemodynamics and assessment of operability: is there a pulmonary vascular resistance that precludes cardiac operation? *Pediatr Crit Care Med* 2010;11:57-69.
  14. Beghetti M, Galiè N, Bonnet D. Can “noperable” congenital heart defects become operable in patients with pulmonary arterial hypertension? Dream or reality? *Congenit Heart Dis* 2012;7:3-11.
  15. Sung KW, Jeon YB, Kim NY, Park KY, Park CH, Choi CH, et al. The effects of perioperative inhaled iloprost on pulmonary hypertension with congenital heart disease. *Cardiology* 2013;126:224-9.
  16. Krug S, Sablotzki A, Hammerschmidt S, Wirtz H, Seyfarth HJ. Inhaled iloprost for the control of pulmonary hypertension. *Vasc Health Risk Manag* 2009;5:465-74.
  17. Hallioglu O, Dilber E, Celiker A. Comparison of acute hemodynamic effects of aerosolized and intravenous iloprost in secondary pulmonary hypertension in children with congenital heart disease. *Am J Cardiol* 2003;92:1007-9.
  18. Journois D, Baufreton C, Mauriat P, Pouard P, Vouhé P, Safran D. Effects of inhaled nitric oxide administration on early postoperative mortality in patients operated for correction of atrioventricular canal defects. *Chest* 2005;128:3537-44.
  19. Day RW, Hawkins JA, McGough EC, Crezéé KL, Orsmond GS. Randomized controlled study of inhaled nitric oxide after operation for congenital heart disease. *Ann Thorac Surg* 2000;69:1907-12.
  20. Bando K, Turrentine MW, Sharp TG, Sekine Y, Aufiero TX, Sun K, et al. Pulmonary hypertension after operations for congenital heart disease: analysis of risk factors and management. *J Thorac Cardiovasc Surg* 1996;112:1600-7.