



Case Report / Olgu Sunumu

An attempt to retrieve an embolized ductal closure device leading to iliac artery dissection in an 11-month-old child: A case report

On bir aylık çocukta iliyak arter diseksiyonuna neden olan embolize duktal kapama cihazını çıkarma girişimi: Olgu sunumu

Emrah Şişli¹, Serdar Epçaçan²

¹Department of Pediatric Cardiovascular Surgery, University of Health Sciences, Van Training and Research Hospital, Van, Turkey

²Department of Pediatric Cardiology, University of Health Sciences, Van Training and Research Hospital, Van, Turkey

ABSTRACT

An 11-month-old patient was referred with the diagnosis of Amplatzer duct occluder II embolization to the right common iliac artery during transcatheter patent ductus arteriosus closure procedure, and unsuccessful retrieval. Following extraction of the device through median laparotomy, a graft interposition was compulsorily performed due to right common iliac artery dissection. Transcatheter device occlusion of patent ductus arteriosus with low complication rates has become the preferred treatment modality in children. However, insisting on transcatheter retrieval of an occluder device should be avoided, as the outcomes can be devastating including limb loss, death or need for multiple surgical and/or endovascular procedures in the future.

Keywords: Ductus arteriosus; embolism; patent; vascular closure devices; vascular system injuries.

Transcatheter patent ductus arteriosus (PDA) closure using a duct occluder device is a well-established intervention successfully performed in infants and children with high immediate success rates.^[1,2] Although further developments in device technology has improved over time, there remains considerable and non-negligible complication rates in patients less than one year old.^[1-4] Device embolization is the most frequent complication^[3] which may necessitate emergent surgical removal, when the interventional retrieval of the embolized device is unable to be accomplished. Herein, we

ÖZ

On bir aylık hasta transkateter patent duktus arteriozusun kapama işlemi sırasında sağ ana iliyak artere Amplatzer duct occluder II cihazının embolizasyonu ve başarısız geri çekilmesi tanısı ile sevk edildi. Median laparotomi ile cihazın çıkarılmasını takiben, sağ ana iliyak arter diseksiyonu nedeniyle zorunlu olarak greft interpozisyonu gerçekleştirildi. Patent duktus arteriozusun transkateter cihaz kapaması, düşük komplikasyon oranları ile çocuklarda tercih edilen bir tedavi yöntemi olmuştur. Bununla birlikte, kapama cihazının geri çıkarılmasında ısrar edilmesinden kaçınılmalıdır; zira ekstremitte kaybı, ölüm veya gelecekte çoklu cerrahi ve/veya endovasküler girişim gereksinimi gibi yıkıcı sonuçları olabilmektedir.

Anahtar sözcükler: Duktus arteriozusun; emboli; patent; vasküler kapama cihazları; vasküler sistem yaralanmaları.

present a case of device embolization to the right common iliac artery (RCIA) resulting in iliac artery dissection after unsuccessful transcatheter retrieval.

CASE REPORT

An 11-month-old girl was referred to our center with the diagnosis of acute arterial compromise due to device embolization to the RCIA during a transcatheter PDA closure procedure. The medical history in the referring center included failed transcatheter PDA closure with the embolization of the Amplatzer duct occluder II (ADO-II) (5/4 mm, Amplatzer™ Duct

Received: June 19, 2018 Accepted: October 05, 2018

Correspondence: Emrah Şişli, MD. SBÜ Van Eğitim ve Araştırma Hastanesi Çocuk Kalp ve Damar Cerrahisi Kliniği, 65040 Van, Turkey.

Tel: +90 505 - 598 52 33 e-mail: dresisli@gmail.com

Cite this article as:

Şişli E, Epçaçan S. An attempt to retrieve an embolized ductal closure device leading to iliac artery dissection in an 11-month-old child: A case report. Turk Gogus Kalp Dama 2019;27(1):111-113

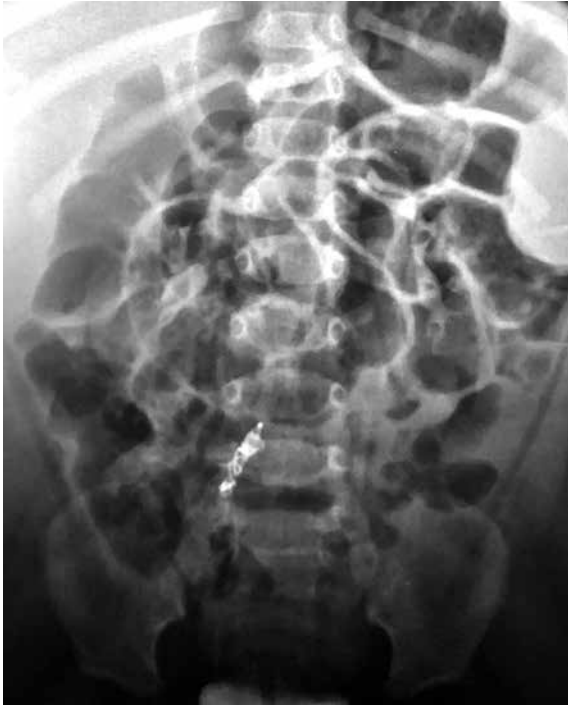

Figure 1. Posteroanterior abdominal X-ray showing embolized duct occluder device with the snare guidewire entwined and squeezed.

Occluder II, St. Jude Medical, Plymouth, MN, USA) to the RCIA (Figure 1). Additionally, the attempts for retrieval of the ADO-II were unsuccessful. We were

also informed that, during the retrieval process, the snare guidewire was entwined around the ADO-II and squeezed.

On admission, the patient had hard signs for vascular compromise including neuromotor deficit. The patient was urgently transferred to the operating room. A written informed consent was obtained from each parent. After median laparotomy, the retroperitoneum overlying the RCIA was divided (Figure 2a). After heparinization (1 mg/kg), the CIA was vertically opened. Along with the snare guidewire, the ADO-II was extracted (Figure 2b). Due to the accompanying arterial dissection, the atriotomy was extended distally, until a healthy segment of intima was reached. The length of the segment of dissection was almost 6-cm long, and an end-to-end anastomosis was not possible. Thus, following the proximal and distal embolectomies accompanied by a good antegrade and retrograde blood flow, a 4-mm polytetrafluoroethylene tube graft interposition with internal iliac artery ligation were performed (Figure 2c). The ischemia time was almost three hours. The postoperative course was uneventful.

On echocardiography, the PDA was small (2-mm in diameter), and the left heart chambers were not enlarged. As the patient was asymptomatic with medications, clinical and echocardiographic follow-up was decided. The patient was discharged on

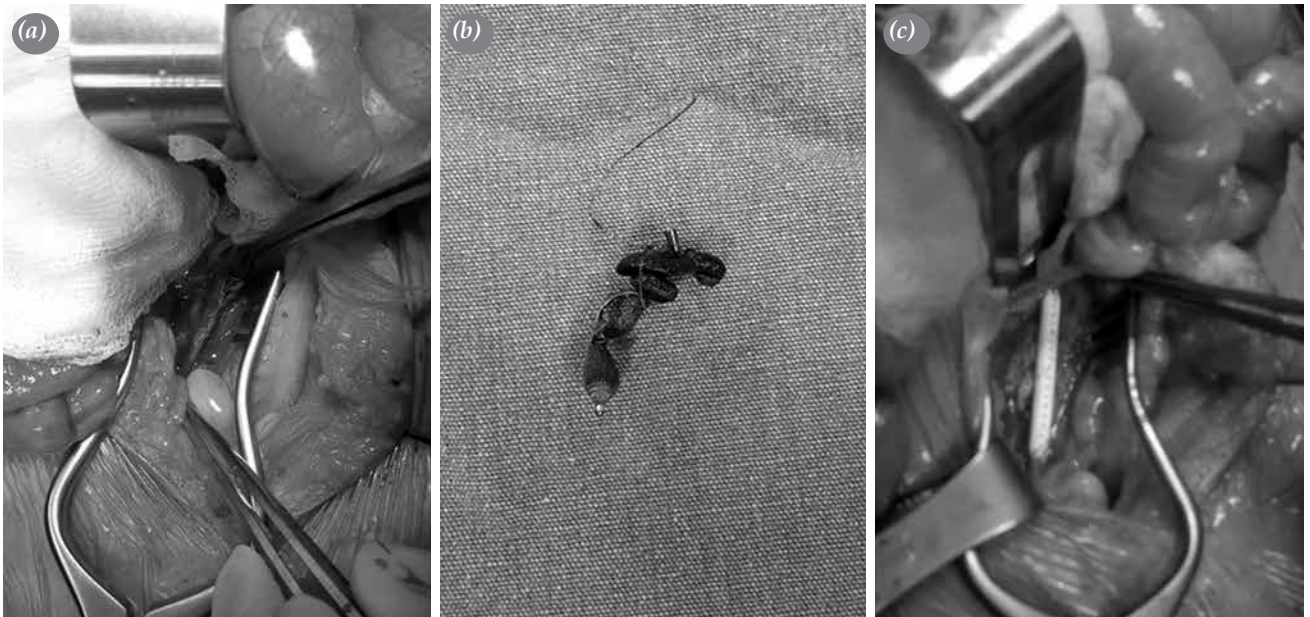


Figure 2. (a, b) The right common iliac artery was vertically opened, and the Amplatzer duct occluder II along with the snare guidewire was extracted. (c) A 4-mm polytetrafluoroethylene tube graft interposition was performed with ligation of the right internal iliac artery.

postoperative Day 9. She had no signs of ischemia and the graft was patent with triphasic flow pattern at five months of follow-up in the outpatient setting.

DISCUSSION

In addition to the advancements in device technology, the avoidance of thoracotomy, shortened procedural time and length of hospital stay have made transcatheter PDA closure the preferred treatment modality.^[1-3] The ADO-II is a mushroom-shaped, self-expandable device manufactured at a thickness of 0.004-inch nitinol wire mesh and a patch made of polyester fiber within. Although many of the deficiencies of coil embolization techniques have been overcome with the use of ADO-II,^[2] considerably non-negligible rates of complication persist.^[2-5] Among 404 patients, Amoozgar et al.^[3] reported device embolization as the most frequent (2.7%) complication of transcatheter PDA closure. In the current case, ADO-II was embolized to the RCIA; however, what makes this case interesting was the mechanism of the vascular injury. In general, the mechanism of vascular injury in pediatric patients undergoing transcatheter intervention is iatrogenic and access site-related.^[3-5] On the contrary, the mechanism of vascular injury in our case was different. In our case, during the surgical removal of the device through arteriotomy, the device was found to be wrapped up with the snare guidewire (Figure 2b). Thus, retrieval of the device was thought to be strived strongly, leading to RCIA dissection. From our point of view, this situation highlights another critical issue indicating the importance of the operator experience for not only the transcatheter PDA closure technique, but also for proper management of possible complications, and additionally, the importance of surgical back-up during these procedures.

Rolland et al.^[6] reported 73% spontaneous PDA closure even in extremely preterm infants. Additionally, from our point of view, due to the increased rate of vascular injury in patients less than one year old,^[1,5] patients who are asymptomatic or in whom the symptoms are under control with medications, it seems beneficial to delay transcatheter PDA closure, until the patient turns at least one-year-old. Our patient was asymptomatic with medications; thus, PDA was not closed surgically in the current admission. Furthermore, at five months of follow-up in the outpatient setting, the patient was still asymptomatic with a normal growth as for PDA, highlighting the importance of patient selection for transcatheter PDA closure and avoidance of overtreatment with the associated complications.

Along with the studies which compare patency of different grafts, the long-term follow-up of extremity viability and outcomes of vascular reconstruction techniques following pediatric vascular injury are limited, which makes the fate of the bypass grafts uncertain in this patient population.^[4,5] Although the graft may be patent for a particular period, outgrowth of the polytetrafluoroethylene graft is the anticipated problem in the near future, which in our opinion, within two or three years. Furthermore, gait disturbances, leg-length discrepancy, claudication, and additional surgical or endovascular interventions would be other morbidities which will be confronted in the long-term period.^[5]

In conclusion, transcatheter closure of patent ductus arteriosus seems to be effective and safe in not all but selected cases. This case report highlights the importance of patient selection, importance of the avoidance from insisting on retrieval of the occluder device, and backup of pediatric cardiovascular surgical cover, since although the embolization rate seems to be very low, the outcomes may be devastating including limb loss, death or in the best-case scenario, need for multiple surgical and/or endovascular procedures in the future.

Declaration of conflicting interests

The authors declared no conflicts of interest with respect to the authorship and/or publication of this article.

Funding

The authors received no financial support for the research and/or authorship of this article.

REFERENCES

1. Baruteau AE, Hascoët S, Baruteau J, Boudjemline Y, Lambert V, Angel CY, et al. Transcatheter closure of patent ductus arteriosus: past, present and future. *Arch Cardiovasc Dis* 2014;107:122-32.
2. Backes CH, Rivera BK, Bridge JA, Armstrong AK, Boe BA, Berman DP, et al. Percutaneous Patent Ductus Arteriosus (PDA) Closure During Infancy: A Meta-analysis. *Pediatrics*. 2017;139(2). pii: e20162927.
3. Amoozgar H, Salehi S, Farhadi P, Edraki MR, Borzoe M, Ajami G, et al. Follow-Up Results of Device Occlusion of Patent Ductus Arteriosus. *Iran J Pediatr* 2016;26:3621.
4. Tasar M, Yaman ND, Saricaoglu C, Eyiletlen Z, Kaya B, Uysalel A. Surgical repair of lower extremity vascular injuries in children: two cases. *Case Rep Vasc Med* 2014;2014:606574.
5. Lin PH, Dodson TF, Bush RL, Weiss VJ, Conklin BS, Chen C, et al. Surgical intervention for complications caused by femoral artery catheterization in pediatric patients. *J Vasc Surg* 2001;34:1071-8.
6. Rolland A, Shankar-Aguilera S, Diomandé D, Zupan-Simunek V, Boileau P. Natural evolution of patent ductus arteriosus in the extremely preterm infant. *Arch Dis Child Fetal Neonatal Ed* 2015;100:F55-8.