

A small horn-like pseudoaneurysm of the common carotid artery due to penetrating injury

Delici yaralanmaya bağlı ana karotis arterde boynuz görünümlü küçük pseudoanevrizma

Eyüpserhat Çalık,¹ Ahmet Yalçın,² Ziya Yıldız,¹ Mehmet Tort,¹ Ümit Arslan,¹ Hüsnü Kamil Limandal,¹
Mehmet Ali Kaygın,¹ Özgür Dağ,¹ Bilgehan Erku¹

Departments of ¹Cardiovascular Surgery, ²Radiology,
Erzurum Region Training and Research Hospital, Erzurum, Turkey

A 31-year-old male patient was admitted to the emergency service with an injury of the left neck zone 2 (sternal notch to the angle of mandible) through a letter opener. In the injured area, there was no bleeding and any evidence of a major hematoma, defined as a 5 mm skin lesion. On ultrasonography (USG), we detected an intimal injury of the common carotid artery (CCA) and there was a small hematoma around it. For the evaluation of other builds of the neck, computed tomography angiography (CTA) was performed and showed a small two-sided horn-like pseudoaneurysm. Pharynx, larynx, esophagus, trachea, neck vein, and cervical nerves were intact (Figure 1). As the patient was hemodynamically stable, we performed an open surgery on the day after admission. Approximately 1 cm defect was excised and left CCA was repaired with the end-to-end anastomosis (Figure 2). No surgery-related complication was seen in the postoperative period. The patient was discharged with full recovery on the third postoperative day. At six months and one year, the patient was uneventful.

The penetrating neck injuries include a wide clinical spectrum from conditions which threaten life and require immediate surgery, to conditions which require a detailed examination, as some patients are hemodynamically stable.^[1,2] Carotid artery injuries account for nearly 22% of all cervical vascular injuries.^[1] Approximately 75% and 20% of these cases are CCA and internal carotid artery injuries.^[1] In perforating injuries of the neck, the

treatment approach still remains questionable. In case of vascular injuries which present with several manifestations such as active bleeding, a rapidly growing hematoma, arteriovenous fistula, loss of pulse with neurological deficits, immediate surgical treatment is essential. In the presence of suspicious signs of vascular injury, which include close injury to the carotid cover, an ingrown hematoma, unknown level of fistula, loss of carotid pulse without neurological deficit, further diagnostic studies should be performed.^[2] Recently, CTA which offers a thorough evaluation of the structural injuries of the neck has been a widely used diagnostic modality.^[2]

For injuries of zone 2 of the neck, the diagnostic and therapeutic modalities have changed over time. Earlier, clinical observation and ligation technique were used.^[3] With the development of arterial repair methods during the Korean War, the idea of surgical exploration to asymptomatic patients was adopted and has been survived its validity for a long-time. During the years of the spread of conventional angiography, angiography was recommended for possible injuries of the carotid artery. Although ultrasonography - Doppler ultrasound in recent years - has been widely recommended for asymptomatic patients, CTA is considered as the major diagnostic tool.^[2] In the treatment, conventional vascular repair methods are often used, while repair techniques with endovascular interventions (stent grafting, coil embolization, etc.) have become widespread.^[1,4] The stent grafting is a frequently used method which has been increasingly



Available online at
www.tgkdc.dergisi.org
doi: 10.5606/tgkdc.dergisi.2016.11973
QR (Quick Response) Code

Received: May 13, 2015 Accepted: August 10, 2015

Correspondence: Eyüpserhat Çalık, MD. Erzurum Bölge Eğitim ve Araştırma Hastanesi Kalp ve Damar Cerrahisi Kliniği, 25040 Yakutiye, Erzurum, Turkey.

Tel: +90 442 - 232 57 80 e-mail: eyupserhatcalik@hotmail.com

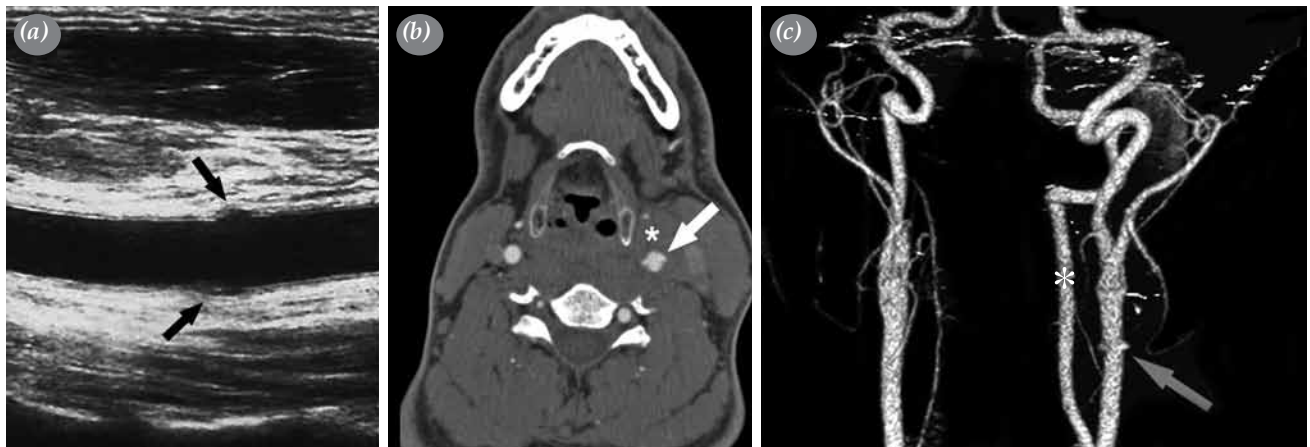


Figure 1. (a) Coronal B-mode ultrasound image obtained from the level of distal common carotid artery. Focal medial and lateral intimal defects of the common carotid artery seen at the injury site (black arrows). (b) Axial contrast enhanced computed tomography image and (c) three-dimensional volume rendered image of the same level. Complete penetration of common carotid artery characterized by contrast enhancement (white arrow, grey arrow). Note the obliterated perivascular fat planes due to hemorrhage (white asterisk in B). The patient had hypoplastic right vertebral artery and left dominant vertebral artery flow (white asterisk in C).

reported in the treatment of blunt and penetrating carotid artery injuries.^[1,4] Despite high technical success rates and extremely low neurological complications, the ambiguity on the long-term outcomes and the perceived risk of thromboembolic complications in young patients has precluded overall adoption of these techniques.^[1]

Nonetheless, endovascular interventions have been applied for traumatic vascular injuries with an

increasing frequency in Turkey;^[5] however, we have limited experience on these interventions in our hospital. Therefore, we primarily recommended open surgery, followed by alternative endovascular interventions in this young patient. In accordance with the consent of the patient, we performed open surgery next day due to the possible risks for bleeding, thrombosis, and infection. During surgery, we performed resection and end-to-end anastomosis, due to the presence of intimal damage and two-sided dissection of the vessel wall.

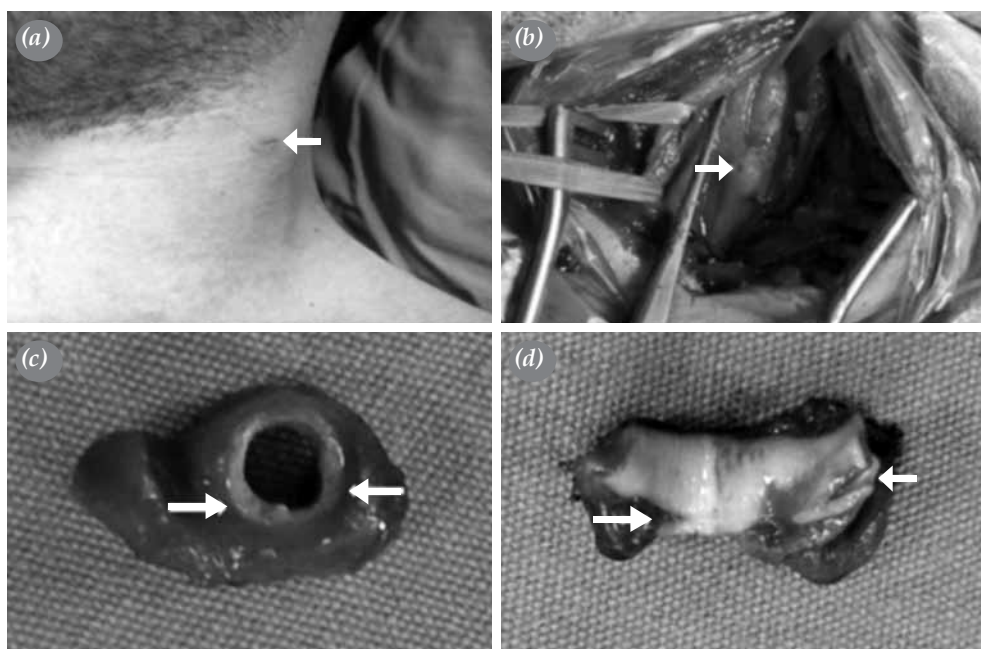


Figure 2. The images of the patient. (a) Skin lesion of the neck (white arrow). (b) Appearance of the lesion on the common carotid artery (white arrow) during surgery. (c) Excised defective vessel (white arrows show two-sided injury). (d) Intimal lesions in two-sided common carotid artery (white arrows).

In conclusion, carotid artery pseudoaneurysms are quite rare and usually occur after blunt and penetrating neck injuries. Due to possible risks for bleeding, thrombosis, and infection, it should be treated early. In the presence of suspicious signs of vascular injury, a definite diagnosis in the early stage of the disease with appropriate therapeutic efforts would reduce the morbidity and mortality rates.

Declaration of conflicting interests

The authors declared no conflicts of interest with respect to the authorship and/or publication of this article.

Funding

The authors received no financial support for the research and/or authorship of this article.

REFERENCES

1. du Toit DF, Coolen D, Lambrechts A, de V Odendaal J, Warren BL. The endovascular management of penetrating carotid artery injuries: long-term follow-up. *Eur J Vasc Endovasc Surg* 2009;38:267-72.
2. Reva VA, Pronchenko AA, Samokhvalov IM. Operative management of penetrating carotid artery injuries. *Eur J Vasc Endovasc Surg* 2011;42:16-20.
3. Fox CJ, Gillespie DL, Weber MA, Cox MW, Hawksworth JS, Cryer CM, et al. Delayed evaluation of combat related penetrating neck trauma. *J Vasc Surg* 2006;44:86-93.
4. Maras D, Lioupis C, Magoufis G, Tsamopoulos N, Moulakakis K, Andrikopoulos V. Covered stent-graft treatment of traumatic internal carotid artery pseudoaneurysms: a review. *Cardiovasc Intervent Radiol* 2006;29:958-68.
5. Temizkan V, Uğur M, Şenay Ş, Uçak A, Yılmaz AT. The effect of early endovascular intervention on the outcome of traumatic vascular injuries. *Türk Gogus Kalp Dama* 2013;21:63-8.