

## Posttraumatic iliac arteriovenous fistula

### *Travma sonucu gelişen iliyak arteriyovenöz fistül*

Anil Z. Apaydın,<sup>1</sup> Mustafa Parıldar,<sup>2</sup> Hakan Posacıoğlu,<sup>1</sup> Mustafa Korkut,<sup>3</sup> Erman Pektok<sup>1</sup>

Departments of <sup>1</sup>Cardiovascular Surgery, <sup>2</sup>Radiology and <sup>3</sup>General Surgery,  
Medicine Faculty of Ege University, İzmir

A 41-year-old male with a large arteriovenous fistula (AVF) of the left iliac vessels was referred to our clinic. Patient had a gunshot wound to the abdomen 10 years ago and underwent colostomy and repairment of the left iliac vein. The patient had been on oral anticoagulant therapy since he underwent aortic valve replacement 5 years ago. Covered endovascular stent grafts could not be used due to big size discrepancy between the common and external iliac arteries. Simple embolization with a detachable balloon system and placement of a stent to stabilize the balloon resulted with failure. AVF was closed surgically. Although endovascular approaches offer great advantages for the treatment of complex vascular pathologies, surgery remains the ultimate solution as in this case.

**Key words:** Arteriovenous shunt, surgical; iliac artery/surgery; iliac vein/surgery.

Iatrogenic iliac arteriovenous fistula (AVF) is a well-known complication of lumbar disc surgery. There have been numerous case reports regarding its surgical and endovascular treatment.<sup>[1,2]</sup> However, posttraumatic iliac AVF involving the internal iliac artery and the external and/or internal vein are extremely rare.<sup>[3]</sup> Their treatment is more complicated since they are more chronic and most patients have already undergone one or more laparotomies to repair other organ damages caused by missile injury. We report the management of a patient with chronic posttraumatic iliac AVF.

### CASE REPORT

A 41-year-old male complaining of left leg swelling and fatigue was referred to our clinic with the diagnosis of large AVF of the left iliac vessels. Patient had a gunshot wound to the lower abdomen 10 years ago. Patient underwent colostomy, repair of left iliac vein injury and left nephrectomy. Later, the colostomy was closed on an elective basis. The patient also underwent aortic valve

Sol iliyak damarlarında geniş arteriyovenöz fistül saptanan 41 yaşında erkek hasta kliniğimize yatırıldı. On yıl önce kurşunlanma nedeniyle kolostomi ve sol iliyak ven tamiri yapılan hasta beş yıl önce geçirdiği aort kapak replasmanı nedeniyle antikoagulan tedavi alıyordu. Öncelikle planlanan kaplı stent, ana ve eksternal iliyak damar çapları arasındaki büyük fark nedeniyle kullanılmadı. Ayrılabilir balon ile embolizasyon ve bu balonu yerinde tutmak için yerleştirilen stent sonuç vermedi. Arteriyovenöz fistül cerrahi olarak kapatıldı. Ameliyat sonrası dönemde hastanın sol bacağındaki bulgular hızla düzeldi. Her ne kadar endovasküler yaklaşımlar kompleks vasküler patolojilerin tedavileri için büyük avantajlar sunmaktaysa da, cerrahi tedavi halen en kesin çözüm olmaya devam etmektedir.

**Anahtar sözcükler:** Cerrahi arteriyovenöz fistül; iliyak arter/cerrahi; iliyak ven/cerrahi.

replacement with a mechanical prosthesis 5 years ago and has been on oral anticoagulation since then.

On physical examination, a loud bruit was audible in the left lower quadrant. The patient had signs of chronic venous insufficiency of the left lower extremity. Digital subtraction angiography revealed a large side wall arteriovenous fistula between the proximal portion of the left internal iliac artery and the vein (Fig. 1). A bullet was located near the AVF on posteroanterior projection. The left common and internal iliac arteries became enlarged and were measured 20 and 12 mm in diameter, respectively. The left external iliac artery diameter was only 7 mm. A large venous aneurysm filling the entire pelvis was seen on a CAT scan study (Fig. 2).

**Management.** Oral anticoagulant was discontinued and low molecular weight heparin q12h was started. Since the patient underwent multiple laparotomies and had to be on anticoagulant therapy, it was deemed better if the

Received: March 7, 2005 Accepted: May 4, 2005

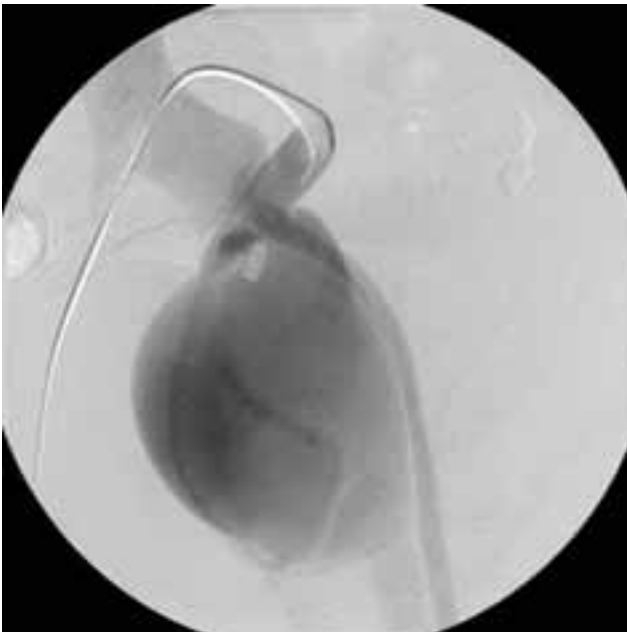Correspondence: Dr. Anil Apaydın, Ege Üniversitesi Tıp Fakültesi, Kalp ve Damar Cerrahisi Anabilim Dalı, 35100 Bornova, İzmir.  
Tel: 0232 - 390 40 52 e-mail: anil.apaydin@ege.edu.tr

fistula could be closed by means of endovascular techniques.

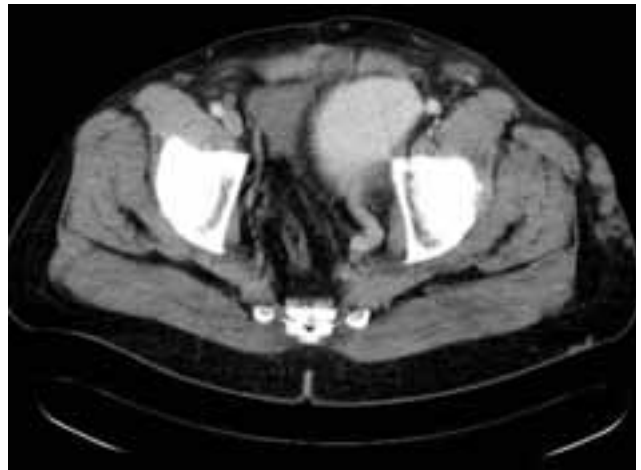**Endovascular approach.** A detachable silicon balloon (Goldvalve Balloon, Paris, France ) with a diameter of 14 mm and a length of 22.5 mm was used to occlude the arteriovenous communication and the left internal iliac artery simultaneously. The balloon was inserted through the contralateral common femoral artery and was inflated with isotonic contrast medium at the ostium of internal iliac artery. Several attempts were made to position the balloon to occlude the communication. The maximum recommended volume of contrast injection was reached and the balloon occluded the left internal iliac artery and the AVF, however the sump effect of low-pressure venous side caused the transition of the balloon into the venous aneurysm through its shortest diameter. Despite the use of maximum balloon size available, simple embolization with a detachable balloon system resulted in failure. The balloon was deflated and retrieved in order not to give rise to pulmonary embolism. We thought that implantation of a self expandable nitinol stent (Biotronik, Berlin, Germany) could stabilize the balloon in the internal iliac artery. For this purpose, a 1 cm wide and 4 cm long stent was implanted in the proximal segment of the internal iliac artery. Afterwards, a detachable silicon balloon was implanted in the stent lumen and was inflated until the maximum size was reached. The balloon stayed in the lumen of the internal iliac artery with the support of the

stent and occluded the AVF (Fig. 3). The common and external iliac arteries were patent whereas the internal iliac artery and AVF were completely occluded. No retrograde filling of the AVF was seen on control angiography and the balloon was left in place without any complication. However, 24 hours later, the abdominal bruit returned as an indicator of recanalization. Repeat angiography revealed rupture of the balloon and recanalization of the AVF. Another balloon was placed and the AVF was occluded in the same manner. This also resulted in failure within two days. Patient was prepared for surgery.

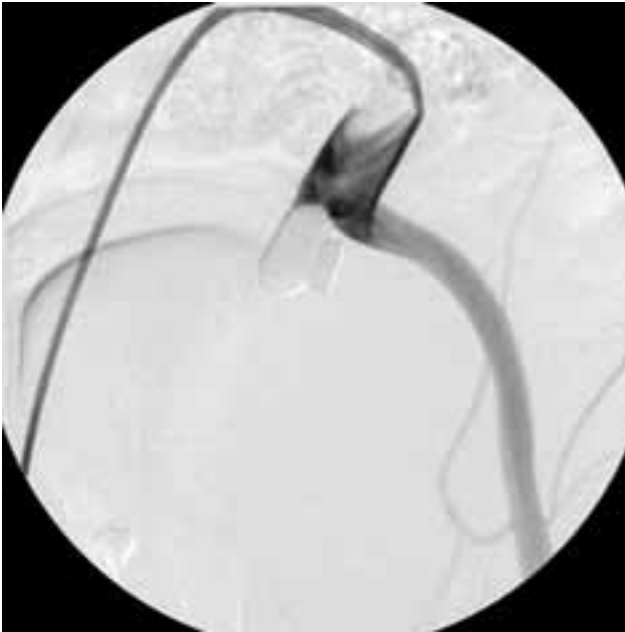**Surgical technique.** After a midline laparotomy and release of dense adhesions, bowels were mobilized. Large venous aneurysm filling the small pelvis was seen. Inferior vena cava and iliac veins were pulsatile. Distal abdominal aorta, left common and external iliac arteries were freed and looped with a vascular tape (Fig. 4). Fistula orifice was located at the proximal portion of the left internal iliac artery, 1 cm distal from the bifurcation. This portion of the artery could be dissected free with the scalpel due to dense adhesions. Intermittant clamping of the left common iliac artery to reduce the pressure and volume in the venous aneurysm revealed better exposure. Distal portion of the internal iliac artery could not be reached since it was embedded to the wall of the venous aneurysm. After heparinization, left common and external iliac arteries were clamped. Short proximal neck of the internal iliac artery could be clamped over the previously placed stent. This artery was amputated by leaving a small rim of wall and the defect at the bifurcation was primarily closed by linear suturing. Stent was quickly removed during a brief period of declamping. It was noted that the thrill over the fistula was still present. The portion of the internal iliac artery distal to the fistula was carved out by scalpel.



**Fig. 1.** Digital subtraction angiography showing a large side wall arteriovenous fistula between the proximal portion of the left internal iliac artery and the iliac veins.



**Fig. 2.** A large venous aneurysm on a Computed axial tomography scan study.



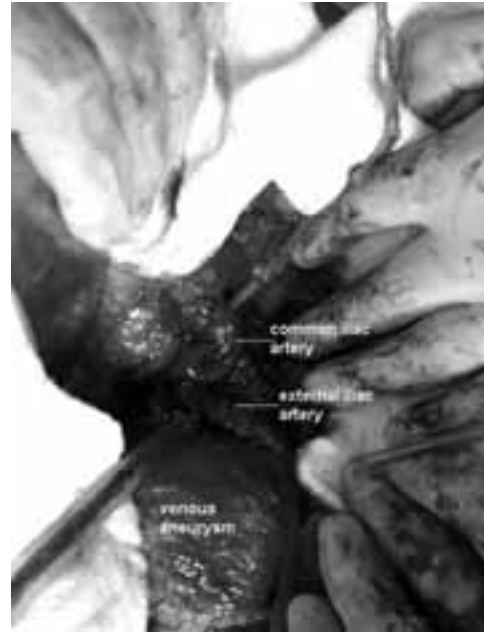
**Fig. 3.** Angiogram showing the occlusion of the arteriovenous fistula by the balloon staying in the lumen of the internal iliac artery with the support of a stent.

Thrill disappeared after ligation of this segment of the artery. Piece of the internal iliac artery that includes the fistula orifice was oversewn from outside. The venous aneurysm that mainly originated from the left internal iliac vein was left in place for the venous drainage of the left leg since it also constituted a long segment wall of the external iliac vein.

Postoperative course of the patient was uneventful, and his left leg swelling and venous engorgement disappeared dramatically.

**Comment.** The aim of the endovascular treatment must be the occlusion of the fistula with preservation of distal flow. At present, covered endovascular stent grafts are best suited for this purpose. However, in our case there was a big discrepancy between the diameters of the common iliac, and external iliac artery diameters. In addition, the AVF was located close to the internal iliac artery ostium. Endograft implantation was not suitable in this case due to above-mentioned factors. Theoretically, a tapered-graft of appropriate size could have been used. Placement of a detachable balloon was unsafe, also due to the location of the AVF. Use of a self expandable nitinol stent to stabilize the detachable balloon was not successful. The failure could be attributed to the sharp stent struts causing rupture of the silicon balloon.

Although it was used for nephrectomy in this patient, one could consider using a retroperitoneal approach to avoid intraperitoneal adhesions. We preferred midline incision since the distal aorta, and espe-



**Fig. 4.** Operative view of the left iliac bifurcation and the venous aneurysm. The left common and external iliac arteries were freed and looped.

cially the pulsatile inferior vena cava and proximal iliac veins could be safely controlled in case of an inadvertent entry to these vessels.

Venous aneurysms are rare and their long term behavior is unknown due to lack of large series. Their known risks of embolism and thrombosis can be reduced by lifelong intake of oral anticoagulants.<sup>[4]</sup> Intervention was advocated in symptomatic or enlarging ones.<sup>[5]</sup> There are only a couple of case reports with good surgical outcome in primary venous aneurysms. In these reports either a PTFE or an autologous vein was used for venous reconstruction.<sup>[4,6]</sup> In our case, the venous aneurysm was not resected due to a couple of reasons. Aneurysm did not have a neck and rather constituted a long segment wall of the external iliac vein. As mentioned above, long term patency of grafts on the venous system is not clear. One would expect stability or regression of the secondary venous aneurysm after cessation of the arterial pressure and flow pattern. We believe it is safe to follow the venous aneurysm in this case by means of yearly CAT scan or sonographic imaging since the patient had to take lifelong oral anti-coagulant for the mechanical heart valve prosthesis anyway. The size of the venous aneurysm in our patient was found to be slightly diminished in a follow-up sonogram which was done 2 months after the surgery.

Although endovascular approaches offer great advantages for the treatment of complex vascular pathologies at difficult locations such as posttraumatic

iliac AVF, surgery remains the ultimate solution as in this case.

## REFERENCES

1. Kwon TW, Sung KB, Cho YP, Kim DK, Ko GY, Yoon HK, et al. Large vessel injury following operation for a herniated lumbar disc. *Ann Vasc Surg* 2003;17:438-44.
2. Hart JP, Wallis F, Kenny B, O'Sullivan B, Burke PE, Grace PA. Endovascular exclusion of iliac artery to iliac vein fistula after lumbar disk surgery. *J Vasc Surg* 2003;37:1091-3.
3. Weyrich G, Beck A. Traumatic fistula between internal iliac artery and external iliac vein. *Radiat Med* 1990;8:215-8.
4. Fourneau I, Reynders-Frederix V, Lacroix H, Nevelsteen A, Suy R. Aneurysm of the iliofemoral vein. *Ann Vasc Surg* 1998;12:605-8.
5. Calligaro KD, Ahmad S, Dandora R, Dougherty MJ, Savarese RP, Doerr KJ, et al. Venous aneurysms: surgical indications and review of the literature. *Surgery* 1995;117:1-6.
6. Hurwitz RL, Gelabert H. Thrombosed iliac venous aneurysm: a rare cause of left lower extremity venous obstruction. *J Vasc Surg* 1989;9:822-4.