

Left ventricle wall hydatid cyst

Sol ventrikül duvarında kist hidatik

Alper Sami Kunt, Salih Aydın, Deniz Demir, Cüneyt Şelli, Mehmet Halit Andaç

Department of Cardiovascular Surgery, Medicine Faculty of Harran University, Şanlıurfa

Echinococcosis is a significant health problem in some parts of the world. Although cardiac involvement is rare, early diagnosis and treatment of this situation is important. A 48-year-old woman presented with dyspnea and palpitation on exertion. T wave was negative on leads V2-4 on the electrocardiogram and these changes were initially diagnosed as coronary artery disease and she was hospitalized. Echocardiography and computed tomography evaluation revealed a cystic formation of 4 cm in diameter located on the lateral left ventricular wall. Serologic test for hydatid cyst was positive. During surgery, the cyst was removed from the surrounding tissue. There was no connection between the cystic lumen and the ventricular cavity. The patient had an uncomplicated postoperative course. Pathologic examination confirmed the diagnosis of hydatid cyst. The patient had a hepatic cyst operation after three months and was asymptomatic at postoperative 8th month.

Key words: Cardiomyopathies/diagnosis; echinococcosis/surgery.

Hydatid cyst is a kind of parasitic infection caused by *Echinococcus granulosus*. The most frequent locations of the hydatid cysts are the liver (more than 65%) and the lungs (25%), cardiac involvement occurs in only 0.2-3% of the cases.^[1,2]

Hydatid cysts continue to be a significant health problem in developing countries including South America, Australia, New Zealand, Philippines, China, Arabia, Eastern Europe, and the Mediterranean coast. Humans are infected by way of contaminated dogs or contaminated uncooked vegetables.^[3]

In this article, we report our clinical and surgical experience with diagnosis and management of cardiac cyst hydatid intramurally located on the lateral left ventricular cardiac wall and liver hydatidosis.

Ekinokokkozis dünyadaki bazı yerleşim birimlerinde ciddi bir sağlık sorunu oluşturmaktadır. Kardiyak tutulum oldukça nadir olmasına karşın, bu durumda erken tanı ve tedavi çok önemlidir. Kırk sekiz yaşındaki kadın hasta egzersiz sırasında dispne ve çarpıntı yakınmasıyla başvurdu. Elektrokardiyografide V2-4 derivasyonlarında T dalgasının negatif olduğunun görülmesi üzerine hasta koroner arter hastalığı ön tanısıyla yatırıldı. Yapılan ekokardiyografi ve bilgisayarlı tomografide sol ventrikül duvarında 4 cm çapında kistik yapı görüldü. Kist hidatik için yapılan serolojik test pozitif bulundu. Ameliyat sırasında kist, çevre dokudan ayrıldı, kist lümeniyle ventriküler kavite arasında bağlantı olmadığı görüldü. Hastanın ameliyat sonrası dönemi komplikasyonsuz geçti. Patolojik inceleme sonucunda kist hidatik tanısı doğrulandı. Üç ay sonra hepatic kist ameliyatı olan hasta, takibinin sekizinci ayında asemptomatikti.

Anahtar sözcükler: Kardiyomiyopati/tanı; ekinokokkozis/cerrahi.

CASE REPORT

A 48-year-old woman presented with dyspnea and palpitation on exertion. Her physical examination was unremarkable. T wave was negative on leads V2-4 on the electrocardiogram and these changes were initially diagnosed as coronary artery disease. She was hospitalized for unstable angina. Cardiac silhouette was slightly enlarged on chest roentgenogram. Routine blood tests were normal.

Echocardiography revealed a cystic formation of 4.0 cm by 3.5 cm in diameter located on the lateral left ventricular wall (Fig. 1a). There were no echocardiographic signs of obstruction.

The computed tomographic scan demonstrated a well-defined cystic lesion with regular borders on the

Received: January 11, 2005 Accepted: May 10, 2005

Correspondence: Dr. Alper Sami Kunt, Harran Üniversitesi Tıp Fakültesi, Kalp ve Damar Cerrahisi Anabilim Dalı, 63100 Şanlıurfa.
Tel: 0414 - 314 63 32 e-mail: dralper@msn.com

lateral left ventricular wall (Fig. 1b). Serologic tests were positive for hydatid cyst.

Coronary angiography and ventriculography were performed. Coronary angiogram was normal and the patient did not have a filling defect at ventriculography.

The patient underwent elective operation through a median sternotomy. The mass was seen clearly in the muscle of the lateral left ventricular wall (Fig 2a). Following the initiation of cardiopulmonary bypass (CPB) under mild systemic hypothermia, the heart was arrested with cold blood cardioplegia. The cyst, which invaded lateral left ventricular muscle, was removed from the surrounding tissue. There was no connection

between the cyst lumen and the ventricular cavity. The cyst was removed intact (Fig. 2b). The ventriculotomy was sutured by using Teflon strips (Impra, Inc, subsidiary of LR Bard, Tempe, AZ).

The patient was easily weaned from CPB and had an uncomplicated postoperative course. Pathologic and microbiologic examination of the surgical material confirmed the diagnosis of hydatid cyst. After 3 months, she had undergone hepatic cyst operation. Albendazole treatment was prescribed 10 mg/kg/day to be used for 1 year. She remained asymptomatic, without any evidence of recurrence during her 8-months postoperative follow-up period.

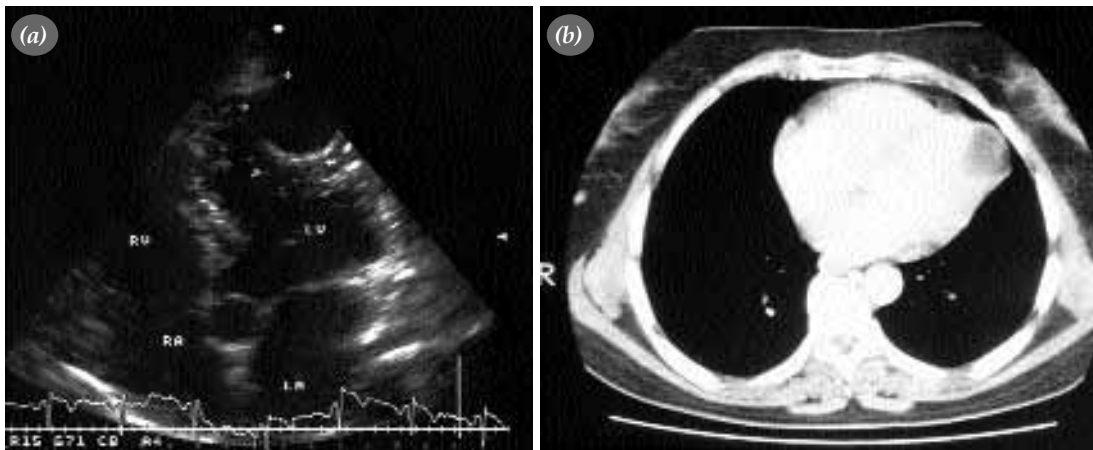


Fig. 1. (a) Echocardiography revealed a cystic formation of 4.0 cm by 3.5 cm in diameter located on the lateral left ventricular wall (LA: Left atrium; LV: Left ventricle; RA: Right atrium; RV: Right ventricle). (b) Computed tomographic scan demonstrated a well-defined cystic lesion with regular borders on the lateral left ventricular wall.

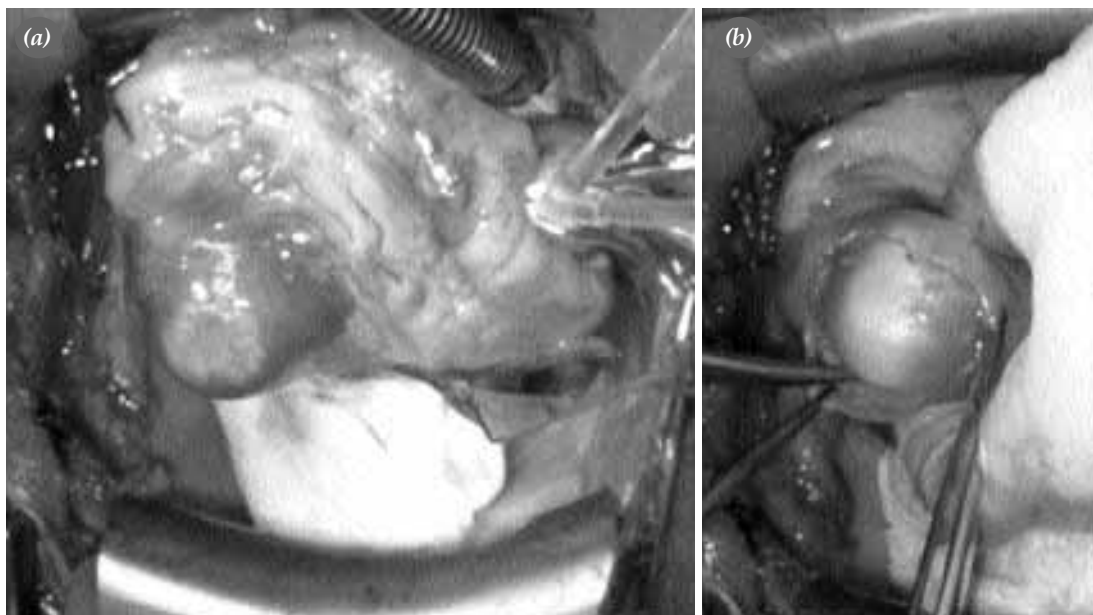


Fig. 2. (a) The mass was seen clearly in the muscle of the lateral left ventricular wall. (b) The cyst was removed intact.

DISCUSSION

Echinococcosis is a human parasitic disease most commonly caused by *Echinococcus granulosus*. Hydatid cysts can be located in various tissues, although they are mostly seen in the liver (50-70%) and the lungs (20-30%) and other organs (less than 10%) in humans.^[4] Cardiac hydatid cysts comprise only 0.5-2% of all the hydatidosis cases.^[1,2]

The embryo usually reaches the myocardium via coronary circulation. The cyst develops within a period of 1-5 years. Because of the pressure in the cardiac chambers, hydatid cysts of the left ventricle are usually localized subepicardially. Pericystic growth of a viable hydatid cyst may determine the outcome, such as rupture into the heart chambers or pericardial cavity, compression of the coronary vessels with resultant myocardial ischemia, disturbances of conducting mechanism of the heart, obstruction of the ventricular outflow tract and pulmonary emboli.^[4,5] Hydatid cysts of the left ventricle are usually localized subepicardially and rarely rupture into the pericardial space.

The clinical presentation varies depending on the location, size and presence of complications. In some patients, it is mistaken as solid masses, which is frequently confused with heart tumors.^[5] Cardiac hydatid cyst may be readily diagnosed in cases with history of previous hydatid cyst disease. Cardiovascular manifestations of cardiac echinococcosis are arrhythmia, angina, valvular dysfunction, pericardial reaction, pulmonary or systemic embolism, pulmonary hypertension, anaphylactic reactions.^[5] The techniques of cardiac imaging, either computed tomography or two-dimensional echocardiography are sensitive and useful diagnostic procedures in cardiac echinococcosis.^[1] Cardiac hydatid cysts should be treated by surgical excision under CPB since the removal of cyst via this technique is safer. Our patient had hepatic and cardiac hydatidosis diagnosed by computed tomography and echocardiography. If it had ruptured, as it is well known by scientific circles, into the pericardial cavity, the patient would most probably have died. Because the left ventricular wall was so delicate due to its intramural location on the left ventricular wall. It was successfully removed under CPB and no other methods to prevent

contamination were needed because we removed it intact.

When hydatid cyst is going to be removed, it is usually sterilized before enucleation by injection or instillation of 2% formalin, 0.5% silver nitrate solution, 20% hypertonic saline solution, 1% iodine solution or 5% cetimide solution.^[6] We sterilized the cyst before enucleation by injecting 20% hypertonic saline solution into it. It has been suggested that antihelmintics (mebendazole or albendazole) should be given during the postoperative period because of the risks of recurrence of hydatid cyst.^[7]

In conclusion, whatever the localization, treatment for the cardiac hydatid cyst disease is surgical and surgery should not be delayed. Patients with cardiac echinococcosis may remain asymptomatic for many years or have minor nonspecific complaints, but it is associated with an increased risk of lethal complications if left undiagnosed and untreated. Gentle manipulation of the heart under cardiopulmonary bypass minimizes the operative risk.

REFERENCES

1. Aydogdu T, Sahin N, Ulsan V, Gurpinar F, Turkey C, Bayezid O. Right atrial hydatid cyst associated with multiple organ involvement: case report. *J Thorac Cardiovasc Surg* 2001;121:1009-11.
2. Miralles A, Bracamonte L, Pavie A, Bors V, Rabago G, Gandjbakhch I, et al. Cardiac echinococcosis. Surgical treatment and results. *J Thorac Cardiovasc Surg* 1994;107:184-90.
3. Kardaras F, Kardara D, Tselikos D, Tsoukas A, Exadactylos N, Anagnostopoulou M, et al. Fifteen year surveillance of echinococcal heart disease from a referral hospital in Greece. *Eur Heart J* 1996;17:1265-70.
4. Kardelen F, Akcurin G, Ertug H, Beyazit O. Right atrial hydatid cyst with multiple organ involvement. *Asian Cardiovasc Thorac Ann* 2001;9:240-2.
5. Tejada JG, Saavedra J, Molina L, Forteza A, Gomez C. Hydatid disease of the interventricular septum causing pericardial effusion. *Ann Thorac Surg* 2001;71:2034-5.
6. Tetik O, Yilik L, Emrecan B, Ozbek C, Gurbuz A. Giant hydatid cyst in the interventricular septum of a pregnant woman. *Tex Heart Inst J* 2002;29:333-5.
7. Durgut K, Özergin U, Özdemir K, Görmüş N, Yüksek T, Solak H. Hydatid cyst on right ventricular posterior wall. *Asian Cardiovasc Thorac Ann* 2000;8:275-7.