

## **Recurrent familial cardiac myxomas in a mother and daughter with Carney's syndrome**

*Carney sendromlu anne ve kızında tekrarlayan ailesel kardiyak miksonoma*

**Nazmiye Selçuk Kapisiz, Hasan Fahri Kapisiz, Orhan Veli Doğan, Ertan Yücel**

Department of Cardiovascular Surgery, Ankara Dışkapı Yıldırım Beyazıt Training and Research Hospital, Ankara

We presented familial recurrent cardiac myxomas and goiter in a mother and her daughter with Carney's syndrome. A 42-year-old woman and her 13-year-old daughter developed recurrent myxomas 1.5 years and four years after surgery for left atrial myxoma, respectively. Both were operated on for recurrent left atrial myxomas. One interesting point was that the recurrent myxoma in the mother originated from the endothelium over the patch placed in the first operation. Since Carney's syndrome is much more than a cardiocutaneous disorder, medical evaluation and follow-up of patients and their first-degree relatives are needed.

**Key words:** Heart atria; heart neoplasms; myxoma/genetics/surgery; recurrence; skin pigmentation; syndrome.

Myxomas are typically sporadic, benign, nonrecurring intracardiac tumors.<sup>[1]</sup> However, a familial form and syndrome form of this lesion have been described, which are associated with a higher rate of recurrence. The difference between the two forms is that the syndrome form is a multisystem disease and comprises the familial form. In other words, every syndrome form of myxoma is also a familial form.<sup>[2]</sup> The association of intracardiac myxomas with myxomatous masses of other organs, endocrine overactivity and spotty pigmentation of the skin was first described by Carney et al. and named as Carney's syndrome.<sup>[3]</sup>

We presented a woman with Carney's syndrome. We documented recurrent left atrial myxoma in her daughter by examining her first-degree relatives. The importance of knowing the components of Carney's syndrome, the need to examine patients with cardiac myxoma in this aspect, and investigation of the first-degree relatives of affected patients are emphasized.

Bu yazıda Carney sendromlu anne ve kızında görülen tekrarlayan ailesel kardiyak miksonoma ve guatr sunuldu. Kırk iki yaşında annede ve 13 yaşındaki kızında ilk ameliyattan sırasıyla 1.5 yıl ve dört yıl sonra sol atriyal miksonoma nüksü saptandı. Her ikisi de tekrarlayan sol atriyal miksonoma nedeniyle ameliyat edildi. İlginç olan nokta, annedeki tekrarlayan miksonomanın, ilk ameliyatta yerleştirilen yama üzerindeki endotelden kaynaklanmış olmasıydı. Carney sendromu kardiyokutanöz bir hastalıktan çok daha öte bir durum olduğundan, hastanın ve birinci dereceden akrabalarının tıbbi incelemesi ve takibi gerekir.

**Anahtar sözcükler:** Kalp atriyumu; kalp neoplazileri; miksonoma/genetik/cerrahi; nüks; deri pigmentasyonu; sendrom.

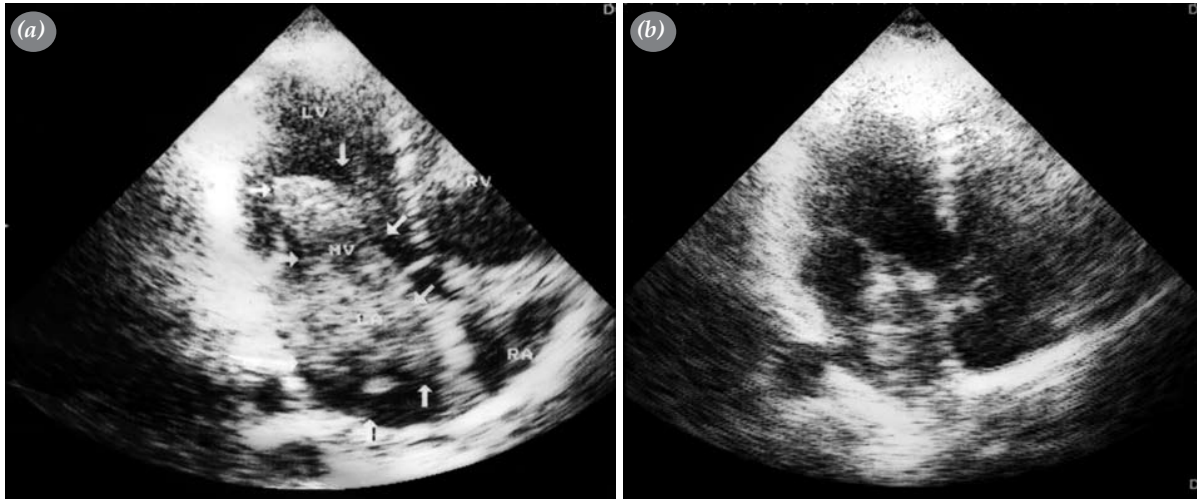
### **CASE REPORT**

A 42-year-old woman underwent surgery for a huge left atrial myxoma with a biatrial approach and wide resection in our clinic (Fig. 1a). The atrial septal defect was closed with a synthetic Dacron patch. She then presented with a complaint of palpitations 1.5 years after the initial surgery. Echocardiography revealed a recurrent left atrial myxoma (Fig. 1b). She had extensive spotty mucocutaneous brown pigmentation on her face and body, three cutaneous tumors on her legs (two on the right leg, one on the left) and goitre. She was examined for other components of Carney's syndrome. Multinodular benign goitre was detected by thyroid ultrasonography and fine needle aspiration biopsy. Thoracoabdominal spiral tomography, magnetic resonance imaging of the hypophysis, and bilateral mammography showed no tumoral pathology. Blood biochemistry and hormonal studies showed only hyperthyroidism. The biopsy of cutaneous tumors in her legs was consistent with cutaneous myxoma.

*Presented at the 52nd International Congress of European Society of Cardiovascular Surgery, November 7-10, 2003, Istanbul, Turkey (52. Uluslararası Avrupa Kardiyovasküler Cerrahi Derneği Kongresi'nde sunulmuştur. Kasım 7-10 2003, İstanbul).*

*Received:* January 31, 2006 *Accepted:* March 03, 2006

Correspondence: Dr. Nazmiye Selçuk Kapisiz. Bizim Çınar Sitesi, B2-A Blok, D: 9, Kent Koop Mah., 06370 Batıkent, Ankara.  
Tel: 0312 - 251 93 19 e-mail: hkapisiz@superonline.com



**Fig. 1.** Echocardiographic views of the mother showing (a) initial and (b) recurrent left atrial myxomas.

The patient's first-degree relatives were examined by history, physical examination, and echocardiography. The father and mother of the patient were the children of siblings. The mother who died at 32 years of age was known to have goitre and a cerebrovascular event at age 20. The mother had two sisters and four brothers. Of these, only one sister had an operation in the breast for myxoid mammary fibroadenoma. The other family members of the father and mother were found to have no findings of Carney's syndrome.

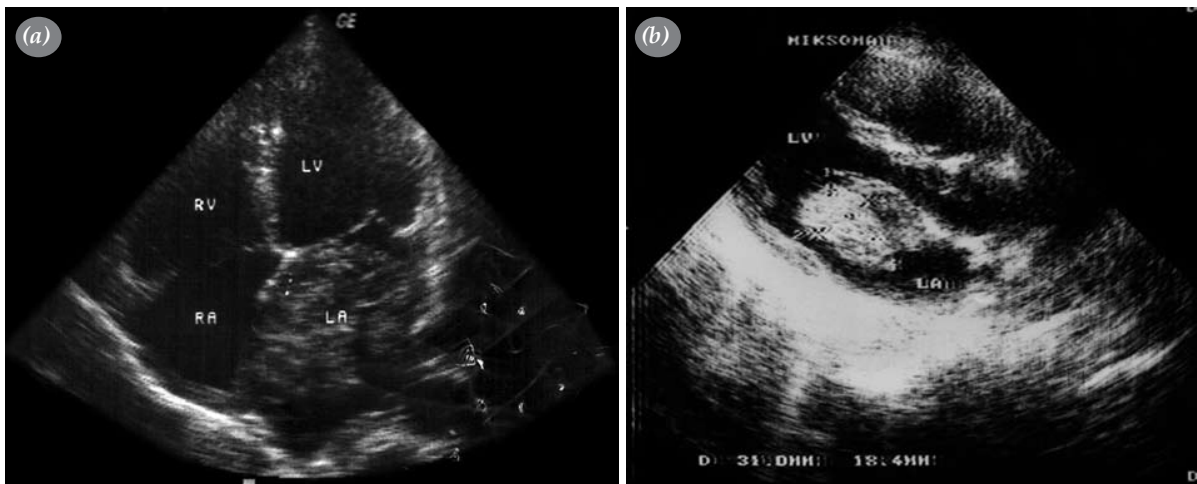
The index patient had four daughters. The eldest one was 18 years old and had mucocutaneous brown spotty pigmentation in her face and body, and euthyroid goitre. Another was 17 years old and had mucocutaneous spotty pigmentation in her face and body and hyperthyroid goitre. Echocardiography revealed mitral valve prolapsus in both sisters. The youngest daughter who was eight years old had spotty mucocutaneous pigmentation in her face.

The third daughter was 13 years old and had spotty pigmentation in her face and body and euthyroid goitre. She was operated on for a left atrial myxoma four years before in our clinic (Fig. 2a). Extensive resection with a biatrial approach was performed and the atrial septal defect was repaired with a patch. However, she was found to have a recurrent left atrial myxoma at the time her mother was examined (Fig. 2b).

The mother and her third daughter were operated on for recurrent left atrial myxomas. The lesions were both very extensive in the left atrium, multicentric, and wide-based. One interesting point was that the recurrent myxoma in the mother originated from the endothelium over the patch placed in the first operation. Biopsy of specimens revealed no malignant pathology, but classic features of myxoma.

## DISCUSSION

Approximately 5% of myxomas show a familial pattern with autosomal dominant inheritance with regard



**Fig. 2.** Echocardiographic views of the daughter showing (a) initial and (b) recurrent left atrial myxomas.

to tumor growth. While 80% of nonfamilial sporadic myxomas exhibit a normal DNA pattern, an abnormal chromosomal pattern is present in 20% of nonfamilial sporadic myxomas and in patients with the familial pattern. Unlike sporadic myxomas, familial myxomas develop in younger patients, grow as multicentric tumors, and show no sex predilection.<sup>[4]</sup> The recurrence rates after surgical resection of familial myxomas are reported to be higher (21%-67%).<sup>[5]</sup> About 20% of familial myxomas are associated with other pathologies (adrenocortical nodular dysplasia, testicular tumors, etc.) These cases are named as "complex myxoma" in the familial myxoma group.<sup>[4]</sup>

There are several case reports of complex or syndrome form, namely Carney's syndrome, which comprises skin lesions (ephelides, blue nevi, lentiginos), skin myxomas, myxoid mammary fibroadenomas, Cushing's syndrome, adrenocortical hyperplasia, pituitary tumors, testicular, thyroid and uterine lesions.<sup>[6]</sup> Awareness to these findings is very important. Appreciation of mucocutaneous features seen in the majority of patients with Carney's syndrome can help detect potentially serious cardiac and endocrine tumors. This mucocutaneous pigmentation was present in both the mother and her daughter.

Proposed explanations for myxoma recurrence include incomplete removal (either of the primary site and/or failure to recognize multiple tumors initially), malignant transformation, intracardiac seeding of tumor cells, or multiple foci of tumor development.<sup>[6]</sup> Recurrence can be seen in these patients because of multigrowth potential of the tumor even after a complete resection including the base of attachment, avoiding detachment of the tumor fragment, and exploration of all the heart cavities for possible multiple origins.<sup>[7]</sup> This was the case in both of our patients. This may be due to intracardiac seeding of tumor cells or multiple foci of tumor development besides being a component of Carney's syndrome in our cases.

In our case, by examining the first-degree relatives of our patient, we detected recurrent left atrial myxoma

in her daughter. This shows the importance of close follow-up of these patients.

In conclusion, Carney's syndrome is much more than a cardiocutaneous disorder. Adding our experience with this family to that in the literature,<sup>[3,8]</sup> we make the following recommendations for the management of affected patients. (i) Patients with the diagnosis of myxoma should be investigated for the components of Carney's syndrome. (ii) Medical evaluation of first-degree relatives is needed whenever a patient is recognized to have a myxoma, especially recurrent cases. (iii) Close postoperative follow-up is necessary to monitor recurrences of cardiac myxoma. (iv) In cases of young patients, multiple myxomas in one or two chambers, complex myxoma, localization outside the left atrium, and recurrent myxomas, the patient and his/her first-degree relatives should be examined for Carney's syndrome.

## REFERENCES

1. Fagan LF Jr, Castello R, Barner H, Moran M, Labovitz AJ. Transesophageal echocardiographic diagnosis of recurrent right ventricular myxoma 2 years after excision of right atrial myxoma. *Am Heart J* 1990;120:1456-8.
2. Deshpande A, Kumar S, Chopra P. Recurrent, biatrial, familial cardiac myxomas. *Int J Cardiol* 1994;47:71-3.
3. Tatebe S, Ohzeki H, Miyamura H, Hayashi J, Hiratsuka M, Sunami E, et al. Carney's complex in association with right atrial myxoma. *Ann Thorac Surg* 1994;58:561-2.
4. Hall RA, Anderson RP. Cardiac neoplasms. In: Edmunds LH Jr, editor. *Cardiac surgery in the adult*. New York: McGraw-Hill; 1997. p. 1345-62.
5. van Gelder HM, O'Brien DJ, Staples ED, Alexander JA. Familial cardiac myxoma. *Ann Thorac Surg* 1992;53:419-24.
6. Akbaş H, Kırallı K, Dağlar B, Kutay V, Işık O, Yakut C. Surgical treatment of left-atrial myxoma in Carney's complex. *Thorac Cardiovasc Surg* 1997;45:148-50.
7. Castells E, Ferran V, Octavio de Toledo MC, Calbet JM, Benito M, Fontanillas C, et al. Cardiac myxomas: surgical treatment, long-term results and recurrence. *J Cardiovasc Surg* 1993;34:49-53.
8. Nwokoro NA, Korytkowski MT, Rose S, Gorin MB, Penles Stadler M, Witchel SF, et al. Spectrum of malignancy and premalignancy in Carney syndrome. *Am J Med Genet* 1997; 73:369-77.