

## How to do it?

## Nasıl yapılır?

## Unroofing procedure

## Unroofing işlemi

Nihan Kayalar, Harold M. Burkhart

Division of Cardiovascular Surgery, Mayo College of Medicine, Rochester, MN, USA

Anomalous origin of the coronary artery from the opposite sinus may have a potential for life-threatening presentation including myocardial infarction, arrhythmia, or sudden death. Surgery is generally indicated when the course of anomalous artery is interarterial between the aortic root and right ventricular outflow tract/pulmonary artery. Specific morphologic details, mainly the ostial status and intramural course, influence the type of surgical repair. The unroofing procedure is a technique suitable for those with intramural course, and it creates a new coronary ostium in the correct valsalva sinus, thereby eliminating the course between the pulmonary artery and aorta as well as the intramural course.

**Key words:** Coronary anomalies; sudden death; unroofing procedure.

## The unroofing procedure

Anomalous origin of the coronary artery from the opposite sinus may have a potential for a life-threatening presentation, including myocardial infarction, arrhythmia, or sudden death. The most common anomaly of this type is the anomalous origin of the left circumflex (LCx) coronary artery from the right sinus followed by the right coronary artery from the left sinus of Valsalva (ARCA), and the left main coronary artery from the right sinus of Valsalva (ALCA).<sup>[1,2]</sup> When an anomalous coronary artery arises from the opposite sinus, it can take one of these four courses: interarterial, transseptal, retroaortic or prepulmonic. The interarterial course between the aortic root and right ventricular outflow tract/pulmonary artery (PA) is the so-called malignant course and is most likely to be associated with an adverse outcome, including death (Fig. 1).

Koroner arterlerin karşı valsalva sinüsten çıkış anomalisi miyokard infarktüsü, aritmi ve ani ölüm gibi hayatı tehdit edecek şekilde belirti verebilir. Anormal arterin izlediği yol, aort kökü ve sağ ventriküler çıkım yolu/pulmoner arter arasında ise anomali yüksek riskli kabul edilir ve genellikle cerrahi tedavi önerilir. Koroner ostiumun yapısı ve intramural segment varlığı gibi morfolojik özellikler cerrahi tekniğin seçilmesinde rol oynar. Unroofing işlemi, intramural segment olan durumlarda seçilen bir tekniktir ve doğru valsalva sinüste yeni bir koroner ostium oluşturur ve böylece intramural segmentin yanı sıra pulmoner arter ve aort arasındaki segmenti elimine eder.

**Anahtar sözcükler:** Koroner arter anomalileri; ani ölüm; unroofing işlemi.

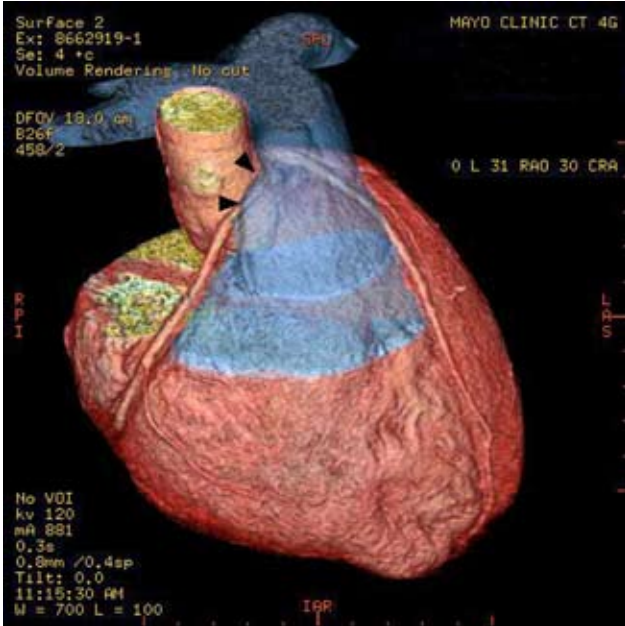
## Surgical indications and technique

The anomalous left main coronary artery with an interarterial course is considered to be a high risk lesion, and even without symptoms, its surgical correction is recommended.<sup>[2,3]</sup> Although a surgical correction is indicated in symptomatic ARCA, the correction of asymptomatic ARCA remains controversial, but it is still a widely recommended operation.<sup>[3,4]</sup> In patients with symptoms, the surgery should not be delayed. Given the fact that sudden death is rare in children before adolescence, the option to delay elective surgical repair until late puberty or approximately 10 years of age in the asymptomatic patients is also recommended.<sup>[2,5]</sup>

Many surgical strategies have been suggested to treat this defect, including coronary reimplantation, unroofing the intramural segment and coronary artery bypass grafting. Specific morphologic details, mainly the ostial

Received: June 22, 2009 Accepted: June 30 2009

Correspondence: Nihan Kayalar, M.D. Mithatpaşa Mah., Kazım Karabekir Cad., Kayalar Sok., No: 10, 34075 Kemerburgaz, Eyüp, İstanbul, Turkey. Tel: +90 212 - 360 13 31 e-mail: nihankayalar@yahoo.com



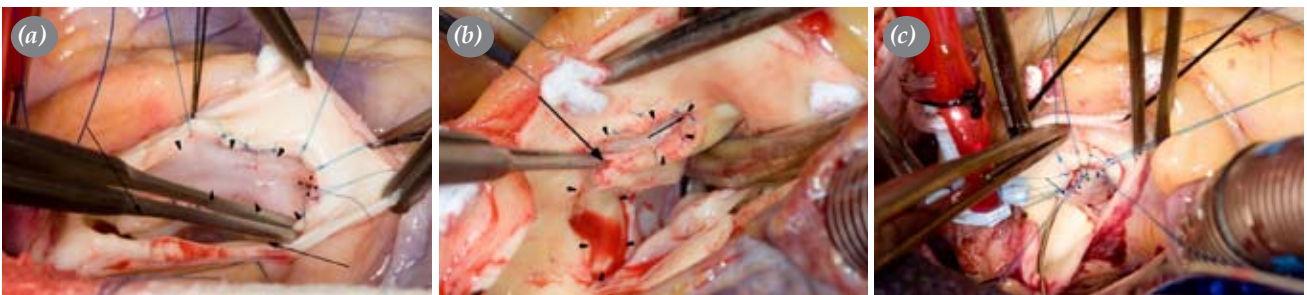
**Fig. 1.** Three-dimensional computed tomography image showing anomalous right coronary artery from the left sinus of Valsalva with a course between aorta and pulmonary artery. Arrowheads point to the interarterial and intramural segment of right coronary artery. Copyrighted and used with permission of Mayo Foundation for Medical Education and Research.

status and the intramural course, influence the type of the surgical repair. The unroofing procedure, suitable for those with intramural course, was first described by Mustafa et al.<sup>[6]</sup> This technique creates a new coronary ostium in the correct sinus, eliminates the course

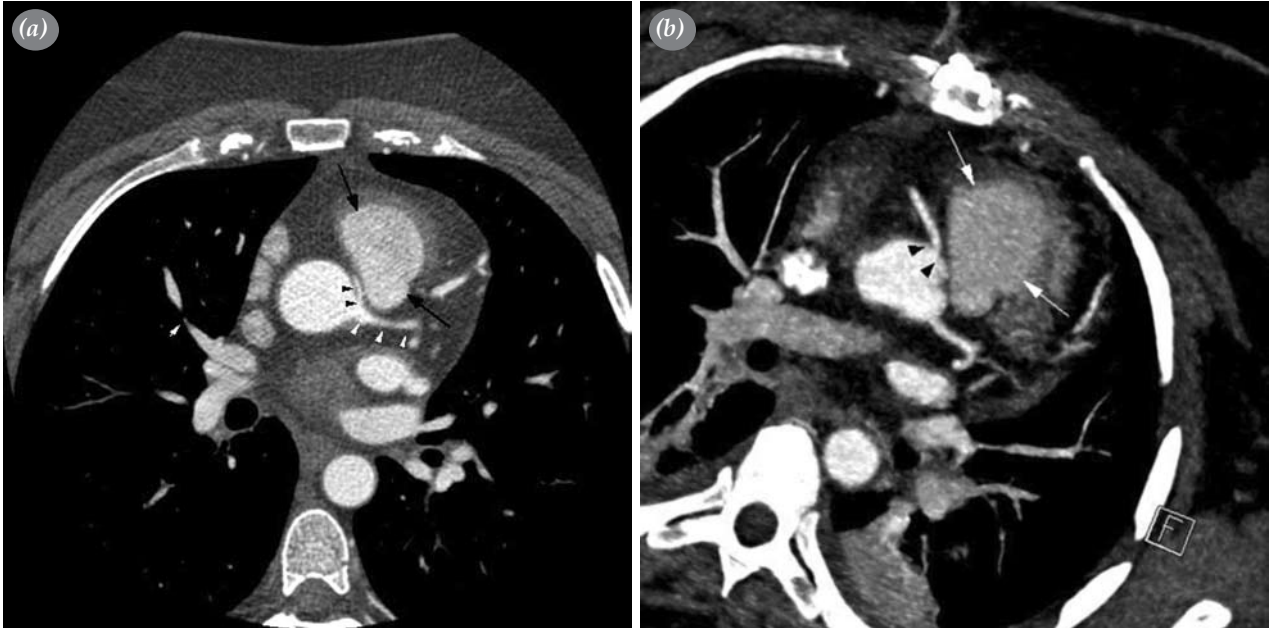
between the PA and aorta, and eliminates the intramural course.

The operation is performed through a median sternotomy with standard aortic arterial and dual stage single venous cannulation. Following the aortic cross-clamping, the cardioplegia is given through the antegrade route. The aortotomy should be performed with great care to prevent any inadvertent injuries to the anomalous coronary artery. If the origin of the anomalous coronary artery is at a level higher or cephalad to the commissure, the unroofing of this segment can be performed with little injury risk to the aortic commissural attachments (Fig. 2a). The unroofing technique involves opening the slit-like ostium with fine scissors. The shared wall between the coronary artery and the aortic lumen is excised to the extent of its intramural course. Care should be given not to be too aggressive and cut beyond the shared wall to the outside of the aorta. Next, the edges of the wall are sutured with interrupted fine prolene suture.

If the intramural course is at or below the level of the commissural attachments of the aortic valve, the commissure may require detachment and reattachment to the aortic wall at the appropriate level to prevent a prolapse of the aortic leaflets and aortic insufficiency (Fig. 2b). An alternative procedure is the “fenestration/limited unroofing” that avoids the manipulation of the commissural attachment (Fig. 2c). A probe or right-angle clamp can be passed from the anomalous origin to the point at which the intramural course leaves the aorta from the appropriate sinus. The neo-ostium is created in



**Fig. 2.** (a) Unroofing procedure with intramural segment above commissural level in a patient with ARCA. Aortic valve and commissures are below the level of unroofing incision and are not seen in the picture. On the right side between two arrows is the right sinus of Valsalva where the coronary artery leaves the aortic wall. The tract of intramural segment is probed to be sure of its course and the luminal wall of the coronary is incised to the point at which the coronary artery leaves the aortic wall adjacent to the appropriate sinus of Valsalva. The intimal edges are tacked down with fine monofilament suture. The newly created coronary ostium is seen between small arrow heads and the unroofed intramural segment of the anomalous coronary artery is indicated with big arrow heads. (b) Unroofing procedure in a case with a tunnel below commissural level. Cardiotomy sucker is passed to the left ventricle through aortic valve. Commissure between right and left aortic cusps (large arrow) was detached and intramural course (arrow heads) was incised. Edges were tacked down around the new orifice (small arrow). Commissural attachment, held by the forceps, is being adjusted for the proper level at the aortic wall. (c) Limited unroofing or fenestration. Edges of aortotomy are held with forceps and two arrows are indicating commissure between right and left sinuses of Valsalva. A probe is seen in anomalous coronary ostium adjacent to this commissure. A limited unroofing has been performed only in the correct coronary sinus without detaching commissure. The attached edge of new ostium is in the right sinus of Valsalva above the right coronary cusp (small arrow heads). Copyrighted and used with permission of Mayo Foundation for Medical Education and Research.



**Fig. 3. (a)** Preoperative computed tomography angiography of a patient with anomalous origin of right coronary artery (black arrow heads) from the left sinus of Valsalva with an anomalous course between aorta and pulmonary artery (arrows). White arrow heads indicate the left coronary artery. **(b)** Postoperative computed tomography angiography of the same patient showing the new origin of right coronary artery (arrow heads) from the right sinus of Valsalva. Arrows indicate the pulmonary artery. Copyrighted and used with permission of Mayo Foundation for Medical Education and Research.

the correct coronary sinus by excising the shared wall and eliminating the interarterial course without disturbing the valve commissure.

With the unroofing technique, a new coronary ostium is created in the correct sinus and the course between the PA and aorta is eliminated. The intramural course is no longer present. The postoperative CT angiographic studies can confirm the new origin of the anomalous artery from the correct sinus of the Valsalva (Fig. 3 a, b).

## REFERENCES

1. Click RL, Holmes DR Jr, Vlietstra RE, Kosinski AS, Kronmal RA. Anomalous coronary arteries: location, degree of atherosclerosis and effect on survival-a report from the Coronary Artery Surgery Study. *J Am Coll Cardiol* 1989;13:531-7.
2. Jagers J, Lodge AJ. Surgical therapy for anomalous aortic origin of the coronary arteries. *Semin Thorac Cardiovasc Surg Pediatr Card Surg Annu* 2005;122-7.
3. Gulati R, Reddy VM, Culbertson C, Helton G, Suleman S, Reinhartz O, et al. Surgical management of coronary artery arising from the wrong coronary sinus, using standard and novel approaches. *J Thorac Cardiovasc Surg* 2007; 134:1171-8.
4. Patel S. Normal and anomalous anatomy of the coronary arteries. *Semin Roentgenol* 2008;43:100-12.
5. Basso C, Maron BJ, Corrado D, Thiene G. Clinical profile of congenital coronary artery anomalies with origin from the wrong aortic sinus leading to sudden death in young competitive athletes. *J Am Coll Cardiol* 2000;35:1493-501.
6. Mustafa I, Gula G, Radley-Smith R, Durrer S, Yacoub M. Anomalous origin of the left coronary artery from the anterior aortic sinus: a potential cause of sudden death. Anatomic characterization and surgical treatment. *J Thorac Cardiovasc Surg* 1981;82:297-300.