

Surgical treatment of complicated sternal non-union using multiperforated titanium plates

Komplike sternal ayrılmaların çok delikli titanyum plaka kullanılarak cerrahi tedavisi

Ömer Faruk Doğan

Department of Cardiovascular Surgery, Adana Numune Training and Research Hospital, Adana

Background: In this study, we present a different surgical technique for correction of sternal non-union with the use of titanium plates and screws in eight coronary artery bypass grafting (CABG) patients.

Methods: The Leibinger® titanium multiperforated titanium plate and screw system described for craniofacial fixation was used together with steel wires for re-correction and fixation of sternal non-union in eight CABG patients (5 males, 3 females; mean age 76.4 years; range 67 to 84 years).

Results: Sternal stability and fixation were achieved successfully in all cases. No complications were seen at two years clinical follow-up.

Conclusion: Sternal non-union and dehiscence is a severe complication that causes prolonged hospitalization and increased mortality and morbidity if the patient is not treated. Our surgical approach can be used for surgical treatment of complicated sternal non-union.

Key words: Sternal fracture; sternal nonunion; surgical wire; titanium plate.

Amaç: Bu çalışmada, sekiz koroner arter bypass greftleme (KABG) hastasında titanyum plaka ve vida kullanılarak sternal ayrılmanın düzeltilmesine yönelik farklı bir cerrahi yaklaşım sunuldu.

Çalışma planı: Kraniyofasyal tespit için tanımlanmış olan Leibinger® çokdelikli titanyum plaka ve titanyum vida sistemi sekiz KABG hastasında (5 erkek, 3 kadın; ort. yaş 76.4 yıl; dağılım 67-84 yıl) sternumun tekrar onarımı ve tespiti için çelik telle beraber kullanıldı.

Bulgular: Sternal stabilite ve tespit tüm hastalarda başarıyla sağlandı. İki yıllık klinik takiplerde herhangi bir komplikasyon görülmedi.

Sonuç: Sternumun tekrar ayrılması cerrahi olarak tedavi edilmediğinde hastanede yatış süresini uzatan, mortalite ve morbiditeye neden olabilen ciddi bir komplikasyondur. Cerrahi yöntemimiz sternumun komplike ayrılmalarının cerrahi tedavisinde uygulanabilir.

Anahtar sözcükler: Sternum kırığı; sternumda ayrılma; cerrahi tel; titanyum plaka.

Surgical steel wire is used for sternal closure after median sternotomy. Unfortunately, sternal non-union is a severe complication of sternotomy closure that can be seen after open heart operations. In the literature, healing complications have been reported in 0.3% to 5% of cases and are associated with a 14-47% mortality rate if mediastinitis supervenes.^[1,2] Obesity, diabetes mellitus, osteoporosis and prior sternotomy increase the incidence of sternal non-union. Because sternal non-union is a rare complication there is no consensus on how to treat these particular patients and different surgical approaches and materials have been defined. Leibinger fixation systems have been well established in plastic and neurosurgery for fixation of facial fractures, but there is limited experience with their use for sternal correction, including a

boy with primitive sternal tumor by Sunil et al.^[3] We describe a different technical approach for correction of sternal non-union with the use of Leibinger titanium plates and screws in eight coronary artery bypass grafting (CABG) patients.

PATIENTS AND METHODS

We used this device in our eight CABG patients (5 males, 3 females; mean age 76.4 years; range 67 to 84 years) for surgical correction of sternal non-union. All patients had multi-vessel coronary artery disease. Five patients had insulin-dependent diabetes mellitus, one patient had hyper parathyroidism and one patient had non-small cell pulmonary carcinoma. Mean body mass index was 26 (min.: 25; max.: 32). In two cases, sternal dehiscence

Received: November 19, 2009 Accepted: March 1, 2010

Correspondence: Ömer Faruk Doğan, M.D. Adana Numune Eğitim ve Araştırma Hastanesi Kalp ve Damar Cerrahisi Kliniği, 01150 Seyhan, Adana, Turkey. Tel: +90 322 - 246 26 54 e-mail: ofdogan@hacettepe.edu.tr

developed in the early postoperative period. In the remaining six patients, sternal non-union developed in the late postoperative period. Patients' characteristics, metabolic disorder, time interval from operation to dehiscence and clinical follow-up are listed in table 1.

Sternal instability was detected using physical and radiologic examination in all patients. Thoracic computed tomography (CT) was used in three patients. All patients had multi-vessel coronary artery disease. Saphenous vein and left internal thoracic artery grafts had been used in all patients. The characteristics of previous operations including cardiopulmonary bypass time, graft selection, duration of hospitalization are summarized in table 2.

Surgical technique

After midline sternotomy incision, the steel wires were removed. Mediastinal adhesions were released using blunt dissection and low voltage electrocautery. There was severe sternal fracture in all cases. Pseudoarthrosis was debrided and bone particles were carefully removed (Fig. 1). Sterno-costal junctions were clearly visualized from manubrium to xiphoid. The pectoralis muscles were dissected from the sternal edge about 10 cm beyond the costo-sternal junctions bilaterally. Before the insertion of titanium plates, the sternal incision was closed with the use of surgical steel wire. After this, multiperforated titanium plates were fixed using titanium screws (Fig. 2).

In our procedure, treatment of dehiscence involved two components: In the first; approximation of the sternum was provided by steel wires. Steel wires were inserted in a figure-of-eight fashion and the sternum was closed. In the second; the plates were set into the manubrium of the sternum using the screws' drill bit. Therefore, we implanted the devices on the manubrium and distal part of the sternum. Two titanium plates were fixed bilaterally with the aid of titanium screws.

RESULTS

There is no mortality and morbidity in our patients. No lateral movement or sliding was observed in all patients. No instability was detected after closure of the sternum. Patient activity was limited 2-4 weeks during recovery until they became pain free. Posteroanterior and lateral chest X-rays were used for examination of the patients postoperatively (Fig. 3a, b). There was no sternal non-union in our patients. Thoracic CT examination was performed in three patients in the 3rd and 4th postoperative month. No complications were seen and sternal healing was successfully achieved in all patients on clinical follow-up at 7-24 months.

DISCUSSION

Because of easy application after open heart operations, the most common method to close a median sternotomy incision is to twist together six or more

Table 1. Patients' characteristics

No	Age/gender	Metabolic disorder	From operation to dehiscence (month)	Follow-up (month)	CT (month)
1	75/F	Diabetes mellitus	1	11	3
2	67/M	Hyperparathyroid	4	15	–
3	71/F	–	7	9	–
4	84/F	Diabetes mellitus	4. day	7	4
5	72/M	Pulmonary non-small cell cancer	6	6.5	3
6	68/M	Diabetes mellitus	5	8	–
7	69/M	Diabetes mellitus	4.4	24	–
8	67/M	Diabetes mellitus	3. day	22	–

CT: Computed tomography (time after operation).

Table 2. Characteristics of the operations'

No	CPB time (min.)	Type of grafts	Duration of hospitalization (day)	Resternotomy	Infection
1	46	IMA and SV	8	No	No
2	52	IMA and SV	6	No	No
3	65	IMA and SV	5	No	No
4	52	IMA and SV	11	No	No
5	48	IMA and SV	5	No	No
6	60	IMA and SV	6	No	No
7	56	IMA and SV	9	No	No
8	61	IMA and SV	10	No	No

CPB: Cardiopulmonary bypass; IMA: Internal mammary artery; SV: Saphenous vein;

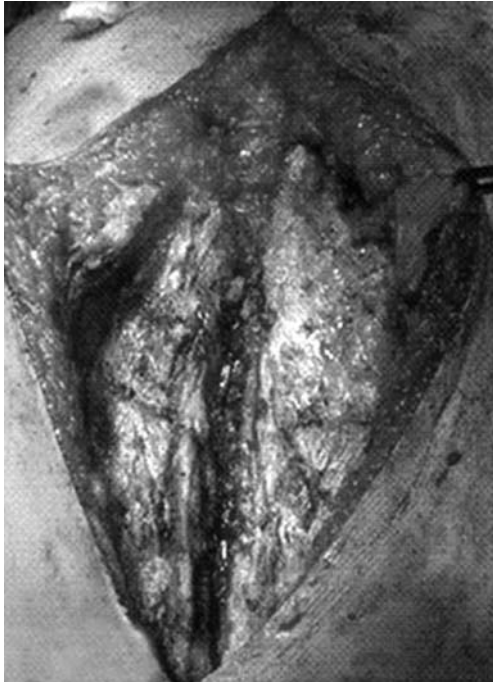

Fig. 1. Pseudoarthrosis and fractured bone materials are carefully cleared along the sternum. The edges of the sternum should be free from the adhesions.

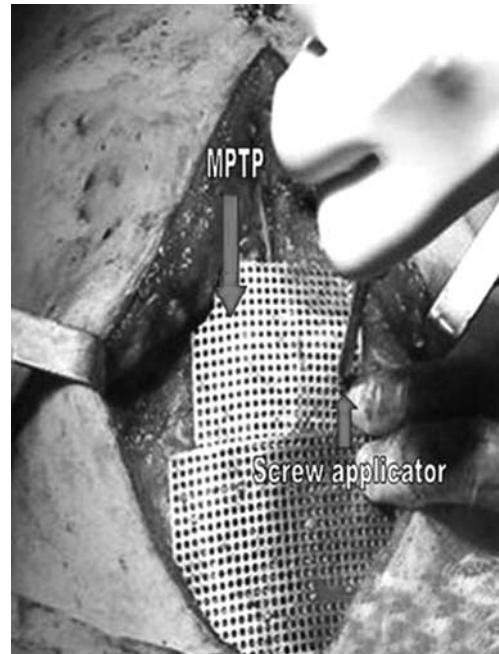


Fig. 2. The fixation of the plate with the aid of screws. To prevent the laceration of posterior sternal side by screws digital control should be performed. MPTP: Multiperforated titanium plate; The red arrowhead: Demonstrates the special applicator of screw.

transverse surgical steel wires. In the English literature, alternative techniques for closure of sternotomy have been described. These have included differences in the number and orientation of the wire or ethibond sutures, differences in the circumferential closure materials used

either in addition to or instead of stainless steel wire or completely different techniques such as the use of poly L-lactide sternal pins^[4] and thermo reactive nitillium clips.^[5] However, dehiscence of the sternum can be seen as a serious and potentially devastating complication

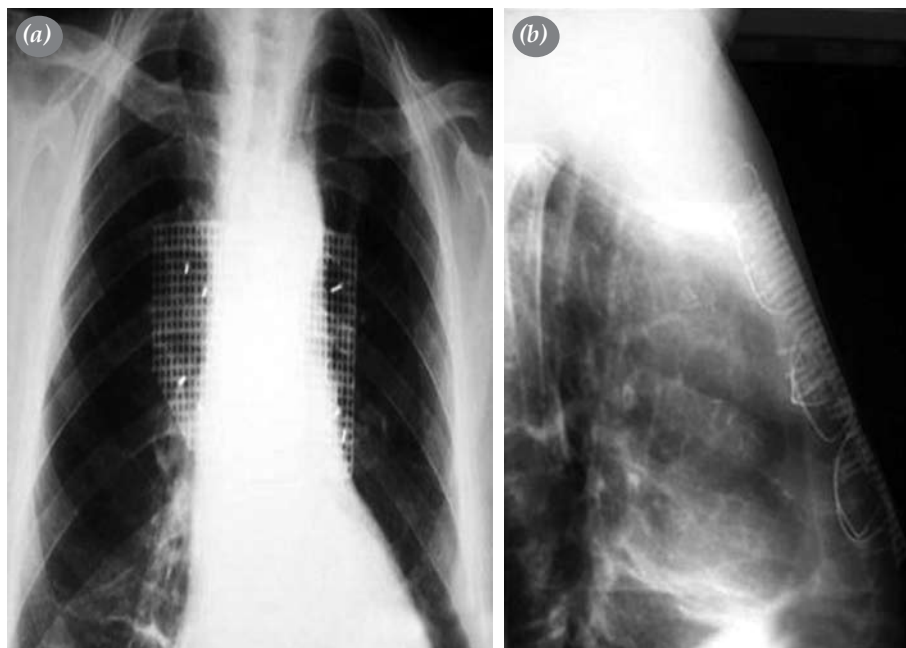


Fig. 3. Are showing the plates and screws from the (a) postero-anterior and (b) lateral chest X-ray film.

that can cause pulmonary dysfunction, chest wall discomfort, superficial and mediastinal infections.

Sternal motion and instability may occur in the first days or weeks after median sternotomy owing to technical issues with the bone, wire or surgical technique. This may resolve and heal normally or it may lead to dehiscence because of fracture of the sternal bone or the sternal wires. There is no consensus for optimal consideration of median sternotomy closure when sternal non-union is seen. Because this clinical state is rare only a few studies have addressed sternal nonunion and its treatment. A number of new techniques have been defined over the years, including rigid or semirigid fixation, and suture anchors with or without bone grafts.^[6-13] However, the use of plates in the practice of cardiac surgery is rare and the most effective placement of plates has not been defined.

In our patients, we used two plates for approximation of the sternum after applying steel wires in figure-of-eight fashion. We achieved sternal stabilization with this technique. Our clinical follow-up has shown that there was no complication due to surgical method or device. One reason for these findings could be that the rigid titanium plates and screws block the motion of the ribs. Based on this consideration it is preferable to choose transverse plates that are as short as possible. Drilling and screwing for plate fixation involves the danger of damaging blood vessels or other mediastinal or pleural structures. It is difficult to measure the proper depth of the ribs especially in transverse plate fixation. This is crucial because bicortical screw placement is preferable to provide stability. Careful orientation and surgical approach is a major concern. Drilling too deep or choosing too long screws risks lung or internal mammary artery injury. As part of our standard technique in sternal re-fixation, we dissected the sternal border to remove fibrous tissue and thus to promote firm healing of bone. Sternal stability was restored to its former condition by longitudinal plating. In case of widely resected or lost sternal bone, the longitudinal plates were connected to the residual sternum or ribs. To avoid bone destruction we applied a minimal number of screws.

It is known that the mixture of stainless steel and titanium can create an electromagnetic effect. Theoretically, this could result in a local tissue reaction or inflammation. Even after two years clinical follow-up we have not seen any signs indicating such a reaction. In fact, the contact area between the different metals is very small and probably not sufficient to create a relevant electromagnetic effect. Mitra et al.^[19] and Voss et al.^[20] have previously suggested a similar mix-technique, and did not see any reaction.

Our results confirm that titanium plate fixation is an applicable technique for stabilization of sternal non-union after median sternotomy in complicated patients. In our study complete thoracic stabilization using two titanium plates placement was achieved. Oversize transverse plate fixation may lead to severe compression of the lung. The limitation in quality of sternal bone is addressed by using strong enough materials such as the titanium plate and screwing system. The benefits of this new technique may be convenient for surgeons closing sternotomies especially in cases with sternal non-union or those under risk of non-union. In conclusion, sternal plating, which is based on the tension-band principle, is an effective treatment of sternal non-union due to multiple fractured sternal bone. This simple technique can be considered for both simple and complex non-unions after midline sternotomy closure. The titanium plates are stronger than steel and resist bending stresses, and the cortical bone resists compressive forces during respiration and upper extremity movement.

Declaration of conflicting interests

The authors declared no conflicts of interest with respect to the authorship and/or publication of this article.

Funding

The authors received no financial support for the research and/or authorship of this article.

REFERENCES

1. Satta J, Lahtinen J, Räisänen L, Salmela E, Juvonen T. Options for the management of poststernotomy mediastinitis. *Scand Cardiovasc J* 1998;32:29-32.
2. El Oakley RM, Wright JE. Postoperative mediastinitis: classification and management. *Ann Thorac Surg* 1996;61:1030-6.
3. Sunil I, Bond SJ, Nagaraj HS. Primitive neuroectodermal tumor of the sternum in a child: resection and reconstruction. *J Pediatr Surg* 2006;41:e5-8.
4. Saito T, Iguchi A, Sakurai M, Tabayashi K. Biomechanical study of a poly-L-lactide (PLLA) sternal pin in sternal closure after cardiothoracic surgery. *Ann Thorac Surg* 2004;77:684-7.
5. Negri A, Manfredi J, Terrini A, Rodella G, Bisleri G, El Quarra S, et al. Prospective evaluation of a new sternal closure method with thermoreactive clips. *Eur J Cardiothorac Surg* 2002;22:571-5.
6. Dogan OF, Oznur A, Demircin M. A new technical approach for sternal closure with suture anchors (Dogan technique). *Heart Surg Forum* 2004;7:E328-32.
7. Dogan OF, Demircin M, Duman U, Ozsoy F, Acaroglu E. The use of suture anchors for sternal nonunion as a new technical approach (Demircin-Dogan technique). *Heart Surg Forum* 2005;8:E364-9.
8. Hendrickson SC, Koger KE, Morea CJ, Aponte RL, Smith PK, Levin LS. Sternal plating for the treatment of sternal

- nonunion. *Ann Thorac Surg* 1996;62:512-8.
9. Coons DA, Pitcher JD, Braxton M, Bickley BT. Sternal non-union. *Orthopedics* 2002;25:89-91.
 10. Eich BS, Heinz TR. Treatment of sternal nonunion with the Dall-Miles cable system. *Plast Reconstr Surg* 2000;106:1075-8.
 11. Bertin KC, Rice RS, Doty DB, Jones KW. Repair of transverse sternal nonunions using metal plates and autogenous bone graft. *Ann Thorac Surg* 2002;73:1661-2.
 12. Wu LC, Renucci J, Song DH. Rigid-plate fixation for the treatment of sternal nonunion. *J Thorac Cardiovasc Surg* 2004;128:623-4.
 13. Tavilla G, van Son JA, Verhagen AF, Lacquet LK. Modified Robicsek technique for complicated sternal closure. *Ann Thorac Surg* 1991;52:1179-80.
 14. Mansour KA, Thourani VH, Losken A, Reeves JG, Miller JI Jr, Carlson GW, et al. Chest wall resections and reconstruction: a 25-year experience. *Ann Thorac Surg* 2002;73:1720-5.
 15. Yuen JC, Zhou AT, Serafin D, Georgiade GS. Long-term sequelae following median sternotomy wound infection and flap reconstruction. *Ann Plast Surg* 1995;35:585-9.
 16. Robicsek F, Daugherty HK, Cook JW. The prevention and treatment of sternum separation following open-heart surgery. *J Thorac Cardiovasc Surg* 1977;73:267-8.
 17. Pai S, Gunja NJ, Dupak EL, McMahan NL, Roth TP, Lalikos JF, et al. In vitro comparison of wire and plate fixation for midline sternotomies. *Ann Thorac Surg* 2005;80:962-8.
 18. Ozaki W, Buchman SR, Iannettoni MD, Frankenburg EP. Biomechanical study of sternal closure using rigid fixation techniques in human cadavers. *Ann Thorac Surg* 1998;65:1660-5.
 19. Mitra A, Elahi MM, Tariq GB, Mir H, Powell R, Spears J. Composite plate and wire fixation for complicated sternal closure. *Ann Plast Surg* 2004;53:217-21.
 20. Voss B, Bauernschmitt R, Will A, Krane M, Kröss R, Brockmann G, et al. Sternal reconstruction with titanium plates in complicated sternal dehiscence. *Eur J Cardiothorac Surg* 2008;34:139-45.