

## **A multidisciplinary approach to aorto-esophageal fistula: a case report**

*Aorto-özofageal fistüle yönelik çok disiplinli bir yaklaşım: Olgu sunumu*

**Walid Abu Arab,<sup>1</sup> François Chagnon,<sup>1</sup> Vincent Echavé,<sup>1</sup> Dominique Dorion,<sup>2</sup> Marco Sirois<sup>1</sup>**

Departments of <sup>1</sup>Thoracic Surgery, <sup>2</sup>Otolaryngology, Faculty of Medicine and Health Sciences,  
University of Sherbrooke, Sherbrooke, QC, Canada

Aorto-esophageal fistula is a rare emergency condition. Rapid diagnosis and management may help to save lives. We report here a case of a 60-year-old man who presented with aorto-esophageal fistula. The fistula was managed with aortic vascular endoprosthesis. An esophageal reconstruction was initially achieved with a gastric pull-up, which unfortunately failed, and subsequently, the patient underwent esophageal reconstruction using myocutaneous flap. The patient is still living with a good quality of daily life.

**Key words:** Aortic aneurysm/thoracic; aorto-esophageal fistula; diagnosis.

Aorto-esophageal fistula (AOF) is a rare (0.01%-0.08%) but fatal cause of massive upper gastrointestinal haemorrhage with few reported survivors.<sup>[1-3]</sup> They most commonly result from aneurysm rupture into an adjacent viscus or progressive erosion of a prosthetic graft or suture line, ruptured atherosclerotic ulcers in the thoracic aorta, foreign bodies, esophageal or bronchogenic malignancies, esophageal resections, esophageal stenting and trauma.<sup>[4-6]</sup> The surgical intervention should involve repair of both esophageal erosion and aortic aneurysm to avoid terminal exsanguination and uncontrollable mediastinitis.<sup>[7]</sup>

### **CASE REPORT**

A 60-years-old man was admitted to the emergency department of Sherbrook University Medical Centre (CHUS) with hematemesis. His past medical history included left thoracotomy for empyema, colonic diverticulosis, and chronic obstructive lung disease. He was a heavy alcoholic and obese. Stabilization of the patient was achieved and upper endoscopy was performed. A pulsatile lesion at the mid-esophagus was discovered with erosion of the esophageal mucosa over

Aorto-özofageal fistül nadir görülen bir acil durumdur. Hızlı tanı ve tedavi hayat kurtarılmasına yardımcı olabilir. Bu yazıda aorto-özofageal fistülü olan 60 yaşında bir erkek hastayı içeren bir olgu sunuldu. Fistül aort vasküler endoprotezi ile tedavi edildi. İlk olarak mideye "pull-up" ile özofageal rekonstrüksiyon sağlandı ancak bu maalesef başarısız oldu ve bunun ardından hastaya miyokütanöz flep ile özofageal rekonstrüksiyon uygulandı. Hasta halen hayattadır, iyi ve kaliteli bir günlük yaşam sürmektedir.

**Anahtar sözcükler:** Aort anevrizması/torasik; aorto-özofageal fistül; tanı.

this pulsatile lesion. Thoracic computed tomography (CT)-scan showed multiple saccular aneurysms of the descending thoracic aorta. The largest one was 8 cm wide, compressing and eroding the mid-esophagus. Angiography using a right femoral approach was performed on the spots where aneurysms were confirmed in the descending aorta; from the insertion of the subclavian artery to the celiac trunk. Four endoprostheses were inserted to completely cover the descending thoracic aorta. Following endovascular intervention, the patient suffered paraparesis. Investigations revealed T<sub>9</sub>-T<sub>10</sub> myelopathy secondary to spinal cord ischemia produced by the endoprostheses, which was temporary and the patient recovered soon after without medical or surgical management.

One month later, a gastrografen study was performed as part of follow-up. Leakage of contrast was noticed around the endoprostheses. The patient was treated conservatively with antibiotics and a feeding jejunostomy. However, the patient was not compliant, and maintained oral alimentation. Two months later, the patient was operated upon and complete esophageal exclusion with cervical esophagostomy was performed

*Received:* November 5, 2008 *Accepted:* February 11, 2009

Correspondence: Walid Abu Arab, M.D. Service de chirurgie thoracique Faculté de Médecine et des Sciences de la Santé, Université de Sherbrooke 3001 12e avenue nord, Sherbrooke, J1H 5N4, QC, Canada. Tel: 1 (819) 346 1110 / 12371 e-mail: walidabuarab@yahoo.com

to minimize contamination of the endoprosthesis. One-year later, an upper digestive tract reconstruction was achieved. A retrosternal gastric pull-up with cervical esophago-gastric anastomosis was performed. The native esophagus with site of perforation was left in place and the retrosternal route was used because the posterior mediastinum was the site of an important inflammatory reaction. One-week postoperatively, gastrografin study elicited a small leak at the anastomotic site. Three-weeks postoperatively, the patient developed mediastinitis. A thoracic CT-scan confirmed a persistent leak with an abscess around the gastric pull-up. The patient was operated on, and the upper part of the gastric pull-up was shown to suffer severe ischemia with necrosis. Drainage and debridement of the anastomotic site was performed.

Later, an esophageal reconstruction was achieved with collaboration of the ear nose and throat department. The anterior gap between the cervical esophagus and the remaining part of the gastric pull-up (Fig. 1) was reconstructed with a left pectoralis major myocutaneous flap (Fig. 2). The postoperative course was uneventful. On follow-up, he complained of dysphagia. Upper endoscopy showed an efficient anastomosis with hair emerging from the wall of the neo-esophagus. In addition, there was stenosis at the cervical portion of the esophagus, a few centimeters above the anastomosis. It was thought to be ischemic in nature. Repeated endoscopic dilatations were performed and the patient is still living with good quality of daily life.

## DISCUSSION

Aorto-esophageal fistula is a rare and fatal cause of massive gastrointestinal bleeding.<sup>[1-3]</sup> Endoscopy is the preferred initial method of assessment.<sup>[2]</sup> Thoracic CT

is the most important tool in diagnosis and planning for management.<sup>[8]</sup>

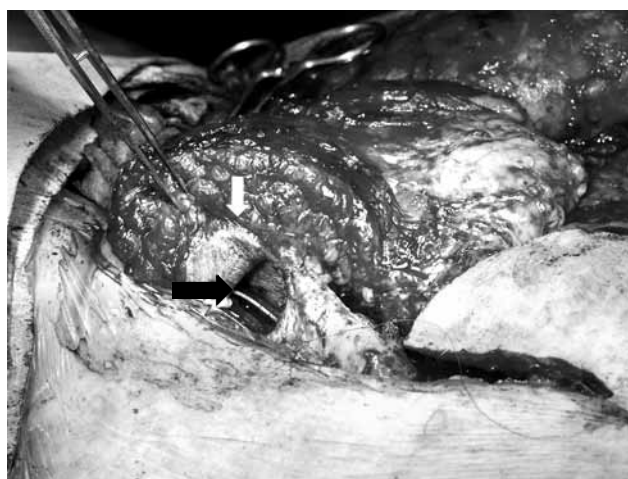
Management should not be delayed once AOF is diagnosed. Management consists of two essential parts. First is stabilization of the patient and control of bleeding with repair of aortic aneurysm as it saves the life of the patient. The second step is repair of the esophageal defect.<sup>[7-8]</sup> Different methods of aortic repair are mentioned in the literature, including direct aortic suture, patch angioplasty, in-situ graft replacement, and recently percutaneous endovascular stent grafting.<sup>[3,5,8]</sup>

Our patient was high-risk with multiple co-morbidities so we preferred a rapid and less invasive technique to control bleeding and repair the aortic aneurysm. We used percutaneous endovascular stent grafting to manage the aortic aneurysm and tried to manage the esophageal defect conservatively due to the bad general condition of the patient. Endovascular stenting succeeded in controlling the bleeding and repaired the aortic aneurysm effectively and rapidly.

Controversy exists with regard management of the esophageal defect. Mediastinitis and death may result from neglect of this condition. From our experience, we agree with others that conservative management is of no help especially in non-compliant patients like ours.<sup>[8,9]</sup> In our patient, esophageal exclusion and debridement were considered the best management followed by restoration of esophageal continuity with gastric pull-up. We used a pectoral myocutaneous flap for secondary esophageal reconstruction when anastomotic dehiscence at the upper anastomosis of the gastric pull-up had occurred.



**Fig. 1.** Median sternotomy incision showing the retrosternal position of the stomach (white arrow) with nasogastric tube inserted at the anastomotic dehiscence site anteriorly (black arrow).



**Fig. 2.** Repair of anastomotic dehiscence of the gastric pull-up with aid of the pectoralis major myocutaneous flap (white arrow shows the skin edge that are reflected anteriorly to be sutured to the edge of posterior wall of the anastomotic site to restore the continuity of the lumen, while the black arrow shows the lumen with a nasogastric tube inside).

Conservative management was not considered effective in this debilitated patient.

This case is another successful case of percutaneous endovascular stent grafting for treatment of the AOF with restoration of continuity of the digestive tract with gastric interposition and the use of pectoralis major myocutaneous flap.

In conclusion, in expert hands, percutaneous endovascular stent grafting is a rapid and effective method to control bleeding in the treatment of AOF. Esophageal reconstruction is a must to eliminate the occurrence of mediastinitis and its sequelae. However, when primary resection fails, secondary repair with myocutaneous flaps can be used with success.

#### **Declaration of conflicting interests**

The authors declared no conflicts of interest with respect to the authorship and/or publication of this article.

#### **Funding**

The authors received no financial support for the research and/or authorship of this article.

#### **REFERENCES**

1. Peck JJ, Eidemiller LR. Aortoenteric fistulas. Arch Surg 1992;127:1191-3.
2. Hariya A, Makuuchi H, Naruse Y, Kobayashi T, Ogata K, Tsurumaru M. Successful management of aorto-esophageal fistula due to rupture of thoracic aortic aneurysm in an elderly patient. Jpn J Thorac Cardiovasc Surg 1998; 46:777-80.
3. Pellizzari N, Reimers B, Saccà S, Pasquetto G, Cernetti C, Napodano M, et al. Percutaneous endovascular stent-graft placement for the treatment of acute rupture of an aneurysm of the thoracic aorta. Ital Heart J 2002;3:427-30.
4. Montgomery RS, Wilson SE. The surgical management of aortoenteric fistulas. Surg Clin North Am 1996;76:1147-57.
5. Marone EM, Baccari P, Brioschi C, Tshomba Y, Staudacher C, Chiesa R. Surgical and endovascular treatment of secondary aorto-esophageal fistula. J Thorac Cardiovasc Surg 2006;131:1409-10.
6. Maher MM, Murphy J, Dervan P, O'Connell D. Aorto-oesophageal fistula presenting as a submucosal oesophageal haematoma. Br J Radiol 1998 ;71:972-4.
7. Myers HS, Silber W. Oesophageal bleeding from aorto-oesophageal fistula due to aortic aneurysm. S Afr Med J 1983; 63:124-7.
8. Pirard L, Creemers E, Van Damme H, Laurent S, Honoré P, Limet R. In situ aortic allograft insertion to repair a primary aorto-esophageal fistula due to thoracic aortic aneurysm. J Vasc Surg 2005;42:1213-7.
9. Vogt PR, Brunner-LaRocca HP, Lachat M, Ruef C, Turina MI. Technical details with the use of cryopreserved arterial allografts for aortic infection: influence on early and mid-term mortality. J Vasc Surg 2002;35:80-6.