

Early spontaneous reperfusion in the right coronary artery of a patient with acute inferior myocardial infarction

Akut inferiyor miyokardiyal infarktüsülü bir hastada sağ koroner arterde erken spontan reperfüzyon

Tansu Karahmet, Nurşen Keleş, Yusuf Emre Gürel, Tayfun Güneysu, Bülent Mutlu, Yelda Başaran

Department of Cardiology, Koşuyolu Kartal Heart Education and Research Hospital, İstanbul

The spontaneous reperfusion frequently observed during acute myocardial infarction. Spontaneous reperfusion before primary percutaneous transluminal coronary angioplasty is an independent determinant of improved outcome. The determination of plaque vulnerability is crucial.

Key words: Angioplasty; spontaneous reperfusion; sensitive plate.

The significance and implications of the clinical markers of spontaneous reperfusion (SR) during acute myocardial infarction (AMI) have not yet been investigated in detail. The reported incidence of SR during AMI varies widely (7-57%).^[1-6] Recent studies have shown that SR before primary percutaneous transluminal coronary angioplasty (PTCA) is an independent determinant of procedural success, myocardial salvage, and improved outcome.^[4-6] Determination of plaque vulnerability is crucial in patients with AMI after early SR.

CASE REPORT

A 56-year-old man was admitted to our center with severe chest pain which began one hour previously. Upon admission, the blood pressure was 130/60 mmHg, and the remaining physical examination was unremarkable. The laboratory examination, including C-reactive protein, was normal except for mild leucocytosis (12600/mm³). An electrocardiogram revealed 2 mm ST segment elevation in inferior leads (Figure 1a), and the patient

Akut miyokard infarktüsü sırasında spontan reperfüzyon sık olarak gözlenir. Primer perkütan transluminal koroner anjiyoplasti öncesi spontan reperfüzyon olması iyi sonlanımın bağımsız belirteçidir. Bu hastalarda plak duyarlılığının tanınması kritik rol oynar.

Anahtar sözcükler: Anjiyoplasti; spontan reperfüzyon; duyarlı plak.

was admitted to the catheterization laboratory for primary PTCA with a diagnosis of acute inferior myocardial infarction. Before the procedure, the patient was given 5000 U intravenous heparin, 300 mg aspirin, and 600 mg clopidogrel. A selective right coronary angiography (CAG) revealed that the mid region of the right coronary artery was obstructed by abundant thrombus with thrombolysis in myocardial infarction (TIMI) grade 0 flow (Figure 1b). By that time, marked bradycardia had developed with a heart rate of 40/min. This necessitated a temporary pacemaker implantation and a removal of the guiding catheter. After the temporary pacemaker implantation, the right guiding catheter was inserted again, and a second film, obtained within five minutes of the first one, interestingly demonstrated spontaneous reperfusion of the right coronary artery with TIMI grade 3 flow and distal embolization of the thrombus (Figure 1c). After SR with TIMI grade 3 flow, the chest pain entirely disappeared, and the ST segment elevation rapidly recovered (Figure 2a). Because of the distal embolization of thrombus, intravenous

Received: January 18, 2007 *Accepted:* July 22, 2008

Correspondence: Tansu Karahmet, M.D. Acıbadem Üniversitesi Tıp Fakültesi Kardiyoloji Anabilim Dalı, 34848 Maltepe, İstanbul, Turkey.
Tel: +90 212 - 414 40 28 e-mail: drtansukara@yahoo.co.uk

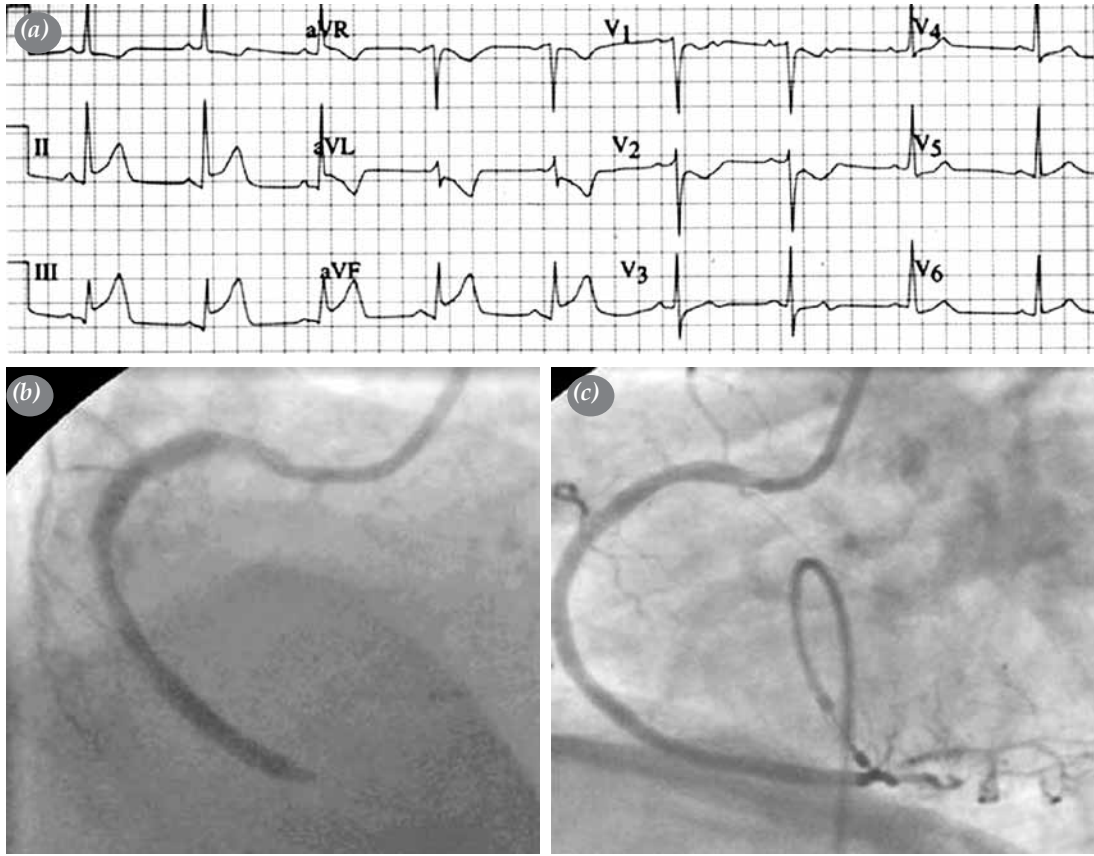


Figure 1. (a) Electrocardiogram in acute phase. (b) coronary angiography imaging in admission. (c) After spontaneous reperfusion in coronary angiography imaging.

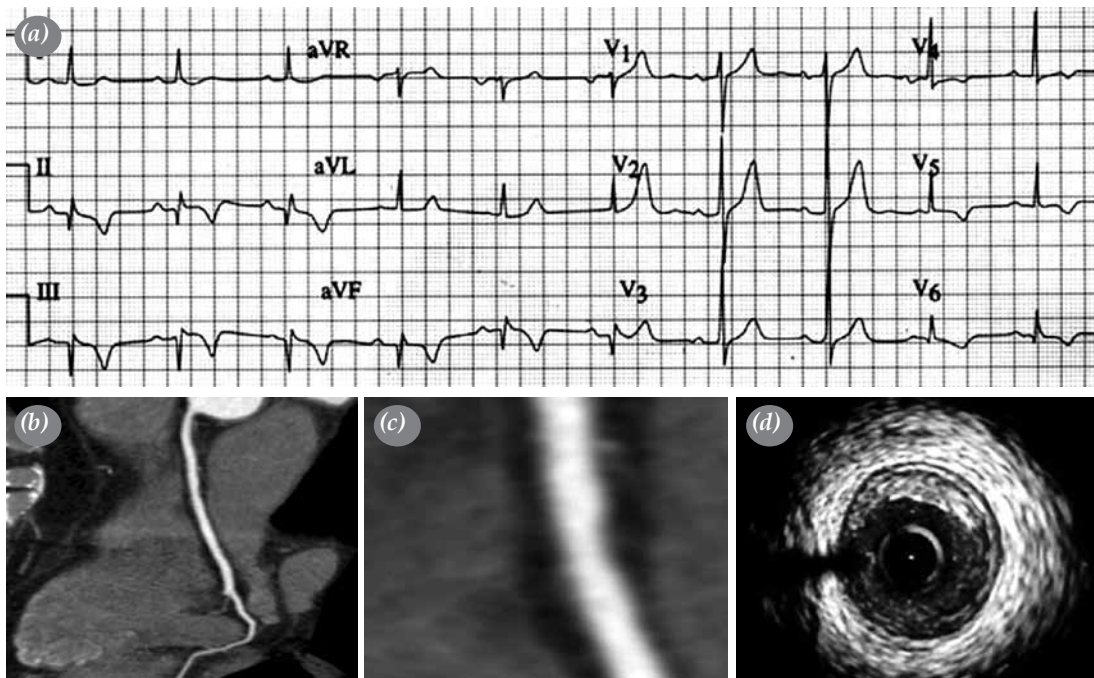


Figure 2. (a) Electrocardiogram after spontaneous reperfusion. (b, c) Multislice CT coronary angiography imaging of right coronary artery and culprit lesion, (d) intravascular ultrasound imaging of culprit lesion.

tirofiban infusion was administered for 48 hours. The patient was then medicated with aspirin 300 mg/day, clopidogrel 75 mg/day, and enoxaparine 1 mg/kg/12 hours. In addition, the patient received a beta bloker, ACE inhibitor, and statin therapy. The maximum troponin concentration was 0.249 ng/ml, and the cardiac enzymes remained within normal limits. During in-hospital follow-up, no complications occurred, and the patient was discharged six days later.

One week later, a computed tomography angiography (CTA) was performed which demonstrated non-significant atherosclerotic plaque in the mid region of the right coronary artery where the obstructive thrombus had been initially observed (Figures 2b, c). Also, one month after initial admission, an intravascular ultrasound (IVUS) examination of the right coronary artery was performed, and vulnerable plaque was shown at the same location of the obstructive thrombus (Figure 2d).

DISCUSSION

Despite primary PTCA, a substantial number of patients fail to achieve complete coronary patency. However, some patients have SR on preintervention angiograms.^[4] Early SR is probably due to relief of coronary spasms, endogenous lysis of thrombus, or both.^[7,8] Administration of aspirin, heparin, and clopidogrel before the procedure may also contribute to SR. Plaque vulnerability plays a crucial role in the management of disease, as well. Imaging techniques, such as IVUS, may detect additional characteristics of plaque and assess the risk of vulnerable plaque.

Declaration of conflicting interests

The authors declared no conflicts of interest with respect to the authorship and/or publication of this article.

Funding

The authors received no financial support for the research and/or authorship of this article.

REFERENCES

1. Steg PG, Himbert D, Benamer H, Karrillon G, Boccara A, Aubry P, et al. Conservative management of patients with acute myocardial infarction and spontaneous acute patency of the infarct-related artery. *Am Heart J* 1997;134:248-52.
2. DeWood MA, Spores J, Notske R, Mouser LT, Burroughs R, Golden MS, et al. Prevalence of total coronary occlusion during the early hours of transmural myocardial infarction. *N Engl J Med* 1980;303:897-902.
3. Christian TF, Milavetz JJ, Miller TD, Clements IP, Holmes DR, Gibbons RJ. Prevalence of spontaneous reperfusion and associated myocardial salvage in patients with acute myocardial infarction. *Am Heart J* 1998;135:421-7.
4. A clinical trial comparing primary coronary angioplasty with tissue plasminogen activator for acute myocardial infarction. The Global Use of Strategies to Open Occluded Coronary Arteries in Acute Coronary Syndromes (GUSTO IIb) Angioplasty Substudy Investigators. *N Engl J Med* 1997;336:1621-8.
5. Lee CW, Hong MK, Lee JH, Yang HS, Kim JJ, Park SW, et al. Determinants and prognostic significance of spontaneous coronary recanalization in acute myocardial infarction. *Am J Cardiol* 2001;87:951-4; A3.
6. Stone GW, Cox D, Garcia E, Brodie BR, Morice MC, Griffin J, et al. Normal flow (TIMI-3) before mechanical reperfusion therapy is an independent determinant of survival in acute myocardial infarction: analysis from the primary angioplasty in myocardial infarction trials. *Circulation* 2001;104:636-41.
7. Maseri A, L'Abbate A, Baroldi G, Chierchia S, Marzilli M, Ballestra AM, et al. Coronary vasospasm as a possible cause of myocardial infarction. A conclusion derived from the study of "preinfarction" angina. *N Engl J Med* 1978;299:1271-7.
8. Folts JD, Crowell EB Jr, Rowe GG. Platelet aggregation in partially obstructed vessels and its elimination with aspirin. *Circulation* 1976;54:365-70.