

Direct cannulation of axillary artery via transpectoral approach in ascending aorta and aortic arch surgery

Çıkan aort ve arkus aort cerrahisinde transpektoral yaklaşımla aksiller arterin direkt kanülasyonu

Gökhan Özerdem,¹ Özcan Özdemir,² Bülent Kaya³

Departments of ¹Cardiovascular Surgery, ²Cardiology, Çağ Hospital, Ankara;
³Department of Cardiovascular Surgery, Medicine Faculty of Ankara University, Ankara

Background: Right axillary artery cannulation provides some advantages in case of circulatory arrest during cardiopulmonary bypass (CPB), including antegrade whole body perfusion flow and unilateral antegrade cerebral perfusion, without requiring any additional cannulation of brachiocephalic arteries and eliminates the need to recannulate the graft before reestablishing CPB in aortic dissection cases.

Methods: We performed right axillary artery cannulation in 82 patients (38 males, 44 females; mean age 59.5±10.6 years; range 32 to 85 years) with the ascending aorta or aortic arch pathologies. Preoperative diagnosis was classified as aneurysm of the ascending aorta or aortic arch due to arteriosclerosis or degeneration (n=46, 56.1%), acute type A aortic dissection (n=28, 34.1%), and porcelain aorta (n=6, 7.3%). All of the patients underwent replacement of the ascending aorta and in 21 of these patients, replacement of the ascending aorta was extended to the hemiarch. Five of the patients underwent total aortic arch replacement. A modified Bentall procedure was performed on 52 patients, and supracoronary graft implantation was performed on 30 patients.

Results: According to clinical examination no complications related to axillary artery cannulation, such as brachial plexus injury, axillary artery thrombosis, or local wound infection, were observed. The mean CPB time and aortic cross-clamp time were 190.8±62.0 min and 72.0±21.7 min, respectively.

Conclusion: Postoperatively, five patients died and one patient developed a new stroke. We think that the full-flow CPB performed using axillary cannulation via transpectoral approach with subclavicular incision is a feasible and safe method with acceptable morbidity and mortality.

Key words: Aortic arch; ascending aorta; right axillary artery cannulation.

Amaç: Sağ aksiller arter kanülasyonu, kardiyopulmoner bypass (CPB) esnasında dolaşım aresti durumunda brakiyosefalik arterlere ek kanülasyon gerektirmeden antegrad tüm vücut perfüzyonu ve tek taraflı antegrad beyin perfüzyonu gibi bazı avantajlar sağlar ve aort diseksiyonunda CPB'nin yeniden tesisi öncesinde greftin kanülasyonuna gerek bırakmaz.

Çalışma planı: Çıkan aort ve arkus aort patolojileri olan 82 hastada (38 erkek, 44 kadın; ort. yaş 59.5±10.6 yıl; dağılım 32-85 yıl) sağ aksiller arter kanülasyonu uygulandı. Ameliyat öncesi tanıda çıkan aort ve arkus aort anevrizmalarının nedeni arteriyoskleroz veya dejenerasyon (n=46, %56.1), akut tip A aortik diseksiyon (n=28, %34.1) ve porselen aort (n=6, %7.3) olarak sınıflandırıldı. Tüm hastalarda çıkan aort replasmanı yapıldı, bu hastaların 21'inde çıkan aort replasmanı hemiarka kadar uzatıldı. Beş hastada ise total arkus aort replasmanı yapıldı. Elli iki hastada modifiye Bentall işlemi gerçekleştirildi, 30 hastada ise suprakoronar greft implantasyonu uygulandı.

Bulgular: Klinik muayeneye göre aksiller arter kanülasyonu ile ilgili brakiyal pleksus hasarı, aksiller arter trombozu ve lokal yara enfeksiyonu gibi hiçbir komplikasyon meydana gelmedi. Ortalama KPB zamanı ve kros-klemp zamanı sırasıyla 190.8±62.0 dak ve 72.0±21.7 dak idi.

Sonuç: Ameliyat sonrası beş hasta öldü ve bir hastada yeni felç gelişti. Subklavian insizyon ve transpektoral yaklaşımla yapılan aksiller arter kanülasyonu ile uygulanan tam-akımlı KPB'nin kabul edilebilir mortalite ve morbiditeye sahip, kolay uygulanabilir ve güvenli bir yöntem olduğunu düşünüyoruz.

Anahtar sözcükler: Çıkan aort; arkus aort; sağ aksiller arter kanülasyonu.

Received: June 24, 2010 Accepted: December 12, 2010

Correspondence: Gökhan Özerdem, M.D. Sevgi Hastanesi, Sivas Cad. Sevgi Sok, No: 2, 38400 Melikgazi, Kayseri, Turkey.
Tel: +90 352 - 224 01 01 e-mail: ozerdemkvc@yahoo.com

For many years, the femoral artery has been the preferred arterial cannulation site for cardiopulmonary bypass (CPB) in surgery of the ascending aorta and aortic arch. However, femoral arterial perfusion causes retrograde flow which poses several drawbacks such as the retrograde embolization of luminal debris and aortic dissection. Both of these may lead to cerebral or visceral organ ischemia as well as ischemia in the lower limbs.^[1-3] To avoid these complications, the cannulation of the axillary artery has become increasingly widespread. Single right axillary artery cannulation provides advantages including antegrade whole body perfusion flow during CPB and unilateral antegrade cerebral perfusion in case of circulatory arrest. This occurs without additional cannulation of brachiocephalic arteries, and there is also no need to recannulate the graft before reestablishing CPB in aortic dissection cases.^[4-7]

Despite several advantages of right axillary artery cannulation in surgery of the ascending aorta and aortic arch, problems and complications of this technique are coming to the forefront with increased use.^[8,9] Among these are the choice of the cannulation site in the presence of pulselessness or attenuation of the pulse of the right upper limb, the possibility of left cerebral hemisphere hypoperfusion with unilateral perfusion, and axillary artery and brachial plexus injury. There is still some debate about which part of the axillary artery will be safe for cannulation. While some prefer a subclavicular approach, others prefer a transpectoral or subpectoral approach.^[4,6,7,10]

Here, we report our preliminary experiences using the transpectoral approach for axillary artery cannulation in aortic dissection or aortic arch pathologies.

PATIENTS AND METHODS

Between July 2004 and December 2010, right axillary artery cannulation was performed in 82 patients (38 males, 44 females; mean age 59.5±10.6 years; range 32 to

85 years) undergoing procedures on the ascending aorta or aortic arch at the Çağ Hospital in Ankara, Turkey. In all patients, the right axillary artery was cannulated via a transpectoral approach for arterial perfusion. Preoperative diagnosis revealed an aneurysm in the ascending aorta or aortic arch due to arteriosclerosis or degeneration in 46 patients (56.1%), acute type A aortic dissection in 28 (34.1%), and porcelain aorta in six patients (7.3%).

Twenty-eight of the operations were performed on an emergency basis and 54 as elective cases. All of the patients underwent replacement of the ascending aorta, and in 21 of those patients, the ascending aorta replacement was extended to the hemiarch. In addition, five patients underwent total arch replacement. Modified Bentall procedure was performed in 52 patients, and supracoronary graft implantation was performed in 30 patients. The concomitant procedure was coronary artery bypass grafting in 16 patients (19.5%). Operative characteristics are presented in table 1.

Surgical technique

The patient was placed in the standard supine position. For better exposure of the right axillary artery, the arm was positioned near the body with the hand down to the side and the elbow slightly flexed. The patient's upper body was elevated 20 degrees and tilted toward the left, so that the skin of the overlying infraclavicular fossa was nearly horizontal. Arterial pressure was routinely measured with a left artery cannula.

Before the median sternotomy, a 6 to 8 cm transverse skin incision was made approximately 1 cm below the middle and lateral part of the right clavicle (deltopectoral groove). Following the direction of its fibers, the pectoralis major muscle was separated, and the underlying pectoralis minor muscle was retracted laterally (Figure 1). The axillary artery was identified by palpation and then gently mobilized by sharp dissection without touching the medial and lateral brachial plexus

Table 1. Patients undergoing axillary artery cannulation for cardiopulmonary bypass

Patient	Diagnosis	Procedure	Selective cerebral perfusion	Open distal anastomosis
32	Ascending aorta aneurysm	Ascending aorta grafting	-	0
18	Acute type 1 dissection	Ascending aorta grafting	+	12
11	Ascending aorta aneurysm	Ascending aorta grafting + Hemiarch repair	+	11
10	Acute type 1 dissection	Ascending aorta grafting + Hemiarch repair	+	10
6	Porcelain aorta, aortic stenosis	Aortic valve replacement (Bentall)	+	6
5	Ascending aorta aneurysm and aortic arch aneurysm	Ascending aorta grafting + Arch replacement	+	5

cords posterior to the artery. The artery was then controlled with loops of silicone elastomer tape. After administration of heparin, an umbilical tape with a tourniquet was passed around the axillary artery, and the proximal and distal part of the exposed segment was clamped with vascular clamps. After performing a transverse incision, the axillary artery was cannulated directly with an 18 F, 20 F, or 22 F (DLP, Medtronic, Inc, Minneapolis, MN, USA) cannula which was advanced 3-4 cm into the artery while the proximal clamp was removed. The tourniquet was secured over the artery and the cannula (Figure 2). After arterial cannulation, a median sternotomy was performed, and a two-stage cannula was used in all patients for right atrial venous cannulation.

Cardiopulmonary bypass was established and an arterial flow of 2.8 L/min/m² was easily obtained at normothermia. After full flow was achieved without observable problems, cooling was started. The mid-ascending aorta was clamped and cold-blood cardioplegia was administered in antegrade and retrograde fashion for myocardial preservation. Proximal aortic reconstruction was then initiated. Once this was completed, the innominate and left common carotid arteries were exposed. When rectal temperature reached 24-26 °C, CPB flow was decreased to a volume flow of 10 mL/kg/min, and the innominate and left common carotid arteries were clamped so that unilateral antegrade cerebral perfusion was accomplished. The table was placed in the Trendelenburg position, and the aortic cross-clamp was removed. The arch was inspected from the inside. All arch reconstruction and distal anastomoses were performed with an open aortic anastomotic technique while low-flow perfusion through the right axillary artery was continued. When the distal repair was completed, the ascending aortic

graft was cross-clamped, and the innominate and left common carotid arterial clamps were removed, thereby starting systemic circulation. Flow through the axillary artery was gradually increased, and warming was started. Hot shot cardioplegia was administered prior to removing the aortic cross-clamp.

RESULTS

Mean CPB time and aortic cross-clamp times were 190.8±62.0 minutes and 72.0±21.7 minutes, respectively. The mean hypothermic circulatory arrest time was 35.3±8.9 minutes during antegrade selective cerebral perfusion. Five patients died postoperatively, and one patient experienced a new stroke in the postoperative period. Upon clinical examination, no complications related to axillary cannulation, such as brachial plexus injury, axillary artery thrombosis, or local wound infection, were observed. The average postoperative length of stay at the intensive care unit was five with a range between one and 28 days. Three patients died from multiple organ failure. One death occurred from acute aortic dissection, and another death occurred during reoperation for an ascending aortic aneurysm.

DISCUSSION

In complex procedures involving the aortic arch, axillary artery cannulation allows for clear advantages related to the antegrade flow and continuous perfusion of the right carotid artery during circulatory arrest.^[4] Axillary artery cannulation via the transpectoral approach with a subclavicular incision has therefore become a routine approach for complex procedures on the ascending aorta and/or aortic arch. Extensive aortic disease, such as aortic dissection with its complications, can make the choice of a cannulation site for CPB a perplexing one, and femoral cannulation may be necessary in

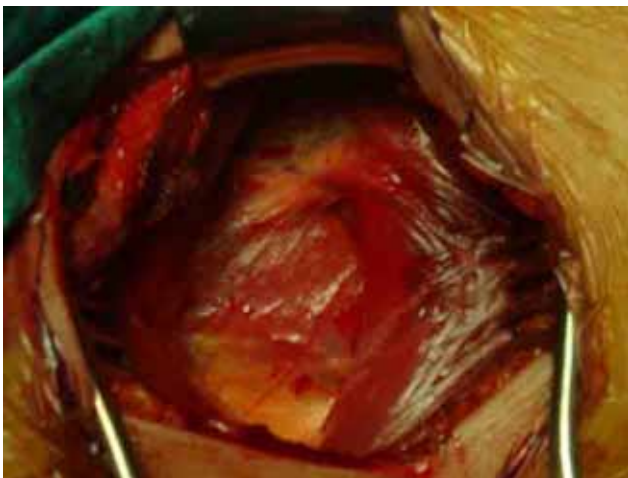


Figure 1. Transpectoral approach for axillary artery cannulation.

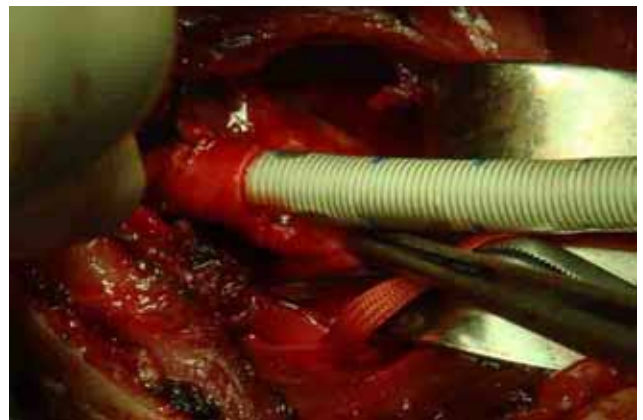


Figure 2. Cannulation of the axillary artery via transpectoral approach. An arterial cannula was inserted in axillary artery which was exposed at the level of the deltoideo-pectoralis groove.

certain cases.^[6] However, this approach carries the risk of atheroembolism due to retrograde aortic perfusion, or it may be undesirable because of severe iliofemoral disease.^[9,11] Our experience demonstrates that axillary artery cannulation was technically feasible in all our cases. It provided sufficient flow, and there were no intraoperative problems related to perfusion.

Possible reasons for changes in the axillary arterial cannulation site include an insufficient distance from the cannula to the innominate artery wall, stenosis of the vessel, small vessel diameter or arterial kinking after cannula introduction, and arterial wall damage after axillary artery cannulation.^[12,13] In this study, we did not experience any of these. We regard it as very important that forced cannulation is absolutely avoided. The main complications of axillary artery cannulation as described in the literature are brachial plexus injury and axillary artery thrombosis, none of which occurred in our series.^[8,14]

A known contraindication regarding the use of the axillary artery for cannulation is severe atherosclerotic disease of this artery leading to dissection of the cannulation site.^[15] However, these vessels are rarely involved in the atherosclerotic process.^[9] In all our successful cases, CPB flows of 2.8 mL/m² per minute were easily obtained.

In the presence of aortic dissection or iliofemoral disease, arterial perfusion through the right axillary artery is a safe and effective means of providing sufficient arterial inflow during CPB. However, in type A aortic dissection surgery, the choice of arterial inflow for CPB is influenced by many factors and depends on the surgeon's experience. Femoral arterial cannulation, a common method of cannulation for CPB, has some drawbacks. The complex anatomy of the false lumen may exclude peripheral vessels making femoral arteries unsuitable sites. Inappropriate perfusion of the false lumen during CPB may be catastrophic. It could lead to ischemia of the brain and spinal cord as well as aortic wall rupture. Thus far, we have not experienced any major vascular complications when using axillary artery perfusion.

In summary, we feel that full-flow CPB through axillary cannulation via the transpectoral approach with subclavicular incision is a feasible and safe method with acceptable morbidity and mortality.

Declaration of conflicting interests

The authors declared no conflicts of interest with respect to the authorship and/or publication of this article.

Funding

The authors received no financial support for the research and/or authorship of this article.

REFERENCES

1. Eugene J, Aronow WS, Stemmer EA. Retrograde aortic dissection during cardiopulmonary bypass. *Clin Cardiol* 1981;4:356-9.
2. Robicsek F, Guarino RL. Compression of the true lumen by retrograde perfusion during repair of aortic dissection. *J Cardiovasc Surg (Torino)* 1985;26:36-40.
3. Parr GV, Manley NJ, Williams DR, Montesano RM. Obstruction of the true lumen during retrograde perfusion of type I aortic dissections: a simplified solution. *Ann Thorac Surg* 1980;30:495-8.
4. Schachner T, Vertacnik K, Laufer G, Bonatti J. Axillary artery cannulation in surgery of the ascending aorta and the aortic arch. *Eur J Cardiothorac Surg* 2002;22:445-7.
5. Neri E, Massetti M, Capannini G, Carone E, Tucci E, Diciolla F, et al. Axillary artery cannulation in type a aortic dissection operations. *J Thorac Cardiovasc Surg* 1999;118:324-9.
6. Battaloglu B, Erdil N, Nisanoglu V. Axillary artery perfusion in acute type A aortic dissection repair. *J Card Surg* 2008;23:693-6.
7. Strauch JT, Spielvogel D, Lauten A, Lansman SL, McMurtry K, Bodian CA, et al. Axillary artery cannulation: routine use in ascending aorta and aortic arch replacement. *Ann Thorac Surg* 2004;78:103-8.
8. Sabik JF, Lytle BW, McCarthy PM, Cosgrove DM. Axillary artery: an alternative site of arterial cannulation for patients with extensive aortic and peripheral vascular disease. *J Thorac Cardiovasc Surg* 1995;109:885-90.
9. Kokotsakit J, Lazopoulos G, Milonakis M, Athanasiadis G, Romana K, Skouteli E, et al. Right axillary artery cannulation for surgical management of the hostile ascending aorta. *Tex Heart Inst J* 2005;32:189-93.
10. Zattera G, Totaro P, D'Armini AM, Vigano M. Deltoidopectoralis approach to axillary vessels for full-flow cardiopulmonary bypass. *Eur J Cardiothorac Surg* 2009; 35:913-4.
11. Sabik JF, Nemeh H, Lytle BW, Blackstone EH, Gillinov AM, Rajeswaran J, et al. Cannulation of the axillary artery with a side graft reduces morbidity. *Ann Thorac Surg* 2004;77:1315-20.
12. Schachner T, Nagiller J, Zimmer A, Laufer G, Bonatti J. Technical problems and complications of axillary artery cannulation. *Eur J Cardiothorac Surg* 2005;27:634-7.
13. Miyatake T, Matsui Y, Suto Y, Imamura M, Shiiya N, Murashita T, et al. A case of intraoperative acute aortic dissection caused by cannulation into an axillary artery. *J Cardiovasc Surg (Torino)* 2001;42:809-11.
14. Bichell DP, Balaguer JM, Aranki SF, Couper GS, Adams DH, Rizzo RJ, et al. Axilloaxillary cardiopulmonary bypass: a practical alternative to femorofemoral bypass. *Ann Thorac Surg* 1997;64:702-5.
15. Ergin MA, Griep EB, Lansman SL, Galla JD, Levy M, Griep RB. Hypothermic circulatory arrest and other methods of cerebral protection during operations on the thoracic aorta. *J Card Surg* 1994;9:525-37.