

## **Herniation of the stomach and colon into the right hemithorax following a transthoracic Collis-Belsey operation**

*Transtorasik Collis-Belsey ameliyatı sonrası sağ hemitoraksa mide ve kolon herniasyonu*

**Zeynep Bilgi, Aslı Gül Akgül, Hasan Fevzi Batirel**

Department of Thoracic Surgery, Medicine Faculty of Marmara University, İstanbul

Collis gastroplasty and Belsey fundoplication is a good choice for patients with a large hiatal hernia and associated reflux. In this article, we report a patient who presented as post-emetic with herniation of the stomach and colon into the right hemithorax, within two months after the Collis Belsey procedure. The patient was reoperated on, and the hernia was reduced through a left posterolateral thoracotomy. At the 22-month follow-up, the patient was well and was able to tolerate a full diet without any symptoms.

**Key words:** Collis-Belsey operation; gastroesophageal reflux; intrathoracic hernia.

Collis gastroplastisi ve Belsey fundoplikasyonu büyük hiatal hernisi ve eşlik eden reflüsü olan hastalarda iyi bir seçimdir. Bu yazıda, Collis-Belsey ameliyatını takip eden iki ay içinde, kusma sonrası sağ göğüs boşluğuna mide ve kolon herniasyonu olan bir hasta bildirildi. Hasta tekrar ameliyat edildi ve herni sol posterolateral torakotomi aracılığıyla redükte edildi. Yirmi iki aylık takipte, hastanın sağlık durumu iyidir ve tam bir diyeti tolere edebilecek durumdadır.

**Anahtar sözcükler:** Collis-Belsey ameliyatı; gastroözofageal reflü; intratorasik herni.

The Collis gastroplasty-Belsey fundoplication is the preferred surgical technique for patients with a large hiatal hernia and associated short esophagus. In recent years, it has been commonly performed laparoscopically rather than through the traditional left thoracotomy. Complications include hernia recurrence, usually occurring after a sudden rise in intra-abdominal pressure.<sup>[1]</sup>

### **CASE REPORT**

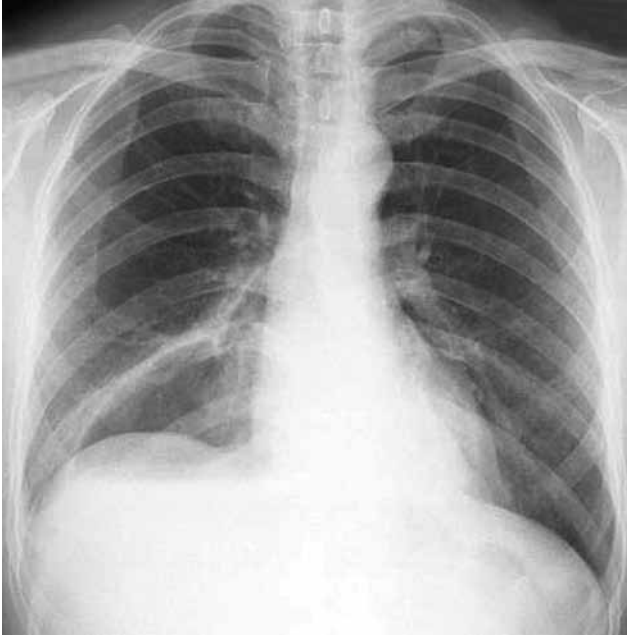
We report a 57-year-old man who underwent a transthoracic Collis gastroplasty-Belsey fundoplication due to a 6 cm hiatal hernia and associated short esophagus. He had suffered from severe reflux for 12 years. We performed a left posterolateral thoracotomy, preserving the serratus, and found severe pleural adhesions. We formed a 4 cm gastric tube to elongate the esophagus and reduced the herniated stomach into the abdomen. A 270 degree Belsey fundoplication was performed, and the diaphragmatic hiatus was closed with three no.1 silk sutures each about 1 cm apart. The patient was discharged on the fifth postoperative day without any complications and tolerated a soft diet.

Two months later, the patient presented with shortness of breath followed by nausea and forceful vomiting. He had eaten a heavy dinner of wheat rice and lamb meat followed by extra food at night. A nasogastric tube (NG) tube was inserted. The chest X-ray exhibited an air fluid level in the right chest (Figure 1). Upper gastrointestinal endoscopy showed a tight cardia, a large amount of retained gastric fluid, and a lack of passage through the pylorus. A computed tomography (CT) scan showed the migration of the stomach and colon to the right chest via the ruptured hiatal repair (Figure 2).

A reoperation was performed which included a full left posterolateral thoracotomy. There was severe fibrosis around the prior repair site, but the fundoplication sutures were intact. The hiatal sutures were ruptured posteriorly resulting in the herniation. Our observation was that the stomach had rolled over itself posteriorly and had become entirely herniated into the right hemithorax. This also pulled the splenic flexure of the colon and omentum (Figure 2). We reduced the herniated contents and performed a reinforced repair

*Received:* December 22, 2008 *Accepted:* June 6, 2009

Correspondence: Zeynep Bilgi, M.D. Marmara Üniversitesi Tıp Fakültesi, Göğüs Cerrahisi Anabilim Dalı, 34662 Koşuyolu, İstanbul, Turkey.  
Tel: +90 216 - 625 45 45 / 3010 e-mail: zeynep.bilgi@gmail.com

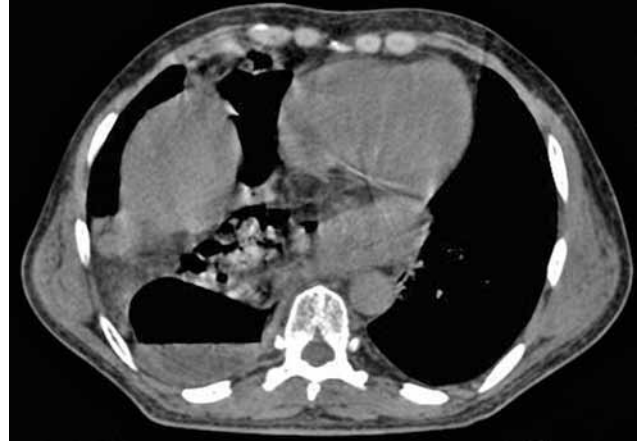

**Figure 1.** An air fluid level is noted in the right chest due to a dilated stomach.

of the diaphragmatic cruri using prolene mesh. The patient was discharged on the seventh postoperative day. Currently, he is asymptomatic at 15 months and tolerates a full diet without any reflux.

## DISCUSSION

Short esophagus may occur in association with hiatal hernia and a long history of gastroesophageal reflux disease. If present, short esophagus must be taken into account before performing a fundoplication operation as it may create excessive tension along suture lines with a standard anti-reflux procedure and increase the likelihood of recurrence.<sup>[2]</sup> Some authors report incidences as high as 80% in massive (>5 cm) paraesophageal hernia cases.<sup>[2,3]</sup> In this case, our patient also had a shortened esophagus due to a large (6 cm) hiatal hernia, so we felt the necessity to add a gastroplasty. There is no consensus on the technique of initial crural repair. Some authors state that mesh repair should be reserved for cases where primary crural repair is not possible, but others advocate a more liberal approach.<sup>[4,5]</sup> There are some reports which state that intraoperative measuring of the hiatal surface area may help in the patient selection process and decrease the incidence of recurrence.<sup>[6]</sup> The overall impression is that mesh closure can be performed with few complications which usually require no secondary surgical intervention, but there are situations resulting in the erosion of prosthetic material which necessitate esophagectomies and gastrectomies.<sup>[7]</sup> Further studies



**Figure 2.** The stomach, omentum, and colon is seen in the right chest.

are needed to determine who would benefit from mesh closure and which mesh material, shape, and repair technique should be used.

In addition to excessive suture line tension on the esophagus, hernia recurrence after hiatal repair is precipitated by sudden rises in intra-abdominal pressure.<sup>[1]</sup> In our case, the vomiting generated enough force to push the entire stomach and a part of the colon through the hiatus to the contralateral chest cavity. These recurrences are likely due to forceful vomiting in the early postoperative period and usually occur following motor vehicle accidents.<sup>[1,3]</sup> We routinely prescribe anti-emetic medications in the first two weeks and advise patients to avoid any excessive rise in intra-abdominal pressure resulting from such things as weight lifting (>5 kg), vomiting, or constipation during the first six months. Our patient did continue his medication but did not follow the dietary restrictions.

During our initial operation, our patient had severe adhesions on the left side resulting from his previous pneumonia attacks. This may have prevented the abdominal contents from herniating into the left chest. A left posterolateral thoracotomy always provides excellent exposure to the left chest and upper abdomen in those cases.<sup>[8]</sup>

The type and mechanism of hernia recurrence may vary largely among individual cases as it did with the patient in this study. Avoidance of sudden rises in intra-abdominal pressure is critical for preventing these complications.

## Declaration of conflicting interests

The authors declared no conflicts of interest with respect to the authorship and/or publication of this article.

## Funding

The authors received no financial support for the research and/or authorship of this article.

## REFERENCES

1. Durr ML, Yang SC. Traumatic right paraesophageal hernia after Belsey Mark IV fundoplication. *Ann Thorac Surg* 2008;85:321-2.
2. Maziak DE, Todd TR, Pearson FG. Massive hiatus hernia: evaluation and surgical management. *J Thorac Cardiovasc Surg* 1998;115:53-60.
3. Pearson FG, Cooper JD, Patterson GA, Ramirez J, Todd TR. Gastroplasty and fundoplication for complex reflux problems. Long-term results. *Ann Surg* 1987;206:473-81.
4. Granderath FA, Carlson MA, Champion JK, Szold A, Basso N, Pointner R, et al. Prosthetic closure of the esophageal hiatus in large hiatal hernia repair and laparoscopic antireflux surgery. *Surg Endosc* 2006;20:367-79.
5. Johnson JM, Carbonell AM, Carmody BJ, Jamal MK, Maher JW, Kellum JM, et al. Laparoscopic mesh hiatoplasty for paraesophageal hernias and funduplications: a critical analysis of the available literature. *Surg Endosc* 2006;20:362-6.
6. Granderath FA, Schweiger UM, Pointner R. Laparoscopic antireflux surgery: tailoring the hiatal closure to the size of hiatal surface area. *Surg Endosc* 2007;21:542-8.
7. Stadlhuber RJ, Sherif AE, Mittal SK, Fitzgibbons RJ Jr, Michael Brunt L, Hunter JG, et al. Mesh complications after prosthetic reinforcement of hiatal closure: a 28-case series. *Surg Endosc* 2009;23:1219-26.
8. Legare JF, Henteleff HJ, Casson AG. Results of Collis gastroplasty and selective fundoplication, using a left thoracoabdominal approach, for failed antireflux surgery. *Eur J Cardiothorac Surg* 2002;21:534-40.