

Type 2 popliteal artery entrapment syndrome: a case report

Tip 2 popliteal arter entrapment sendromu: Olgu sunumu

Erdal Aslım,¹ Hakkı Tankut Akay,¹ Oktay Korun,¹ Rahmi Can Akgün²

¹Department of Cardiovascular Surgery, Medical Faculty of Başkent University, Ankara, Turkey;

²Department of Orthopedics and Traumatology, Medical Faculty of Başkent University, Ankara, Turkey

In this article, we report a 39-year-old male case who was admitted with claudication and diagnosed with popliteal artery entrapment syndrome. The angiographic imaging demonstrated the deviation of the popliteal artery out of its natural tract. The diagnosis of popliteal artery entrapment syndrome was established by means of magnetic resonance imaging. The impingement of the popliteal artery was corrected surgically. The patient was asymptomatic during the follow-up period.

Key words: Claudication; entrapment syndrome; popliteal artery.

Lower extremity claudication is most commonly seen in the elderly and is mainly caused by atherosclerotic disease. It is uncommon in young, healthy adults, but the most frequent causes of atypical claudication are chronic compartment syndrome, medial tibial syndrome, and popliteal artery entrapment syndrome (PAES),^[1] in which the impingement of the popliteal artery, because of its relation to the medial head of the gastrocnemius muscle, causes lower extremity claudication. The prevalence of PAES was found to be 3.5% in a postmortem study.^[2] We hereby present a case of type 2 popliteal artery entrapment syndrome.

CASE REPORT

A 39-year-old male patient was admitted to our vascular surgery outpatient clinic with claudication after 500 meters walking and a feeling of coldness in the right lower extremity. The onset of his symptoms was two months prior to his admission, and the pain was restricted to the calf of the patient. He described no paresthesias or paralysis, and had no history of cigarette

Bu yazıda, klaudikasyon yakınması ile başvuran ve popliteal arter entrapment sendromu tanısı konan 39 yaşında bir erkek olgu sunuldu. Hastanın anjiyografik görüntülemesinde popliteal arterin doğal seyirinden sapma gösterdiği gözlemlendi. Popliteal arter entrapment sendromu tanısı, manyetik rezonans görüntüleme ile kondu. Popliteal arter sıkışması cerrahi olarak düzeltilti. Takip döneminde hasta asemptomatik idi.

Anahtar sözcükler: Klodikasyon; entrapment sendromu; popliteal arter.

smoking or family history of atherosclerotic disease. He also had no chronic diseases that could be deemed as a risk factor for atherosclerosis. A physical examination of the patient was unremarkable other than an absent popliteal artery and distal pulses in the right lower extremity. The patient was scheduled for aorto-iliac and femoro-popliteal angiography.

The angiography demonstrated a chronic occlusion on the distal superficial femoral artery caused by a long-segment thrombus formation that also involved the popliteal artery. The distal parts were recanalized with collaterals. A Cragg-McNamara infusion catheter was inserted, and thrombolytic therapy using urokinase was applied for 24 hours. On the control angiography, the segment with the thrombosis was still partially occluded (Figure 1), and it was also noted that the popliteal artery deviated medially out of its natural tract, which evoked suspicion of PAES. A 6x80 mm stent was implanted on the thrombus at the superficial femoral artery level, and balloon angioplasty was performed through the lumen of the stent.



Available online at
www.tgkdc.dergisi.org
doi: 10.5606/tgkdc.dergisi.2012.178
QR (Quick Response) Code

Received: January 31, 2010 Accepted: June 7, 2010

Correspondence: Oktay Korun, M.D. Başkent Üniversitesi Tıp Fakültesi, Kalp ve Damar Cerrahisi Anabilim Dalı, 06490 Bahçelievler, Ankara, Turkey.

Tel: +90 312 - 212 68 68 e-mail: oktay_korun@hotmail.com

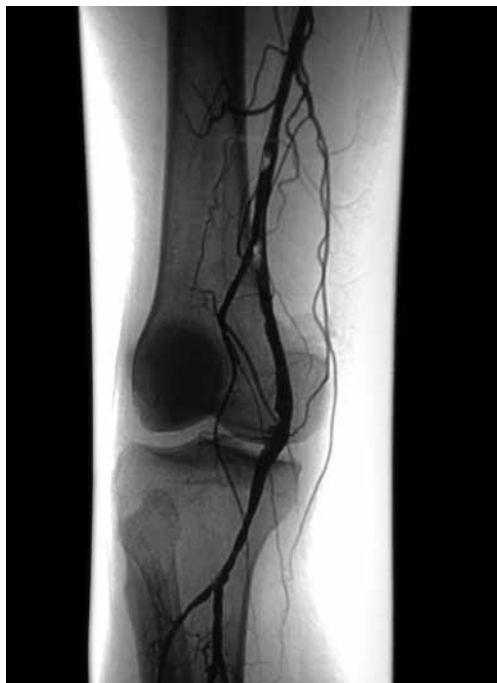

Figure 1. Preoperative angiographic image.

Ten days later at the outpatient clinical control, the patient reported a remarkable decline in his symptoms. Another physical examination revealed that the right popliteal artery and distal pulses were palpable but weaker compared with the contralateral extremity. A right popliteal magnetic resonance imaging (MRI) was

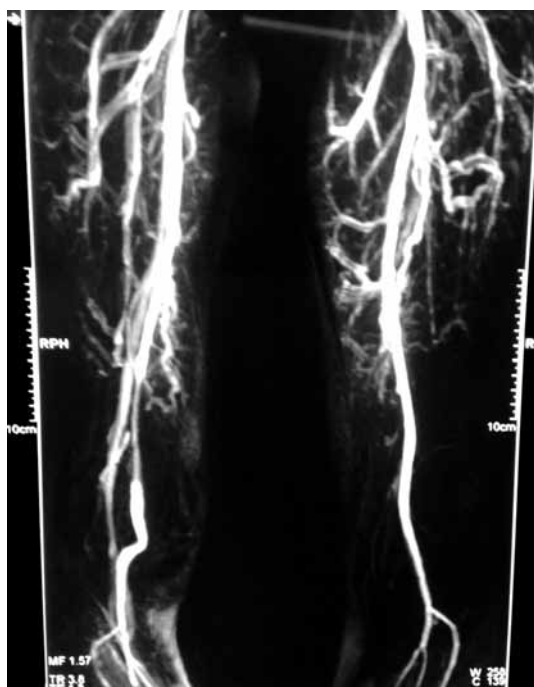


Figure 2. Preoperative magnetic resonance imaging.

performed to demonstrate the entrapment, and this showed the medial head of the gastrocnemius muscle passing between the popliteal artery and the vein, and it had attached itself to the medial condyle of the femur (Figure 2). Therefore, the diagnosis of PAES was confirmed.

The patient was admitted to the ward for popliteal fossa exploration. During the operation, the popliteal artery was dissected, and it was observed that it was impinged medially by a fibrous band on the medial part of the medial head of the gastrocnemius. In addition, the medial head of this muscle was originating from the intercondylar area of the femur. The operation was completed by the resection of the fibrous band which resolved the impingement.

The patient healed perfectly, and reported no symptoms during follow-up (Figure 3).

DISCUSSION

Popliteal artery entrapment syndrome is a rare cause of lower limb claudication. The impingement of the popliteal artery can be caused by various relationships between the popliteal artery and the gastrocnemius muscle and other structures in the popliteal fossa, and these can lead to a classification of the syndrome. The particular classification system used today was proposed by Insua et al.^[3] in 1970, and there are four main types. In type 1, the medial head of the gastrocnemius muscle is attached in its regular position (the medial condyle of the femur), but the popliteal artery follows an abnormal tract medially around the medial head of the muscle. In type 2, the popliteal artery, which normally follows its natural tract, is impinged by the

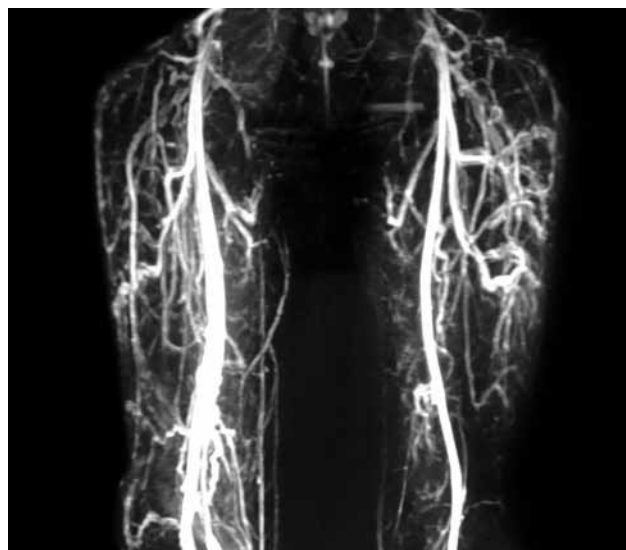


Figure 3. Postoperative magnetic resonance imaging.

aberrant medial head of the gastrocnemius muscle, which is originating from a position more lateral to its natural position. In type 3, both the artery and the muscle are in their natural anatomic positions, but aberrant slips of the muscle from the medial head of the gastrocnemius muscle entrap the artery. In type 4, the popliteal artery is entrapped by the fibrous bands originating from the popliteus muscle. Additionally, if there is any type of impingement which involves the popliteal vein, it is defined as type 5.^[4] There is also a variant of the PAES in which there are no anatomical anomalies, but the entrapment is caused by the hypertrophic gastrocnemius muscle heads. This is called the ‘functional entrapment syndrome’.^[5]

Because it is a rare cause of lower extremity claudication, diagnosis of PAES has a high rate of suspicion. The differential diagnosis involves the adventitial cystic disease of the popliteal artery, thromboangiitis obliterans, and compression of the superficial femoral artery at the level of the adductor canal. As in our case, young patients without any risk factors for atherosclerotic disease and without any known vasculitic disease who present with lower extremity claudication should be suspected of having PAES. The definitive diagnostic tool for this syndrome is an MRI.^[6]

Popliteal artery entrapment syndrome usually progresses along with vascular disease until final vessel occlusion with a subsequent ischemic limb event. Therefore, all anatomic entrapments of the popliteal artery should be repaired surgically independent of the symptoms it causes.^[7] In our case, the patient already had thrombotic stenosis of the superficial femoral artery which had been treated by stent implantation and angioplasty. Once the diagnosis was confirmed, we continued the management via surgical repair of

the entrapment although the patient had virtually no symptoms after the stent implantation.

The exploration of the popliteal fossa revealed the aberrant attachment of the medial head of the gastrocnemius muscle causing the impingement of the popliteal artery. The vein was in its natural position. Therefore, this case was a type 2 PAES. It is a rare cause of lower extremity claudication and should always be kept in mind when approaching a patient with claudication with no other obvious causes.

Declaration of conflicting interests

The authors declared no conflicts of interest with respect to the authorship and/or publication of this article.

Funding

The authors received no financial support for the research and/or authorship of this article.

REFERENCES

1. Turnipseed WD. Clinical review of patients treated for atypical claudication: a 28-year experience. *J Vasc Surg* 2004;40:79-85.
2. Gibson MH, Mills JG, Johnson GE, Downs AR. Popliteal entrapment syndrome. *Ann Surg* 1977;185:341-8.
3. Insua JA, Young JR, Humphries AW. Popliteal artery entrapment syndrome. *Arch Surg* 1970;101:771-5.
4. Rich NM, Collins GJ Jr, McDonald PT, Kozloff L, Clagett GP, Collins JT. Popliteal vascular entrapment. Its increasing interest. *Arch Surg* 1979;114:1377-84.
5. Rignault DP, Pailler JL, Lunel F. The “functional” popliteal entrapment syndrome. *Int Angiol* 1985;4:341-3.
6. McGuinness G, Durham JD, Rutherford RB, Thickman D, Kumpe DA. Popliteal artery entrapment: findings at MR imaging. *J Vasc Interv Radiol* 1991;2:241-5.
7. Fowl RJ, Kempczinski RF, Whelan TJ. Popliteal artery entrapment. In: Rutherford RB, editor. *Vascular surgery*. 4th ed. Philadelphia: W.B. Saunders; 1995. p. 889-94.