

Resection of synchronous ipsilateral giant bullae and bronchial carcinoid tumor

Senkron ipsilateral dev bül ve bronşiyal karsinoid tümörün rezeksiyonu

Adamu Issaka, Korkut Bostancı, Bedrettin Yıldızeli, Mustafa Yüksel, Hasan F. Batirel

Department of Thoracic Surgery, Medicine Faculty of Marmara University, İstanbul, Turkey

Synchronous bronchial carcinoid tumor and giant bullae are rare entities. In this article, we report a 62-year-old male presenting with dyspnea, cough and chest pain. No improvement was achieved with medical treatment. Examinations revealed right lower lobe endobronchial carcinoid tumor and upper lobe giant bullae. Simultaneous bullectomy and bronchotomy and carcinoid tumor resection through right thoracotomy, as well as postoperative tracheostomy were performed. The patient who had 2 lt/minute oxygen was discharged on the 16th postoperative day without any complication. Radiological, appearance, clinical situation and pulmonary functions were improved and better quality of life was observed at six months after surgery. Forced expiratory volume in 1 second (FEV₁) increased from 0.90 liter (29% predicted) to 1.13 liter (37% predicted). Patient continued to smoke and died due to cor pulmonale one year after discharge.

Key words: Bronchotomy; bullae; bullectomy; endobronchial carcinoid.

Bronchial carcinoid tumors are low-grade malignant neoplasms that arise from the neuroendocrine cells of the bronchus. The treatment approach depends on the size, location, and tissue type of the carcinoid tumors, and in most cases, the histological subtype determines the prognosis.^[1,2]

Bullae are defined as abnormally dilated airspaces within the lung parenchyma that measure 1 cm or more in diameter. Giant bullae are defined as bullae which occupy more than one-third of the hemithorax. Small bullae can increase to large sizes in the presence of an obstructive lesion that increases ventilation to the emphysematous parts of the lung. This is a common

Senkron bronşiyal karsinoid tümör ve dev bül, nadir bir durumdur. Bu yazıda, nefes darlığı, öksürük ve göğüs ağrısı ile seyreden 62 yaşında erkek olgu sunuldu. Tıbbi tedavi ile herhangi bir iyileşme sağlanamadı. Yapılan incelemelerde sağ akciğer alt lobda endobronşiyal karsinoid tümör ve sağ üst lobta dev bül tespit edildi. Sağ torakotomi ile eş zamanlı büllectomi ve bronkotomi ile karsinoid tümörün rezeksiyonunun yanı sıra ameliyat sonrası trakeostomi yapıldı. Hasta 2 litre/dakika oksijen ile ameliyat sonrası 16. günde komplikasyonsuz taburcu edildi. Ameliyat sonrası altıncı ayda radyolojik, görünüm, klinik durum ve pulmoner fonksiyonlar iyileşti ve daha iyi bir yaşam kalitesi gözlemlendi. Birinci saniyede zorlu ekspiratuvar volüm (FEV₁) 0.90 litreden (tahmini %29) 1.13 litreye (tahmini %37) yükseldi. Sigara içmeye devam eden hasta, taburcu edildikten bir yıl sonra kor pulmonale nedeniyle kaybedildi.

Anahtar sözcükler: Bronkotomi; bül; büllectomi; endobronşiyal karsinoid.

occurrence following single-sided lung volume reduction surgery or transplantation.^[3] A surgical bullectomy is indicated for patients who have dyspnea and compressive, space-occupying, non-functioning bullae.

We present this case of simultaneous bullectomy and bronchotomy with postoperative tracheostomy for synchronous bullae and endobronchial carcinoid tumor as it is a rare entity and first in literature.

CASE REPORT

A 62-year-old male heavy smoker with a past history of pulmonary hypertension (85 mmHg) and chronic obstructive pulmonary disease (COPD) was admitted to



Available online at
www.tgkdc.dergisi.org
doi: 10.5606/tgkdc.dergisi.2013.4818
QR (Quick Response) Code

Received: August 25, 2010 Accepted: February 13, 2011

Correspondence: Adamu Issaka, M.D. Marmara Üniversitesi Tıp Fakültesi Göğüs Cerrahisi Anabilim Dalı, 34899 Üst Kaynarca, Pendik, İstanbul, Turkey.

Tel: +90 216 - 657 06 06 / 3010 e-mail: aissaka@yahoo.com

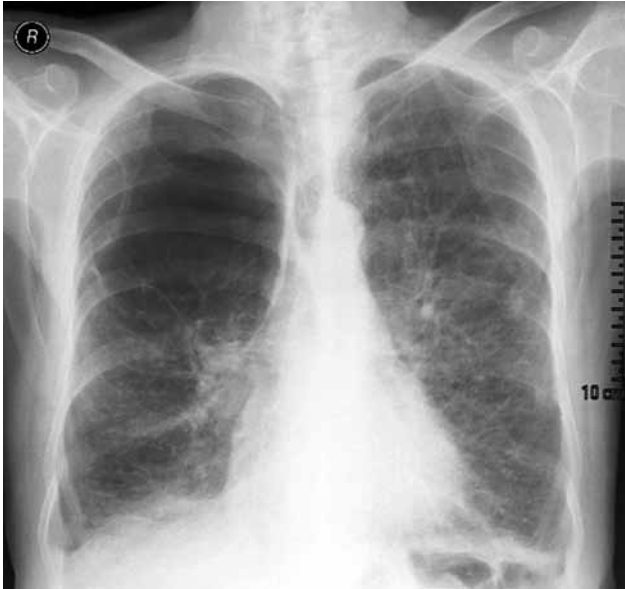


Figure 1. Preoperative chest X-ray revealing a giant bulla in the right hemithorax.

our clinic with chest pain, coughing, and dyspnea. He was dependent on oxygen (6 liter/minute). The patient had been on bronchodilators for many years with no improvement in his symptoms. A chest X-ray revealed a giant bulla in the right hemithorax (Figure 1). In addition, chest computed tomography (CT) revealed an enlarged subcarinal lymph node (LN), an underlying diffuse emphysematous lung, a giant bulla in the right upper lobe, an obstructing lesion in the right lower lobe bronchus with post-obstructive atelectasis, and consolidation (Figure 2). The patient was hypoxic in

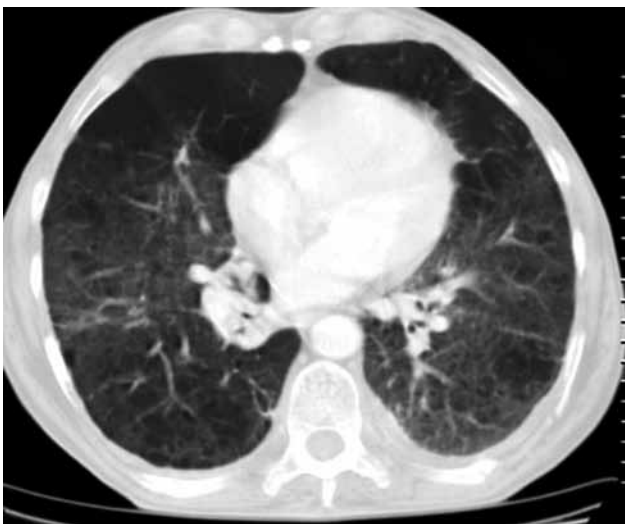

Figure 2. Chest computed tomography showing an obstructing lesion in the right lower lobe bronchus with post-obstructive atelectasis and part of the giant bulla in the right upper lobe.

room air with arterial blood gas pH of 7.41, carbon dioxide partial pressure (pCO₂) of 41.8 mmHg, and oxygen partial pressure (pO₂) of 55.9 mmHg, with desaturation (89%). A pulmonary function test (PFT) revealed severe airway obstruction [Forced expiratory volume in 1 second (FEV₁) of 0.90 liter (29%); forced vital capacity (FVC) of 1.84 liter (48%)]. A fiberoptic bronchoscopy (FOB) detected a polypoid tumoral mass which was almost completely occluding the right lower lobe bronchus lumen. A biopsy of the endobronchial lesion showed the pathological characteristics of a typical carcinoid tumor, and scintigraphy revealed that the right lung was receiving only 34% of the total lung perfusion. In addition, transthoracic echocardiography showed a normal left ventricular ejection fraction (LVEF), significant pulmonary hypertension (85 mmHg), and a hypokinetic left ventricular wall. Further investigations indicated no significant coronary artery disease (CAD), and a whole body skeletal scintigraphy scan and brain magnetic resonance imaging (MRI) showed no distant metastasis. An anesthetic assessment indicated a medium cardiopulmonary risk for the patient.

Prior to surgery, a mediastinoscopy was performed to stage the large subcarinal LN, and this showed no tumor metastasis. A right upper lobe bullectomy and a carcinoid tumor resection with a bronchotomy were performed via a right posterolateral thoracotomy. A frozen section analysis of the bronchial margins was also performed for clear margins. Additionally,

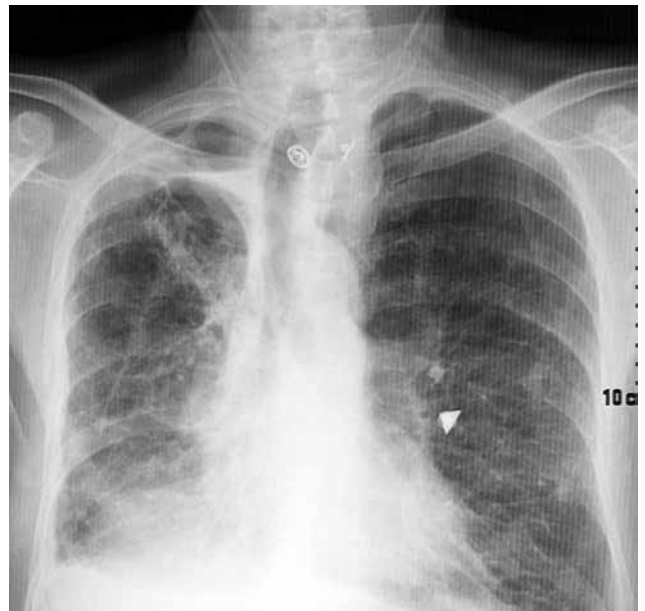


Figure 3. Postoperative chest X-ray showing small apical space and a well expanded right lung.

a simultaneous tracheostomy was performed to manage postoperative secretion. Two chest tubes were then inserted, and the patient was transferred to the intensive care unit (ICU). Postoperative complications (atelectasis, pneumonia, and prolonged air leak) requiring frequent toilet FOB, antibiotherapy, and temporary ventilatory support were noted. The patient was subsequently weaned from the ventilator and moved to the ward on the postoperative 10th day. He was discharged on the 16th postoperative day with a small apical space and a well-expanded right lung (Figure 3).

At the six-month follow-up, the patient had increased exercise tolerance, improved FEV₁ (1.13 liter, 37% predicted), decreased oxygen dependency (96% oxygen saturation at room air), and better quality of life. The patient died from chronic cor pulmonale a year later due to continuous cigarette smoking and noncompliance in medication.

DISCUSSION

Bronchial carcinoid tumors account for 1-2% of all lung tumors and 0.4% to 3% of all resected lung cancers. A patient with typical carcinoid tumors has an excellent long-term prognosis with a five-year survival rate ranging from 87-97%, whereas an atypical carcinoid tumor is characterized by increased mitotic activity and has a five-year survival rate ranging from 57 to 77%.^[1,2] Strictly endoluminal typical carcinoid tumors of the lung may be treated by bronchoscopic resection, and tumors not meeting the criteria for endobronchial resection can be treated surgically. Carcinoid tumors are slowly growing compared to other malignancies; hence, positron emission tomography (PET) imaging shows slow glucose uptake. Patients with LN involvement have a worse prognosis due to local or distant metastases; therefore, investigation for LN metastases is necessary.^[1,2] In our patient, a mediastinoscopy was performed for appropriate staging.

Surgical resection of giant bullae allows for the compressed functional lung to re-expand, permits better ventilation and perfusion, decreases both dead space and residual volume, and improves the chest mechanics by repositioning the diaphragm and chest wall. The presence of diffuse emphysema and severe impairment of lung function [stage 3 COPD classification of American Thoracic Society (ATS)] should not exclude consideration for surgery because in this subset of patients, even a small incremental breathing capacity may improve the patient's symptoms, exercise tolerance, and quality of life. A minimally invasive approach should be the first

option for the management of giant bullae. With the introduction of video-assisted thoracoscopic surgery (VATS), there has been an increase in interest in using this type of approach for many thoracic procedures, including a giant bullectomy, with satisfactory results.^[4] The early functional changes after surgery for bullous disease are qualitatively similar to those in the preliminary reports of lung volume reduction for non-bullous emphysema.^[5] Our patient, according to ATS criteria for COPD, was in stage 3 (FEV₁ <29%) with central typical carcinoid tumors. He had a synchronous bronchial carcinoid tumor and a giant bulla in the right lung, making it difficult to use either the VATS or bronchoscopic resection approach. However, in retrospect, the bronchial carcinoid tumor could have been treated via endobronchial resection since a pathological evaluation revealed no bronchial cartilage invasion.

In our patients, FEV₁ increased from 0.90 liter (29%) to 1.13 liter (37%) six months after surgery, and a postoperative tracheostomy was performed to ease bronchial toilet. The death of the patient one year later was non-surgically related.

Little has been reported in literature regarding synchronous ipsilateral bronchial carcinoid tumors and giant bullae treated with simultaneous parenchyma-sparing bullectomy and bronchotomy. These techniques, which can be performed on patients for whom medical treatment has been ineffective, feature improved clinical, radiological, and pulmonary functions.

Hence, we hope this case study provides valuable information that will lead to further studies related to this issue.

Declaration of conflicting interests

The authors declared no conflicts of interest with respect to the authorship and/or publication of this article.

Funding

The authors received no financial support for the research and/or authorship of this article.

REFERENCES

1. Rea F, Rizzardi G, Zuin A, Marulli G, Nicotra S, Bulf R, et al. Outcome and surgical strategy in bronchial carcinoid tumors: single institution experience with 252 patients. *Eur J Cardiothorac Surg* 2007;31:186-91.
2. Filosso PL, Rena O, Donati G, Casadio C, Ruffini E, Papalia E, et al. Bronchial carcinoid tumors: surgical management and long-term outcome. *J Thorac Cardiovasc Surg* 2002;123:303-9.

3. Rogers RM, DuBois AB, Blakemore WS. Effect of removal of bullae on airway conductance and conductance volume ratios. *J Clin Invest* 1968;47:2569-79.
4. De Giacomo T, Venuta F, Rendina EA, Della Rocca G, Ciccone AM, Ricci C, et al. Video-assisted thoracoscopic treatment of giant bullae associated with emphysema. *Eur J Cardiothorac Surg* 1999;15:753-6.
5. Snider GL. Reduction pneumoplasty for giant bullous emphysema. Implications for surgical treatment of nonbullous emphysema. *Chest* 1996;109:540-8.