

## Identification of the concentration of iodopovidone pleurodesis in rats for the maximal effectiveness

*Sıçanlarda maksimum etkinlik için iodopovidon plörodezis konsantrasyonunun belirlenmesi*

Rasih Yazkan,<sup>1</sup> Berkant Özpolat,<sup>2</sup> Levent Duman,<sup>3</sup> Sema Bircan,<sup>4</sup> Kemal Kürşat Bozkurt,<sup>4</sup> Sedat Güneş<sup>1</sup>

<sup>1</sup>Department of Thoracic Surgery, Süleyman Demirel University School of Medicine, Isparta, Turkey

<sup>2</sup>Department of Thoracic Surgery, Kırıkkale University School of Medicine, Kırıkkale, Turkey

<sup>3</sup>Department of Pediatric Surgery, Süleyman Demirel University School of Medicine, Isparta, Turkey

<sup>4</sup>Department of Pathology, Süleyman Demirel University School of Medicine, Isparta, Turkey

**Background:** This study aims to investigate the efficacy and safety of different doses of iodopovidone for pleurodesis and to evaluate the histopathological changes in thyroid tissue.

**Methods:** Thirty-eight male Albino Wistar rats (260-320 g, 6-8 months old) included in this experimental study were randomly divided into four groups. Groups 1, 2, and 3 were given 2 mL/kg intrapleural iodopovidone at concentrations of 1%, 2%, 4%, respectively, while group 4 was administered intrapleural saline. The surfaces were graded by macroscopic and microscopic examination on Day 30 and thyroid tissues were histopathologically examined.

**Results:** Iodopovidone at concentrations of 2% and 4% resulted in significantly more adhesions and inflammatory response. Four percent iodopovidone produced non-significant microscopic changes in the contralateral visceral pleural surface. No vacuolization in thyroid tissue showing hyperthyroidism was observed in the groups.

**Conclusion:** We suggest that 2% iodopovidone is enough for an effective and safe pleurodesis and the concentration of iodopovidone may be raised to 4% in unsuccessful cases. However, as the study was conducted on rats, it still remains to be elucidated that the similar results can be achieved in human studies.

**Key words:** Iodine; iodopovidone; pleurodesis; thyroid.

**Amaç:** Bu çalışmada, plörodez amacı ile kullanılan iodopovidonun farklı dozlarının etkinliği ve güvenilirliği araştırıldı ve tiroid dokusundaki histopatolojik değişiklikler değerlendirildi.

**Çalışma planı:** Bu deneysel çalışmaya alınan 38 Albino Wistar erkek sıçan (260-320 g, 6-8 aylık) rastgele dört gruba ayrıldı. Grup 1, 2 ve 3'e sırasıyla plevra içine %1, %2 ve %4'lük konsantrasyonlarda 2 mL/kg iodopovidon, grup 4'e plevra içine serum fizyolojik verildi. Plevral yüzeyler 30. günde makroskopik ve mikroskopik inceleme ile derecelendirildi ve tiroid dokuları histopatolojik olarak incelendi.

**Bulgular:** İodopovidon %2 ve %4'lük konsantrasyonlarda daha belirgin yapışma ve enflamatuvar yanıtı neden oldu. Yüzde dördlük iodopovidon kontralateral visceral plevra yüzeyinde anlamlı olmayan mikroskopik değişikliklere neden oldu. Hiçbir grupta tiroid dokusunda hipertiroidizm bulgusu olan vakuolizasyon izlenmedi.

**Sonuç:** Etkili ve güvenli bir plörodez için %2'lik iodopovidonun yeterli olacağını ve başarı sağlanamayan olgularda iodopovidon konsantrasyonunun %4'e yükseltilebileceğini önermekteyiz. Ancak deney sıçanlar üzerinde çalışılmış olduğundan, insan çalışmalarında da benzer sonuçların alınabileceği kesinlik kazanmamıştır.

**Anahtar sözcükler:** İyot; iodopovidon; plörodezis; tiroid.



Pleurodesis is used to achieve a symphysis between layers of the pleura to prevent accumulation of fluid in patients with recurrent pleural effusion for malignant or benign events, such as cardiac failure, cirrhosis, nephritic syndrome, and chylothorax.<sup>[1-3]</sup> Several pleurodesis agents have been used with a success rate ranging from 60 to 94%,<sup>[4]</sup> but there is still no consensus opinion regarding the best agent.<sup>[5]</sup> Currently, the three primary agents used for chemical pleurodesis are talc, bleomycin, and tetracycline derivatives.<sup>[6]</sup> However, these are not readily available in some countries and are expensive.

An alternative sclerosant agent is iodopovidone,<sup>[6]</sup> a topical antiseptic that has been shown to be safe and effective in several studies.<sup>[1]</sup> In the literature, clinical and experimental studies of 2% and 4% iodopovidone have been reported.<sup>[6-12]</sup> We have also been using 2% iodopovidone pleurodesis clinically in the management of recurrent pleural effusions with success for one year. The knowledge that iodopovidone has systemic absorption directed us to search for the most appropriate concentration of this agent that could be used for safely and effectively for pleurodesis while also determining whether there would be any side effects on the thyroid gland. To accomplish this, we conducted a prospective, randomized, observer-blinded, controlled study involving rats.

## MATERIALS AND METHODS

Thirty-eight male albino Wistar rats (260-320 g, 6-8 months old) were assigned to the study. All of the animals were cared for in compliance with the European Convention on Animal Care, and the study protocol was approved by the Animal Ethics Committee of Süleyman Demirel University (Protocol no: 18/01). The rats were housed in the animal laboratory, and the operations were performed there. They were divided into four groups in which groups 1, 2, and 3 were the study groups with 10 animals in each, and group 4 was the control group with eight animals. Groups 1, 2, and 3 were given 2 mL/kg iodopovidone, and a 10% solution of iodopovidone was diluted with normal saline to final concentrations of 1%, 2%, and 4%, respectively. Group 4 was given only 2 mL/kg saline intrapleurally. The weights of rats were monitored weekly.

### Surgery

A 5 mm right thoracotomy skin incision was made over the fifth intercostal space under general anesthesia (intraperitoneal xylazine 5 mg/kg and ketamine 50 mg/kg) in sterile conditions. The pleural cavity was entered via a 22-gauge polytetrafluoroethylene (PTFE)

catheter attached to a syringe, and the withdrawn iodopovidone was then given to the animal. The presence of air in the pleural space was controlled, and if any appeared, it was evacuated using a three-way stopcock. Next, the catheter was removed, and the rats were rotated to assure that the iodopovidone was distributed throughout the entire pleural surface. Meanwhile, the control group received only saline using the same method. The skin incision was then closed, and the movements of the rats were observed during the wake-up period. Two early deaths due to a pneumothorax in group 2 were revealed via autopsy. However, no late mortalities were observed during the 30-day follow-up period.

### Necropsy

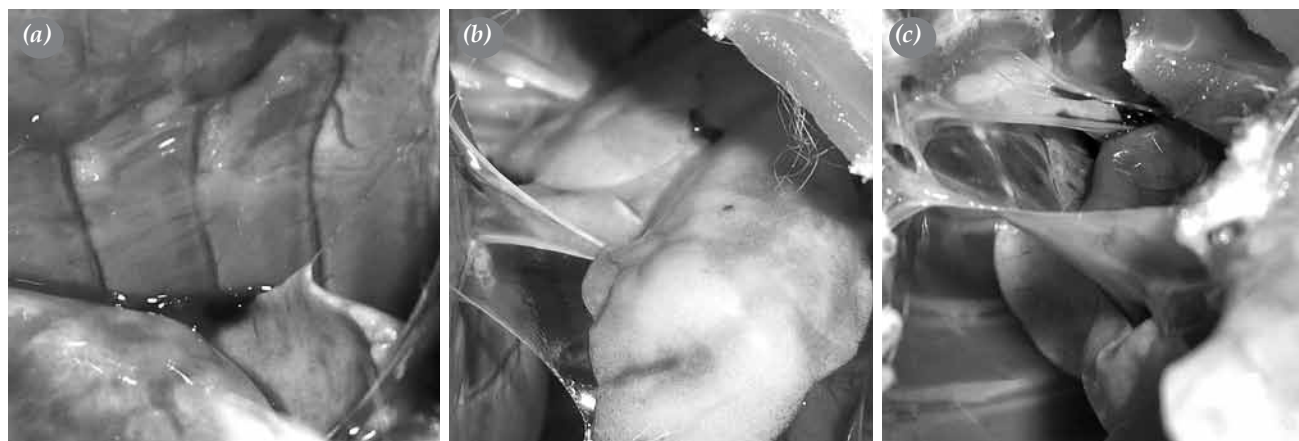
The animals were sacrificed under general anesthesia on day 30. The ribs were cut along the sternum to allow for full access and visualization of the pleural surfaces. Macroscopic scoring of pleurodesis was done by a surgeon who was blinded to the groups, and the procedure was carried out according to the method described by Hurewitz et al.<sup>[13]</sup> The scoring was as follows: grade 0, normal pleura; grade 1, a few scattered adhesions; grade 2, generalized scattered adhesions; and grade 3, complete obliteration of the pleural space by adhesions. The thyroid tissue, contralateral chest wall, lungs, and pleura were also sacrificed, and the specimens were fixed in formalin.

### Microscopy

The sections of the chest wall along with both lungs and the mediastinal structures were extracted at the anteroposterior plane in the mid-lung zone. The samples were stained with hematoxylin and eosin (H-E) for the microscopic evaluation of pleural and alveolar inflammation and fibrosis and then were scored. The analysis was done by a pathologist who was blinded to the groups. The degree of inflammation and fibrosis was scored as follows: grade 0, absence of inflammation and fibrosis; grade 1, mild inflammation and fibrosis; grade 2, moderate inflammation and fibrosis; and grade 3, severe inflammation and fibrosis. The thyroid tissue, contralateral chest wall, lungs, and pleura were also examined.

### Statistical analysis

Statistical analyses were performed using the SPSS version 11.5 for Windows software program (SPSS Inc., Chicago, IL, USA). The median (minimum-maximum) was given in terms of descriptive statistics, and the Kruskal-Wallis one-way analysis of variance (ANOVA) was used to compare the four groups. When



**Figure 1.** Photographs of the rat thorax instilled with iodopovidone after the animals were sacrificed: (a) 1%, (b) 2%, and (c) 4%.

differences occurred, we used the Mann-Whitney U test with Bonferroni correction to determine the difference between the groups, and the Wilcoxon test was utilized for intragroup comparisons. A *p* value of <0.05 was considered to be statistically significant.

**RESULTS**

**Macroscopy**

Adhesions were graded as the chest cavity of the rats was opened (Figure 1). Group 1 received a score of 0 (0-1), group 2 had a score of 1 (0-2), and group 3 received a score of 2 (0-3). No adhesions were seen in the control group. The differences between group 2 and groups 1 (*p*=0.006) and 4 (*p*=0.003) were statistically significant. In addition, there were statistically significant differences between group 3 and groups 1 (*p*=0.001) and 4 (*p*=0.001); however, the differences between group 3 and group 2 (*p*=0.067) were not statistically significant. Furthermore, no adhesions were seen in the contralateral pleural surfaces of any group. The macroscopic scores of pleurodesis and the contralateral side are shown in Table 1, and the

comparative *p* values between each group are shown in Table 2.

**Microscopy**

The scores of the microscopic exam with the H-E-stained lung and pleural surfaces of all of the rats are shown in Table 1. The degree of the inflammatory response and fibrosis was also evaluated (Figure 2). All study groups demonstrated an inflammatory response at the site of injection compared with the contralateral pleura. The microscopic score for group 1 was 0.5 (0-1) while for group 2, the score was 1 (0-2) and for group 3, it was 2 (0-3). The microscopic score for the control group was 0 (0-0). According to the Mann-Whitney U test with Bonferroni correction, the differences between group 1 and groups 2 (*p*=0.070), 3 (*p*=0.029), and 4 (*p*=0.022) were not statistically significant. However, the differences between group 2 and group 4 (*p*=0.001) and group 3 and group 4 (*p*=0.004) were statistically significant, but the differences between group 3 and group 2 (*p*=0.164) and group 3 and group 4 (*p*=0.010) was not statistically significant on the contralateral side. In addition, no vacuolization was

**Table 1. Descriptive statistics and a comparison of the results between the four groups**

Side	Group 1 (n=10)		Group 2 (n=8)*		Group 3 (n=10)		Group 4 (n=8)		<i>p</i>
	Median	Min.-max.	Median	Min.-max.	Median	Min.-max.	Median	Min.-max.	
<b>Macroscopic</b>									
Pleurodesis (+)	0	0-1	1	0-2	2	0-3	0	0-0	0.001
Pleurodesis (-)	0	0-0	0	0-0	0	0-0	0	0-0	-
<b>Microscopic</b>									
Pleurodesis (+)	0.5	0-1	1	0-2	2	0-3	0	0-0	0.002
Pleurodesis (-)	0	0-1	0	0-1	1	0-2	0	0-0	0.029
Thyroid tissue	0	0-0	0	0-0	0	0-0	0	0-0	-

Min.: Minimum; Max.: Maximum; ANOVA: Analysis of variance; \* Kruskal-Wallis one-way ANOVA; Macroscopic scoring: 0= Normal pleura; 1= A few scattered pleura; 2= Generalized scattered pleura; 3= Complete obliteration; Microscopic scoring: 0= Absence of inflammation and fibrosis; 1= Mild inflammation and fibrosis; 2= Moderate inflammation and fibrosis; 3= Severe inflammation and fibrosis.

**Table 2. Intergroup comparisons of the *p* values of each group\***

Side	Group 1 vs. group 2	Group 1 vs. group 3	Group 1 vs. group 4	Group 2 vs. group 3	Group 2 vs. group 4	Group 3 vs. group 4
	<i>p</i>	<i>p</i>	<i>p</i>	<i>p</i>	<i>p</i>	<i>p</i>
<b>Macroscopic</b>						
Pleurodesis (+)	0.006	0.001	0.371	0.067	0.003	0.001
Pleurodesis (-)	-	-	-	-	-	-
<b>Microscopic</b>						
Pleurodesis (+)	0.070	0.029	0.022	0.164	0.001	0.004
Pleurodesis (-)	0.805	0.056	0.192	0.110	0.143	0.010
Thyroid tissue	-	-	-	-	-	-

\* Mann-Whitney U test with Bonferroni correction.

seen in the thyroid tissue of any of the groups. The microscopic scores of pleurodesis and the contralateral side are shown in Table 1, and comparative *p* values between the groups are shown in Table 2.

## DISCUSSION

Pleural effusion in patients with advanced cancer is a common problem which causes significant morbidity. In addition, it can negatively affect the patients' quality of life for remaining months of their life.<sup>[14]</sup> Up to 25% of the patients with lung cancer and 50% of the patients with breast cancer develop pleural effusions,<sup>[15]</sup> and the majority will need a procedure to remove the fluid and prevent recurrence.<sup>[15]</sup>

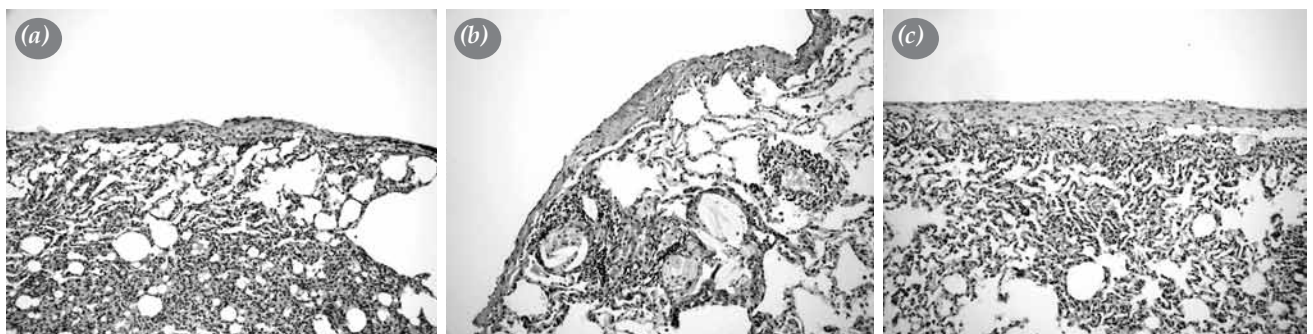
Pleurodesis is a well-accepted therapy for patients with recurrent pleural effusions.<sup>[5,11]</sup> It was first reported at the beginning of the 20<sup>th</sup> century, and a wide variety of agents have been used for this procedure,<sup>[9]</sup> including silver nitrate, quinacrine, tetracycline, doxycycline, talc and bleomycin.<sup>[5,16,17]</sup> Among these, talc is reported to be the most effective chemical agent for malignant pleural effusions, with a complete success rate of 93% compared with bleomycin (54%) and tetracycline (67%).<sup>[11]</sup> Unfortunately, all these

agents are expensive and are not readily available in some countries.

Iodopovidone is a cheap alternative that is a readily available sclerosing agent for chemical pleurodesis.<sup>[6,11]</sup> It is an iodine-based topical antiseptic and has been shown to be safe and effective in several studies.<sup>[11]</sup>

Experimental studies involving iodopovidone pleurodesis are limited. In a single rabbit model study, 4% iodopovidone was shown to be effective for producing pleurodesis, but the side effects associated with this drug have not been investigated.<sup>[6]</sup> Therefore, we decided to investigate different concentrations of iodopovidone to ensure the safety and efficacy of this procedure.

Our results verify the efficacy of iodopovidone pleurodesis. Both 2% and 4% iodopovidone administered intrapleurally induced an effective pleurodesis within 30 days. In all of our groups, iodopovidone produced no macroscopic changes in the contralateral chest wall, lungs, or pleura. At a concentration of 4%, it did produce microscopic changes in the contralateral visceral pleural surface, but these were not statistically significant. We suggest that these microscopic changes might have been due



**Figure 2.** Microscopic sections of the visceral pleura exposed to iodopovidone showed (a) mild inflammation and fibrosis with 1% concentration, (b) moderate inflammation and fibrosis with 2%, and (c) dense inflammation and fibrosis with 4%, (H-E x 200).

to the systemic absorption of iodopovidone since a similar process had previously been seen with talc pleurodesis.<sup>[2]</sup>

The exact mechanism of iodopovidone pleural irritation associated with pleurodesis is unknown. It has been theorized that this could be related to the low pH of the iodopovidone solution (pH=2.97).<sup>[12]</sup> Experimental studies on animals have demonstrated that the intrapleural administration works as an inflammatory agent by first creating an acute pleural injury. This is then followed by inflammation and fibrosis, as evidenced by the high protein and lactate dehydrogenase levels along with the total white cell count.<sup>[6,15]</sup> Furthermore, iodine has strong oxidative and cytotoxic properties which may include a potent inflammatory response, thus leading to pleural symphysis.<sup>[1,12]</sup> In our ongoing study, we are continuing to explore systemic cascade activation using serum markers, interleukins and C-reactive protein (CRP), and we hope that our future results might play a role in revealing the mechanism for pleurodesis.

Currently, we are successfully using 2% iodopovidone in recurrent pleural effusions in clinical settings. In the literature, successful responses of up to 91.6% have been reported with this concentration;<sup>[18]</sup> however, the success rate can be as low as 64.2%.<sup>[19]</sup> This is probably due to the dilution of iodopovidone at residual effusion and the fact that higher concentrations may be necessary for a second pleurodesis. Iodopovidone, which is extensively absorbed from pleural surfaces, may lead to a 10<sup>4</sup> fold increase in serum iodine concentrations compared to normal values and may be absorbed by the thyroid gland. Yeginsu et al.<sup>[7]</sup> reported that the intrapleural administration of 100 mL of 2% iodopovidone did not affect thyroid hormone levels in adult patients. However, to our knowledge, no studies have been conducted on higher concentrations. Microscopic vacuolization in the colloid is a reliable finding of hyperthyroidism in the thyroid tissue,<sup>[20]</sup> and in our study, we did not detect a significant change in this tissue at concentrations of 2% or 4%.

In conclusion, our study showed that iodopovidone, a cheap, readily available agent, is a safe and effective alternative for pleurodesis. No histopathological changes in thyroid tissue were observed at concentrations of 2% and 4%. Therefore, we strongly suggest the use of 2% in clinical settings. If that proves to be unsuccessful, then the concentration of iodopovidone can be raised to 4%. However, since our study was conducted on rats, there is no guarantee

that the same results will carry over to the human population.

#### Declaration of conflicting interests

The authors declared no conflicts of interest with respect to the authorship and/or publication of this article.

#### Funding

The authors received no financial support for the research and/or authorship of this article.

#### REFERENCES

1. Agarwal R, Aggarwal AN, Gupta D, Jindal SK. Efficacy and safety of iodopovidone in chemical pleurodesis: a meta-analysis of observational studies. *Respir Med* 2006;100:2043-7.
2. Gözübüyük A, Ozpolat B, Çiçek AF, Caylak H, Yücel O, Kavaklı K, et al. Comparison of side effects of oxytetracycline and talc pleurodesis: an experimental study. *J Cardiothorac Surg* 2010;5:128. doi: 10.1186/1749-8090-5-128.
3. Marchi E, Vargas FS, Acencio MM, Antonangelo L, Teixeira LR, Genofre EH, et al. Talc and silver nitrate induce systemic inflammatory effects during the acute phase of experimental pleurodesis in rabbits. *Chest* 2004;125:2268-77.
4. Ozpolat B, Gazyagci S, Gözübüyük A, Ayva S, Atinkaya C. Autologous blood pleurodesis in rats to elucidate the amounts of blood required for reliable and reproducible results. *J Surg Res* 2010;161:228-32. doi: 10.1016/j.jss.2009.01.027.
5. Dikensoy O, Light RW. Alternative widely available, inexpensive agents for pleurodesis. *Curr Opin Pulm Med* 2005;11:340-4.
6. Guo Y, Tang K, Bilaceroglu S, Kalomenidis I, Salleng KJ, Lane KB, et al. Iodopovidone is as effective as doxycycline in producing pleurodesis in rabbits. *Respirology* 2010;15:119-25. doi: 10.1111/j.1440-1843.2009.01671.x.
7. Yeginsu A, Karamustafaoglu A, Ozugurlu F, Etikan I. Iodopovidone pleurodesis does not effect thyroid function in normal adults. *Interact Cardiovasc Thorac Surg* 2007;6:563-4.
8. Olivares-Torres CA, Laniado-Laborín R, Chávez-García C, León-Gastelum C, Reyes-Escamilla A, Light RW. Iodopovidone pleurodesis for recurrent pleural effusions. *Chest* 2002;122:581-3.
9. Dey A, Bhuniya S, Datta Chaudhuri A, Pandit S, Saha-Dutta Chowdhury M, Sengupta A, et al. Iodopovidone pleurodesis: experience of a tertiary hospital in Kolkata. *Singapore Med J* 2010;51:163-5.
10. Caglayan B, Torun E, Turan D, Fidan A, Gemicci C, Sarac G, et al. Efficacy of iodopovidone pleurodesis and comparison of small-bore catheter versus large-bore chest tube. *Ann Surg Oncol* 2008;15:2594-9. doi: 10.1245/s10434-008-0004-1.
11. Agarwal R, Aggarwal AN, Gupta D. Efficacy and safety of iodopovidone pleurodesis through tube thoracostomy. *Respirology* 2006;11:105-8.
12. Neto JD, de Oliveira SF, Vianna SP, Terra RM. Efficacy and safety of iodopovidone pleurodesis in malignant pleural

- effusions. *Respirology* 2010;15:115-8. doi: 10.1111/j.1440-1843.2009.01663.x.
13. Hurewitz AN, Lidonici K, Wu CL, Reim D, Zucker S. Histologic changes of doxycycline pleurodesis in rabbits. Effect of concentration and pH. *Chest* 1994;106:1241-5.
  14. Yildirim E, Dural K, Yazkan R, Zengin N, Yildirim D, Gunal N, et al. Rapid pleurodesis in symptomatic malignant pleural effusion. *Eur J Cardiothorac Surg* 2005;27:19-22.
  15. Astoul P. Pleurodesis for recurrent malignant pleural effusions: the quest for the Holy Grail. *Eur J Cardiothorac Surg* 2011;40:277-9. doi: 10.1016/j.ejcts.2010.11.035.
  16. Brock RC. The use of silver nitrate in the production of aseptic obliterative pleuritis. *Guys Hosp Rep* 1942;91:99-103.
  17. Taylor SA, Hooton NS, Macarthur AM. Quinacrine in the management of malignant pleural effusion. *Br J Surg* 1977;64:52-3.
  18. Morales-Gomez J, Tellez-Becerra JL, Martinez-Ormeno JE. Pleurodesis con yodopovidona en el derrame pleural neoplasico. *Rev Inst Nal Enf Resp Mex* 1993;6:71-4.
  19. Kelly-Garcia J, Roman-Berumen JF, Ibarra-Perez C. Iodopovidone and bleomycin pleurodesis for effusions due to malignant epithelial neoplasms. *Arch Med Res* 1997;28:583-5.
  20. Rosai J, Tallini G. Thyroid gland. In: Rosai J, editor. *Rosai and Ackerman's surgical pathology*. New York: Elsevier; 2011. p. 487-564.