

Successful treatment of pulmonary angiosarcoma along with pulmonary endarterectomy and pulmonary valve replacement

Pulmoner anjiyosarkomun pulmoner endarterektomi ve pulmoner kapak replasmanı ile birlikte başarılı tedavisi

Mehmed Yanartaş, Ramesh S Kuffy, Rober E Nadler, David P Jenkins

Department of Cardiothoracic Surgery, Papworth Hospital, Cambridge, UK

Pulmonary endarterectomy (PEA) is an effective treatment of choice for patients with chronic thromboembolic pulmonary hypertension (CTEPH). Symptoms of pulmonary angiosarcoma (PS) can mimic CTEPH, showing similar radiological findings. In this article, we report on a 69-year-old male case with progressive dyspnea and angina. Clinical and radiographic examination revealed pulmonary hypertension with a mass extending to the pulmonary valve, indicating potential PS in the differential diagnosis. A pulmonary valve replacement was performed concurrently with PEA surgery. Histological examination confirmed the diagnosis of PS. The patient was referred into a local oncology service for adjuvant chemotherapy.

Key words: Angiosarcoma; pulmonary endarterectomy; pulmonary hypertension.

Primary sarcomas of the pulmonary artery are rare, with only approximately 120 cases having been reported since it was first described in 1923 by Mandelstamm.^[1] The *in vivo* rate of growth of the tumor is unknown, but it can be rapid, with patients dying from right heart failure or metastases.^[2]

CASE REPORT

A 69-year-old male patient presented with breathlessness, pleuritic chest pain, and palpitations over an 18-month period. He was examined initially via coronary angiography at another center and was treated with a left anterior descending artery (LADA) stent. Echocardiography at our facility revealed a

Pulmoner endarterektomi (PEA), kronik tromboembolik pulmoner hipertansiyon (KTEPH) hastalarında etkili bir tedavi seçeneğidir. Pulmoner anjiyosarkomun (PS) semptomları, benzer radyolojik bulgular göstererek KTEPH'yi taklit edebilir. Bu yazıda, ilerleyici nefes darlığı ve anjinası olan 69 yaşında erkek bir olgu sunuldu. Klinik ve radyolojik muayenede pulmoner kapağa uzanan ve ayırıcı tanıda PS olabileceğini gösteren bir kitle ile birlikte, pulmoner hipertansiyon tespit edildi. Pulmoner endarterektomi cerrahisi ile eş zamanlı pulmoner kapak replasmanı yapıldı. Histolojik incelemede, PS tanısı doğrulandı. Hasta adjuvan kemoterapi için yerel bir onkoloji kliniğine yönlendirildi.

Anahtar sözcükler: Anjiyosarkoma; pulmoner endarterektomi; pulmoner hipertansiyon.

dilated, hypertrophied right ventricle (RV) with a systolic pulmonary artery (PA) pressure of greater than 60 mmHg. Further investigation demonstrated femoral vein thrombosis, and an inferior vena caval filter was inserted. Magnetic resonance (MR) angiography of the PAs showed extensive obstruction of the proximal PA, and computed tomography (CT) (Figure 1) revealed mild dilatation of the main PA (range 3-4 cm) together with marked dilatation of the right heart chambers. In addition, an extensive laminated filling defect, which extended to the left, was noted in the main PA. The left PA was subtotally occluded as was the left lower lobe and the lingual lobe distally. The upper lobe was partially perfused, and the imaging suggested



Available online at
www.tgkdc.dergisi.org
doi: 10.5606/tgkdc.dergisi.2013.6654
QR (Quick Response) Code

Received: February 04, 2012 Accepted: March 22, 2012

Correspondence: Mehmed Yanartaş, M.D. Department of Cardiothoracic Surgery, Papworth Hospital, CB23 3RE, Cambridge, UK.

Tel: +90 533 - 735 10 16 e-mail: myanartas@yahoo.com

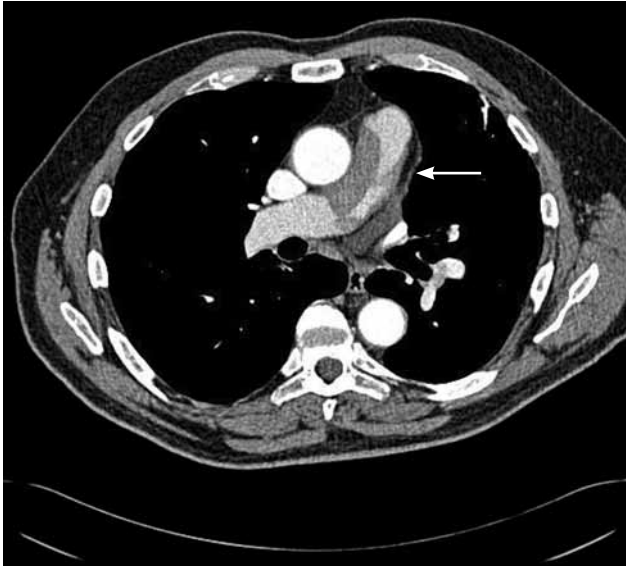

Figure 1. Preoperative computed tomography scan demonstrating the lesion in the main pulmonary artery (arrow).

the possibility of the obstruction being a pulmonary embolism (PE) since it was located so close to the main PA.

After careful discussion, we proceeded with the pulmonary endarterectomy (PEA) to clear the obstruction. Cardiopulmonary bypass (CPB) was established with standard ascending aortic and bicaval venous cannulation, and the patient was cooled to 20 °C to allow for deep hypothermic circulatory arrest (DHCA). The standard set-up for the PEA surgical procedure includes the use of a centrifugal pump in CPB, cell salvage, a topical cooling jacket for the heart and head, blood cardioplegia, the right superior pulmonary vein, the PA, aortic root vents, and cerebral saturation monitoring. For this patient, the elapsed time for the CPB, ischemia, and DHCA was 412, 69, and 25+24 (per side) minutes, respectively. A solid, fibrous, white tumor was resected from the pulmonary trunk and branches of the patient. The pulmonary valve was also involved (Figure 2) and was resected and replaced with a 21 mm St. Jude Epic aortic valve. The patient was then weaned from the CPB without difficulty with normalized PA pressures (Table 1). He

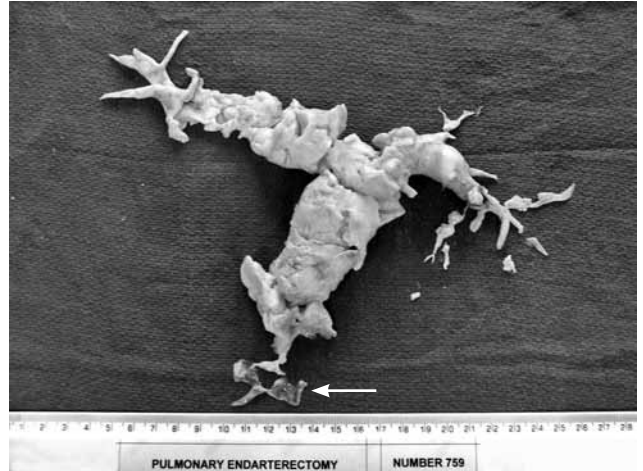


Figure 2. Reconstructed pulmonary artery sarcoma specimen following the pulmonary endarterectomy showing three leaflets of the pulmonary valve (arrow).

had an uncomplicated recovery and was discharged to the oncology service for adjuvant chemotherapy. A histological examination confirmed a medium-to-high grade PA sarcoma that tested positive for smooth muscle actin. There was also a lack of desmin immunostaining, which usually indicates intimal cell sarcoma.

DISCUSSION

Less than 20% of all vascular tumors originate in the arteries.^[3] The majority are malignant sarcomatous neoplasms such as angiosarcoma, leiomyosarcoma, or intimal sarcoma.^[4] Most exhibit bilateral PA involvement and are commonly located in the pulmonary trunk (85%), right or left PAs (71% and 65%, respectively), pulmonary valve (32%), and right ventricular outflow tract (10%).^[5] The origin, etiology, risk factors, and incidence rates of these neoplasms remain uncertain,^[2] and the diagnosis is seldom made preoperatively because the physical findings resemble those of chronic thromboembolic pulmonary hypertension (CTEPH). The differential diagnosis includes pulmonary arteritis, congenital pulmonary stenosis, tumors of the lungs and mediastinum, pulmonary infections, fibrosing mediastinitis, and chronic pulmonary thromboembolic disease.^[3]

Table 1. Preoperative and postoperative pressure values of the patient

| | Preoperative | Day of surgery | Postoperative day 1 |
|--|--------------|----------------|---------------------|
| Mean pulmonary artery pressure (mmHg) | >60 | 26 | 22 |
| Right atrial pressure (mmHg) | 24 | 7 | 7 |
| Mean arterial pressure (mmHg) | 64 | 66 | 83 |
| Pulmonary vascular resistance (dynes/sec/cm-5) | – | 335 | 283 |

A whole body survey that includes CT, CT angiography, MR angiography, and conventional pulmonary angiography is necessary to exclude a primary tumor in another location.^[6] In addition, hilar PA dilatation, increased heart size, changes in the pulmonary vascular pattern, and secondary lesions may arouse suspicion of a pulmonary vascular tumor.^[3] Heterogeneous enhancement of intravascular lesions on MR imaging may help distinguish sarcomas from chronic thromboembolic disease. Furthermore, pedunculated or lobulated lesions or smooth tapering and distal pruning of the pulmonary vessels that can be seen on pulmonary angiography are characteristic of this type of disease.^[3]

Early surgical intervention is important to improve the patients' symptoms, confirm diagnosis, and offer palliation. If delayed, right heart failure and secondary tricuspid valve regurgitation can occur.^[7] However, tricuspid valve repair is not routinely performed since the function returns to normal with the restoration of tricuspid annular geometry and RV remodeling.^[8]

Pulmonary angiosarcomas should be totally removed, including the branches of the pulmonary arterial tree, or "tails" as they are sometimes called. Proximal invasion of the pulmonary valve necessitates replacement. In our experience with 800 PEA procedures, there have been fewer than 20 cases with pulmonary sarcoma. However, all resected material should be sent for a histological examination since the tumor appearance is highly variable and may contain thrombotic disease.

Total surgical resection with chemotherapy and/or radiotherapy or excision of all gross tumors in combination with adjuvant treatment offers these patients significant palliation, improved quality of life (QoL), and a better chance of survival.^[8] A complete

cure is rare, but some patients enjoy prolonged survival of more than five years.

There is little data available on the optimal adjuvant treatment, and unfortunately, these tumors are not particularly chemo- or radio-sensitive.

Declaration of conflicting interests

The authors declared no conflicts of interest with respect to the authorship and/or publication of this article.

Funding

The authors received no financial support for the research and/or authorship of this article.

REFERENCES

1. Mandelstamm M. Uber primäre Neubildungen des Herzens. *Virchows Arch Pathol Anat* 1923;245:43-54.
2. Johansson L, Carlén B. Sarcoma of the pulmonary artery: report of four cases with electron microscopic and immunohistochemical examinations, and review of the literature. *Virchows Arch* 1994;424:217-24.
3. Anderson MB, Kriett JM, Kapelanski DP, Tarazi R, Jamieson SW. Primary pulmonary artery sarcoma: a report of six cases. *Ann Thorac Surg* 1995;59:1487-90.
4. Hsing JM, Thakkar SG, Borden EC, Budd GT. Intimal pulmonary artery sarcoma presenting as dyspnea: case report. *Int Semin Surg Oncol* 2007;4:14.
5. Cox JE, Chiles C, Aquino SL, Savage P, Oaks T. Pulmonary artery sarcomas: a review of clinical and radiologic features. *J Comput Assist Tomogr* 1997;21:750-5.
6. Janssen JP, Mulder JJ, Wagenaar SS, Elbers HR, van den Bosch JM. Primary sarcoma of the lung: a clinical study with long-term follow-up. *Ann Thorac Surg* 1994;58:1151-5.
7. Chhaya NC, Goodwin AT, Jenkins DP, Pepke-Zaba J, Dunning JJ. Surgical treatment of pulmonary artery sarcoma. *J Thorac Cardiovasc Surg* 2006;131:1410-1.
8. Jamieson SW, Kapelanski DP. Pulmonary endarterectomy. *Curr Probl Surg* 2000;37:165-252.