

Device embolization associated with percutaneous closure of atrial septal defect

Atriyal septal defektin perkütan kapatılması ile ilişkili cihaz embolizasyonu

Ali Kemal Gür

Department of Cardiovascular Surgery, Van Regional Training and Research Hospital, Van, Turkey

Atrial septal defect (ASD) is one of the most common congenital cardiac anomalies in adulthood. In this article, we report a 28-year-old female case of a device embolization due to the migration of the device to the main pulmonary artery which was detected one day later during repeated echocardiography after the percutaneous closure of the ASD. The patient who was diagnosed with device embolization was immediately operated. The device was removed through a longitudinal incision to the pulmonary artery and ASD was closed with a pericardial patch. The patient who experienced no complications in the postoperative period was discharged with recovery on the fifth postoperative day.

Key words: Atrial septal defect; device embolization; emergency surgery.

Percutaneous closure of a secundum atrial septal defect (ASD) has become a standard treatment modality in recent years because it is safe and has high success rates. However, even when performed by experienced hands, device embolization can occur, which is a rare but serious complication of this procedure. If the migrated device is not removed percutaneously and is in a position where it is a risk factor for other cardiac structures, the device should be surgically retrieved immediately, and the ASD should be closed directly.

CASE REPORT

A 28-year-old female was referred to our cardiology outpatient clinic because of shortness of breath

Atriyal septal defekt (ASD) erişkinlerde görülen en sık doğuştan kalp anomalilerinden biridir. Bu yazıda ASD'nin perkütan yoldan kapatılması sonrası ertesi gün yapılan kontrol ekokardiyografide cihazın ana pulmoner artere ilerleyerek cihaz embolizasyonuna neden olduğu 28 yaşında bir kadın olgu sunuldu. Hastaya cihaz embolisi tanısı konularak acil ameliyata alındı. Pulmoner artere longitudinal insizyon yapılarak cihaz çıkarıldı ve ASD perikard yama ile kapatıldı. Ameliyat sonrası dönemde herhangi bir komplikasyon görülmeyen hasta ameliyat sonrası beşinci gün şifa ile taburcu edildi.

Anahtar sözcükler: Atriyal septal defekt; cihaz embolizasyonu; acil cerrahi.

and palpitation. The mid-diastolic murmur at the mesocardiac focus in the cardiac examination of the patient revealed a secundum ASD via transthoracic echocardiography. Because the ASD was smaller than 30 mm and the rim was inadequate, the patient was recruited for a trans-catheter ASD procedure because the atrial rim which was located far from other cardiac structures such as the mitral valve, tricuspid valve, superior vena cava, right upper pulmonary vein, and coronary sinus. The Amplatzer device (St. Jude Medical Inc., Cardiovascular and Ablation Technologies, Plymouth, MN, USA, 2011) was implanted successfully without any complications during the catheterization procedure, and the patient was transferred to her room after the procedure was



Available online at
www.tgkdc.dergisi.org
doi: 10.5606/tgkdc.dergisi.2013.6663
QR (Quick Response) Code

Received: February 08, 2012 Accepted: May 11, 2012

Correspondence: Ali Kemal Gür, M.D. Van Bölge Eğitim ve Araştırma Hastanesi Kalp ve Damar Cerrahisi Anabilim Dalı, 65100 Van, Turkey.

Tel: +90 432 -217 91 00 e-mail: dralikemal@gmail.com

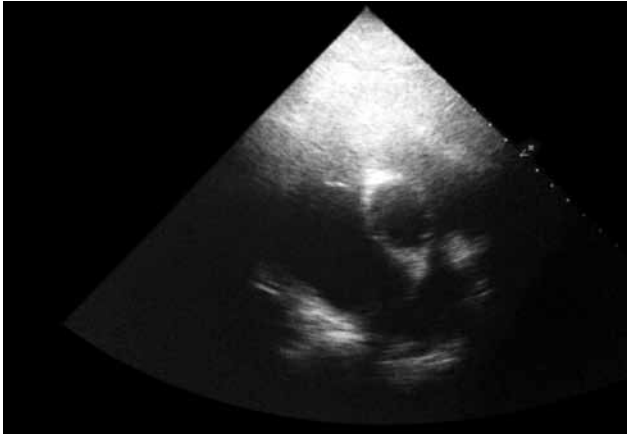


Figure 1. Transthoracic echocardiography (long-axis view) showing the device migration in the main pulmonary artery.

completed. On the first postoperative day, control echocardiography detected that the implanted device was malpositioned and was proceeding towards the pulmonary artery (PA) from the pulmonary valve as an embolus (Figure 1). Immediate surgery was planned, and the patient was taken to the operation room.

The operation

After diagnosing the transcatheter embolus, the patient was immediately operated on under general anesthesia. A standard median incision was applied, and a 5x5 cm pericardial patch was prepared. Cardiopulmonary bypass (CPB) was then established through arterial and bicaval cannulation. After cardiac arrest, a longitudinal incision over the main PA revealed the device in the main pulmonary artery, which was in a parallel position inside the vein. The device, including the fresh thrombus material inside,




Figure 2. Removal of the device with a longitudinal incision of the main pulmonary artery.

was then removed from the pulmonary arteriotomy region (Figure 2 and 3), and the PA contour was closed via primer suture. A right atriotomy indicated the presence of ASD, and a weak ASD rim. This rim was resected until the intact rim could be seen, and the ASD was closed with the pericardial patch. After the air in the heart was evacuated, the cross-clamp was removed, and the heart began to beat spontaneously. No more complications were encountered while exiting CPB. Since there were no postoperative problems, the patient was transferred to her room, but treatment with warfarin sodium (5 mg tablet 1x1) and acetylsalicylic acid (100 mg tablet 1x1) was initiated to avoid a possible pulmonary embolism. The patient was discharged on the fifth postoperative day without any complications after the international normalized ratio (INR) and warfarin dosage were adjusted.

DISCUSSION

Thanks to advanced techniques and imaging devices, diagnosis and treatment of congenital heart diseases can be readily performed; therefore, the number of adults identified with a congenital heart disease has gradually increased. One advantage of transcatheter obstructive devices, which are now a part of routine therapy for congenital heart diseases, is that they can be closed without surgical intervention. In addition, they can also be used for certain congenital heart diseases like ASD, patent foramen oval, ventricular septal defect, and patent ductus arteriosus.^[1] The percutaneous catheter closure procedure is not the only option for the closure of congenital heart disease, but

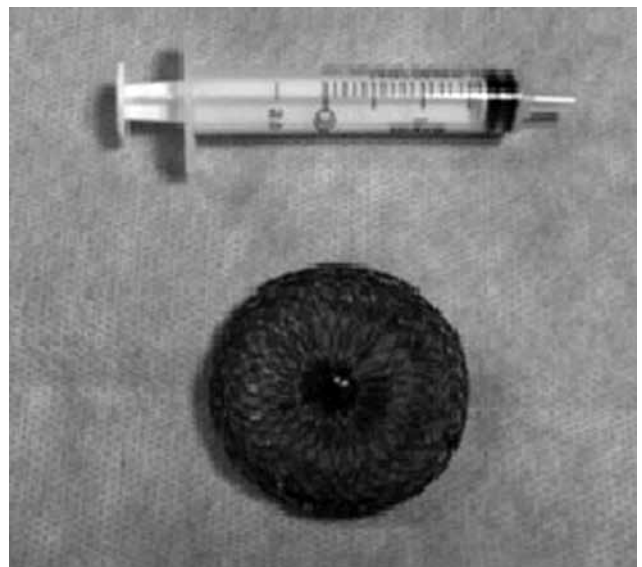

Figure 3. Macroscopic image of the removed device.

it can also be utilized in procedures to treat acquired heart diseases such as the percutaneous replacement of the aortic valve, restoration of the percutaneous mitral valve, closure of the left atrial appendix (to prevent thrombus formation secondary to atrial fibrillation),^[2] closure of a left ventricular aneurism, and closure of a percutaneous sinus of valsalva rupture. Complications, such as postpericardiectomy syndrome, arrhythmia and cerebrovascular accident along with side effects related to CPB and even death are possible during surgical operations, and transcatheter closure procedures may provide a better outcome. However, complications such as device emboli may arise during the transcatheter closure procedure.

Chan et al.^[3] presented the case of a 23-year-old patient with device emboli and subsequent palpitation and ventricular tachycardial symptoms four hours after the closure of a large ASD. Echocardiography demonstrated that the device was located inside the right ventricle; therefore, the patient was taken to the catheter laboratory again, and the device was successfully retrieved via a percutaneous route.

In a study carried out by Massimo et al.,^[4] they reported in detail regarding the complications associated with ASD closure. A total of 36 complications were observed after the closure procedure was performed on 417 patients, and the authors classified the complications as either major or minor. Major complications included device malposition and device emboli, whereas minor complications referred to noncritical malposition, pericardial effusion, thrombus formation at the left atrial disk, right iliac vein dissection, hematoma at the entry site, and hemorrhage at the retropharyngeal region. In addition, they noted that peripheral emboli occurred in the left leg of one patient a year after the procedure, and this patient died suddenly one and a half years later. This death was reported as a late complication.

Furthermore, in a study conducted by Vitiello et al.,^[5] 4,952 patients underwent the transcatheter closure procedure, and the most frequent complications were arrhythmia (22.7%) and vascular hemorrhage (7.5%), and device embolization (3%).

Butera et al.^[6] compared percutaneous and surgical closure of secundum atrial defects and determined that percutaneous closure has lower mortality and morbidity rates than surgical closure. Their cohort study was conducted on 3,082 patients, and 6.8% reported major complications at surgical closure while only 1.9% reported them at percutaneous closure.

While transcatheter closure procedures are normally safe, complications are possible. Therefore, a rapid diagnosis is crucial in order to remove the device percutaneously. However, after determining the cardiac level of the device, appropriate surgical intervention may be required.

Declaration of conflicting interests

The authors declared no conflicts of interest with respect to the authorship and/or publication of this article.

Funding

The authors received no financial support for the research and/or authorship of this article.

REFERENCES

1. Du ZD, Hijazi ZM, Kleinman CS, Silverman NH, Larntz K; Amplatzer Investigators. Comparison between transcatheter and surgical closure of secundum atrial septal defect in children and adults: results of a multicenter nonrandomized trial. *J Am Coll Cardiol* 2002;39:1836-44.
2. Al-Saady NM, Obel OA, Camm AJ. Left atrial appendage: structure, function, and role in thromboembolism. *Heart* 1999;82:547-54.
3. Chan KT, Cheng BC. Retrieval of an embolized amplatzer septal occluder. *Catheter Cardiovasc Interv* 2010;75:465-8.
4. Chessa M, Carminati M, Butera G, Bini RM, Drago M, Rosti L, et al. Early and late complications associated with transcatheter occlusion of secundum atrial septal defect. *J Am Coll Cardiol* 2002;39:1061-5.
5. Vitiello R, McCrindle BW, Nykanen D, Freedom RM, Benson LN. Complications associated with pediatric cardiac catheterization. *J Am Coll Cardiol* 1998;32:1433-40.
6. Butera G, Biondi-Zoccai G, Sangiorgi G, Abella R, Giamberti A, Bussadori C, et al. Percutaneous versus surgical closure of secundum atrial septal defects: a systematic review and meta-analysis of currently available clinical evidence. *EuroIntervention* 2011;7:377-85.