

Recurrent spontaneous pneumothorax in pregnancy

Gebelikte tekrarlayan spontan pnömotoraks

Deniz Cemgil Ankan,¹ Mahmut Tokur,² Mehmet Ergin,³ Derya Yenibertiz⁴

¹Department of Obstetrics and Gynecology,

Medical Faculty of Kahramanmaraş Sütçü İmam University, Kahramanmaraş, Turkey

²Department of Chest Surgery, Medical Faculty of Kahramanmaraş Sütçü İmam University, Kahramanmaraş, Turkey

³Department of Emergency, Medical Faculty of Selçuk University, Konya, Turkey

⁴Department of Chest Disease, Kahramanmaraş State Hospital, Kahramanmaraş, Turkey

Spontaneous pneumothorax is a life-threatening pathology which occurs rarely during pregnancy. In this article, we report a 28-years-old G2P1 pregnant female case with a gestational week of 34 who was admitted to our antenatal clinic with the complaints of chest pain and dyspnea. Chest X-ray showed an extensive pneumothorax in the right side. Pneumothorax developed twice over approximately 15 days following chest tube insertion. An urgent cesarean section was performed under spinal anesthesia with the chest drain in situ. During her follow-up the thoracic computed tomography revealed a bulla at the lower lobe of the right hemithorax. We performed right thoracotomy and bullectomy.

Key words: Pneumothorax; pregnancy; recurrence; spontaneous.

A spontaneous pneumothorax is a life-threatening pathology that occurs due to the collection of extrapulmonary air within the chest accompanied by lung collapse without trauma to the lung or chest wall. It is a unusual disorder during pregnancy, with approximately only 50 cases in the literature.^[1] Diagnosing a pneumothorax is not easy since it can be interfused with dyspnea in pregnancy. In addition, the etiology of a spontaneous pneumothorax is not well known.^[2]

In this case report, we describe the diagnosis and treatment of a patient who experienced recurrent pneumothoraces that developed during her pregnancy after the 34th week of gestation.

Spontan pnömotoraks gebelikte nadir görülen, hayatı tehdit eden bir patolojidir. Bu yazıda, göğüs ağrısı ve nefes darlığı yakınmaları ile doğum öncesi kliniğimize başvuran, G2P1 gebeliğinin 34. haftasında olan 28 yaşında bir kadın olgu sunuldu. Akciğer grafisinde sağda yaygın pnömotoraks izlendi. Göğüs tüpü takıldıktan sonra hastada yaklaşık 15 gün içerisinde iki kez pnömotoraks gelişti. Hastaya göğüs tüplü olarak spinal anestezi altında acil sezaryan yapıldı. Hastanın takibinde çekilen toraks bilgisayarlı tomografisinde hemitoraks sağ alt lobda bül görüldü. Sağ torakotomi ile büllektomi yapıldı.

Anahtar sözcükler: Pnömotoraks; gebelik; nüks; spontan.

CASE REPORT

A 28-year-old G2P1 pregnant women was admitted to our antenatal clinic with complaints of chest pain and dyspnea. She had no obstetric pathology and was a non-smoker with no history of pulmonary disease. We consulted with the chest diseases department, and an examination revealed no respiratory sounds on the right side of the thorax. A chest X-ray also showed an extensive pneumothorax on the right side (Figure 1a). A right tube thoracostomy was then performed, and the pneumothorax resolved completely after a few days (Figure 1b). Seven days later she was readmitted to our clinic with the same complaints. We detected an extensive right pneumothorax and reinserted a chest



Available online at
www.tgkdc.dergisi.org
doi: 10.5606/tgkdc.dergisi.2013.5658
QR (Quick Response) Code

Received: May 22, 2011 Accepted: October 17, 2011

Correspondence: Mahmut Tokur, M.D. Kahramanmaraş Sütçü İmam Üniversitesi
Tıp Fakültesi Göğüs Cerrahisi Kliniği, 46050 Kahramanmaraş, Turkey.

Tel: +90 344 - 225 75 75 e-mail: mahmuttokur@hotmail.com

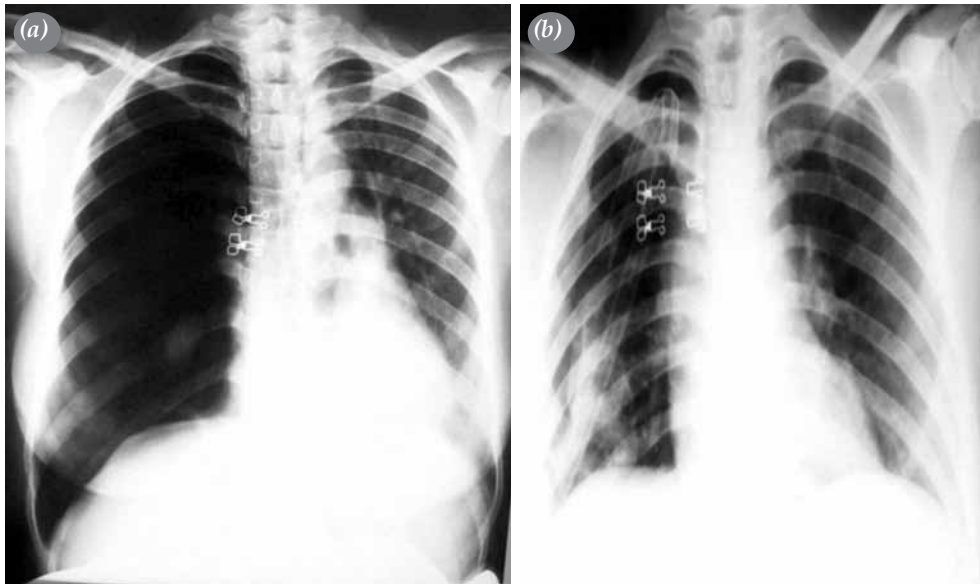


Figure 1. (a) Chest X-ray showing the right total pneumothorax (first pneumothorax). (b) Chest X-ray after chest tube insertion.

tube (Figure 2). Three days later the patient's uterine contractions started. An urgent cesarean section was performed under spinal anesthesia with the chest drain in situ, and a healthy female infant (weight 2,880 g with Apgar scores of 7 and 9 at one and five minutes, respectively) was delivered. No complications were seen afterwards and, the patient was discharged from the hospital five days later. At the one-month follow-up, thoracic computed tomography (CT) revealed a bulla

at the lower lobe of the right hemithorax (Figure 3a). Therefore, a right thoracotomy and bullectomy were performed (Figure 3b), and there were no postoperative complications.

DISCUSSION

A pneumothorax is a pathological condition in which there is an accumulation of air in the pleural cavity accompanied by lung collapse with no trauma to the lung or chest wall.^[3] When there are no etiological factors, it is known as a primary pneumothorax, but if etiological factors exist, such as a bullous lung or tuberculosis (TB), then it is called a secondary pneumothorax. A spontaneous pneumothorax during pregnancy is a very rare condition, and pre-existing risk factors, including lung diseases such as chronic obstructive pulmonary disease (COPD), asthma, TB, and pneumonia as well as certain types of interstitial lung disease may contribute to this condition.^[1,3] Although a spontaneous pneumothorax is mostly related to the presence of small apical blebs or bullae in a healthy, young population, the exact etiology of this pathology in pregnant women is not known.^[3] It is possible that both pneumothoraces in our patient might have been caused by the rupture of the bulla that we detected on the thoracic CT.

The possibility of a recurring spontaneous pneumothorax in pregnant women is 30-40%, with the majority occurring during the same pregnancy or in the postpartum stage.^[2,3] In their report, Terndrup et al.^[4] noted spontaneous pneumothoraces during

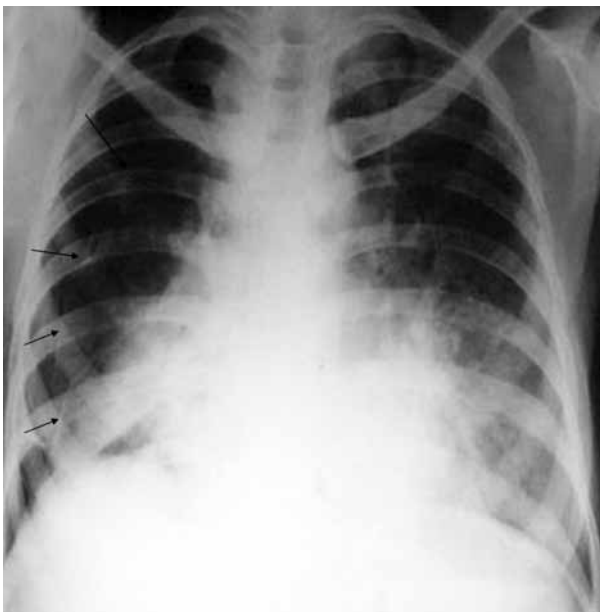

Figure 2. Chest X-ray showing the second right pneumothorax (arrows).

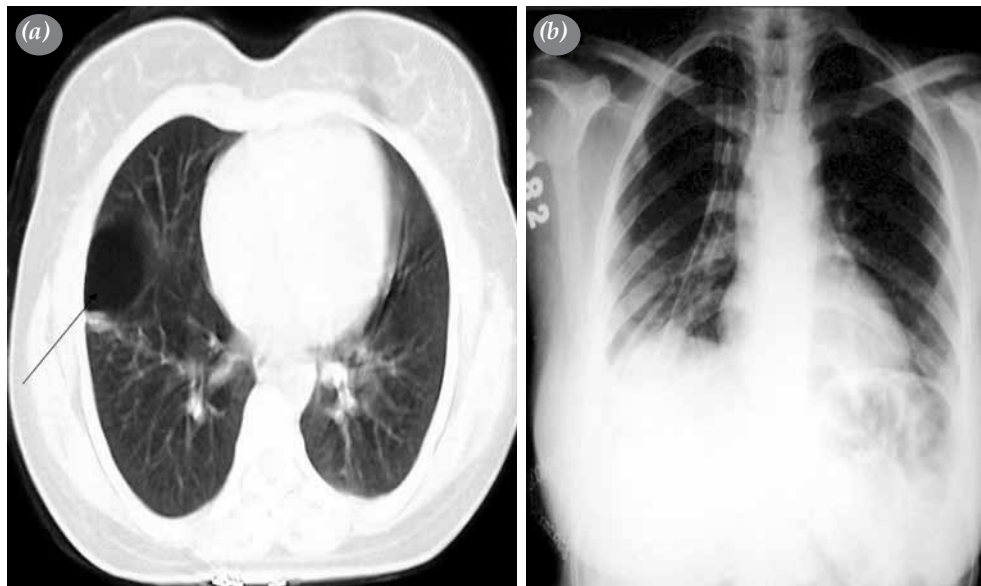


Figure 3. (a) Computed tomographic view of the bulla at the lower lobe of the right hemithorax (arrow). (b) Chest X-ray showing an early postoperative view.

pregnancy. Additionally, Dhalla and Teskey^[3] reported a case with four recurrent spontaneous pneumothorax episodes that occurred before the end of the second trimester, and Sills et al.^[11] presented a case with recurrent spontaneous pneumothoraces in the same pregnancy as well as in two consecutive pregnancies, both of which involved the hemithoraces.

Treatment of a recurrent pneumothorax during pregnancy is the same as for women who are not pregnant and is based on the evacuation of air from the pleural space which permits the lung to reexpand.^[11] In the literature, treatment options for a pneumothorax included observation in 29.6% of the patients, a thoracotomy in 3.8% and a tube thoracostomy, as our patient underwent, in 66.6%.^[5] Although there are usually no clear indications for the operative treatment of a pneumothorax, persistent occurrences despite adequate drainage or multiple recurrences during pregnancy are valid indications that surgery is needed.^[1,6] The operation can be performed via either a traditional thoracotomy or a more recent, less invasive procedure like video-assisted thoracoscopic surgery (VATS), which is commonly done through a pleurectomy or the mechanical scrubbing of the pleural surface.^[7] Although Jain and Goswami^[8] treated their pregnant case with a pneumothorax with a chest tube drain, they removed it after the baby was delivered, and performed VATS along with an apical pleurectomy. Lal et al.^[2] treated five of their six cases by aspiration while a chest drain was inserted in one patient. They also performed VATS on four of their

six cases after they delivered.^[2] The optimal time for surgical intervention is during the second trimester, and there have been no recent reports of adverse maternal outcomes or deaths due to pneumothoraces during pregnancy.^[1,6] For our patient, lung reexpansion was provided with a chest tube for several days in the first and second pneumothoraces. We had to insert a chest tube when the pneumothorax reoccurred because our hospital lacks the adequate equipment to perform VATS. Our patient had her baby before we removed the chest tube the second time. Some might argue that if she had not delivered when she did, then she would not have received the benefits from the chest tube and her clinical condition would have become worse. In addition, they point out that if the baby had been born later, then we would have had to perform thoracic CT and a bullectomy before the delivery. We believe that the delivery ameliorated the respiratory functions of the patient; thus, the chest tube was sufficient to treat the recurrence of the pneumothorax.

Although there is no contraindication for normal vaginal delivery, in order to prevent the increase in intrathoracic pressure that occurs during spontaneous delivery due to repeated Valsalva maneuvers, epidural anesthesia and instrumental delivery are often recommended to shorten the second phase of labor in patients with a pneumothorax.^[6] We preferred a cesarean delivery because of the recurrence of this condition and because the chest tube was in situ during our patient's labor. In addition, in order to

prevent the increase in intrathoracic pressure due to the intubation and positive-pressure ventilation during general anesthesia, we performed spinal anesthesia instead.

In conclusion, a spontaneous pneumothorax must be considered in pregnant women who present with complaints of chest pain and dyspnea. Furthermore, as we detected on thoracic CT, a bulla can be responsible for a pneumothorax during pregnancy. Maternal risks associated with this condition are respiratory problems, and the fetal risks include a decrease in oxygen support and preterm labor. An appropriate treatment method should be chosen by evaluating the complications that present in the mother and baby since these will vary according to the severity of the pneumothorax.

Declaration of conflicting interests

The authors declared no conflicts of interest with respect to the authorship and/or publication of this article.

Funding

The authors received no financial support for the research and/or authorship of this article.

REFERENCES

1. Sills ES, Meinecke HM, Dixson GR, Johnson AM. Management approach for recurrent spontaneous pneumothorax in consecutive pregnancies based on clinical and radiographic findings. *J Cardiothorac Surg* 2006;1:35.
2. Lal A, Anderson G, Cowen M, Lindow S, Arnold AG. Pneumothorax and pregnancy. *Chest* 2007;132:1044-8.
3. Dhalla SS, Teskey JM. Surgical management of recurrent spontaneous pneumothorax during pregnancy. *Chest* 1985;88:301-2.
4. Terndrup TE, Bosco SF, McLean ER. Spontaneous pneumothorax complicating pregnancy--case report and review of the literature. *J Emerg Med* 1989;7:245-8.
5. Garg R, Sanjay, Das V, Usman K, Rungta S, Prasad R. Spontaneous pneumothorax: an unusual complication of pregnancy--a case report and review of literature. *Ann Thorac Med* 2008;3:104-5.
6. VanWinter JT, Nichols FC 3rd, Pairolero PC, Ney JA, Ogburn PL Jr. Management of spontaneous pneumothorax during pregnancy: case report and review of the literature. *Mayo Clin Proc* 1996;71:249-52.
7. Wong MK, Leung WC, Wang JK, Lao TT, Ip MS, Lam WK, et al. Recurrent pneumothorax in pregnancy: what should we do after placing an intercostal drain. *Hong Kong Med J* 2006;12:375-80.
8. Jain P, Goswami K. Recurrent spontaneous pneumothorax during pregnancy: a case report. *J Med Case Rep* 2009;3:81.