

Different reconstructive methods after resection of tumors located in the tracheal carina in three cases

Üç olguda trakeal karina yerleşimli tümörlerin rezeksiyonundan sonra farklı rekonstrüksiyon yöntemleri

Erdal Okur,¹ Cansel Atinkaya,² Volkan Baysungur,² Hacer Okur Kuzu,³ İrfan Yalçinkaya²

Institution where the research was done:

Department of Thoracic Surgery, Medical Faculty of Acıbadem University, İstanbul, Turkey

Author Affiliations:

¹Department of Thoracic Surgery, Medical Faculty of Acıbadem University, İstanbul, Turkey

Departments of ²Thoracic Surgery and ³Pulmonology, Süreyyapaşa Chest Diseases and Thoracic Surgery Training and Research Hospital, İstanbul, Turkey

Surgical resection of tumors which are located within or extend into the tracheal carina is challenging. Complete carinal resection can be safely performed, if an appropriate reconstructive method is selected based on the tumor location. In this article, we report three cases in which different carinal reconstruction methods were applied.

Key words: Carinal resection; carinal tumor; lung cancer.

Reconstructive techniques performed after the resection of tracheal carinal tumors are complex surgical procedures. These tumors are at the locally advanced stage, and choosing the appropriate surgical method requires careful consideration based on the location and the extent of the tumor.

The method for creating a “new carina” after carinal resection was first described by Barclay,^[1] and today, this approach along with the “double-barrel” technique are the two primary reconstructive methods used in this procedure.^[2] Herein, we report three cases in which we used different reconstructive methods after the resection of the tracheal carina.

CASE REPORT

Case 1- A 49-year-old man presented with a cough which had lasted for one month. He had a 25 pack-year smoking history and had undergone anti-tuberculosis

Trakeal karinada yerleşen veya trakeal karinaya uzanım gösteren tümörlerin cerrahi rezeksiyonu güçtür. Tümörün yerleştiği yere göre uygun rekonstrüksiyon yöntemi seçilir ise, tam karina rezeksiyonu güvenli bir şekilde yapılabilir. Bu yazıda, farklı karina rekonstrüksiyon yöntemleri uygulanan üç olgu sunuldu.

Anahtar sözcükler: Karina rezeksiyonu; karina tümörü; akciğer kanseri.

therapy 25 years previously. During a physical examination, his breath sounds were decreased, and rales were heard in his right upper lung. In addition, a plain chest X-ray showed a lesion of non-homogeneous density in his right upper lung, but the patient’s laboratory findings were normal. Pulmonary function tests revealed a forced expiratory volume in the first second (FEV1) of 2.89 L (91%) and a forced vital capacity (FVC) of 3.18 L (82%). Computed tomography (CT) of the chest indicated an irregularly contoured mass lesion located in the right upper lobe (RUL) of the lung in the paratracheal region along with atelectasis in the apical and anterior segments of the RUL secondary to bronchial obstruction. During a fiberoptic bronchoscopy (FOB), we detected mucosal invasion of the right tracheobronchial angle and tumoral obstruction of the RUL bronchus. The pathological results of a biopsy taken from the lesion revealed a squamous cell carcinoma, and positron emission



tomography (PET)-CT showed a hypermetabolic [maximum standard uptake value (SUVmax) of 16.4] lesion in the right upper lung but nothing abnormal in any other areas of the body. Magnetic resonance imaging (MRI) of the cranium was also normal.

The operation began with a rigid bronchoscopy, which determined that the tumor was obstructing the RUL bronchus and invading the right main bronchus up to the tracheobronchial angle. A standard cervical mediastinoscopy was then performed. Tissue biopsies were obtained from the mediastinal 2R, 4R, and 7 lymph node stations, and all were pathologically negative for metastatic disease. Next, we performed a right thoracotomy through the fourth intercostal space. After systematic sampling of the mediastinal lymph nodes, we dissected the tracheal carina and the intermediary bronchus. A sleeve lobectomy of the RUL was performed, and the specimen was sent for frozen section pathology to evaluate whether invasion of the bronchial margins had occurred. Because the carinal side of the main bronchus was positive for a tumor, we resected the tracheal carina by first making an end-to-end anastomosis between the trachea and the left main bronchus using 3-0 polyglactin (Vicryl, Ethicon, Somerville New Jersey, USA) absorbable sutures. An orifice was then opened at the medial side of the left main bronchus, and a second end-to-side anastomosis was made between the orifice and the right intermediate bronchus using 3-0 polydioxanone sutures (PDS, Ethicon, Sumerville New Jersey, USA) absorbable sutures (Figure 1).

The postoperative period was uneventful, but during the patient's 13-month follow-up period, we

detected metastasis on the right chest wall. The patient was treated with radiotherapy and is now doing well.

Case 2- A 44-year-old male was admitted with a six-month history of hemoptysis. His medical history revealed nothing out of the ordinary, and his physical examination was normal. A plain chest radiography revealed an increased density in the hilum of the right lung, and a chest CT showed a mass lesion in the right main bronchus extending to the tracheal carina. An FOB examination showed a tumoral lesion starting at the tracheal carina and extending into the right main bronchus. The pathological results of a biopsy taken from the lesion indicated an adenoid cystic carcinoma. In addition PET-CT indicated a right hilar hypermetabolic mass lesion (SUVmax of 6.3) but no extrathoracic hypermetabolic lesions.

We performed a rigid bronchoscopy to determine the extent of the tumor in the tracheal and main bronchus sites. The patient was intubated with a single-lumen endotracheal tube, and a right posterolateral thoracotomy was performed. The tracheal carina and right main bronchus were resected, and the distal trachea anastomosed end-to-end to the left main bronchus using an interrupted 3-0 polyglactin suture. The distal end of the right main bronchus was then anastomosed to the medial orifice of the left main bronchus using a continuous 3-0 PDS suture (Figure 2). An examination of the frozen sections showed that all bronchial margins were negative, but a submucosal microscopic extension was detected in the distal tracheal margin. The postoperative period was uneventful, and the patient received adjuvant radiotherapy. He is currently at the 31st postoperative month and remains disease-free.

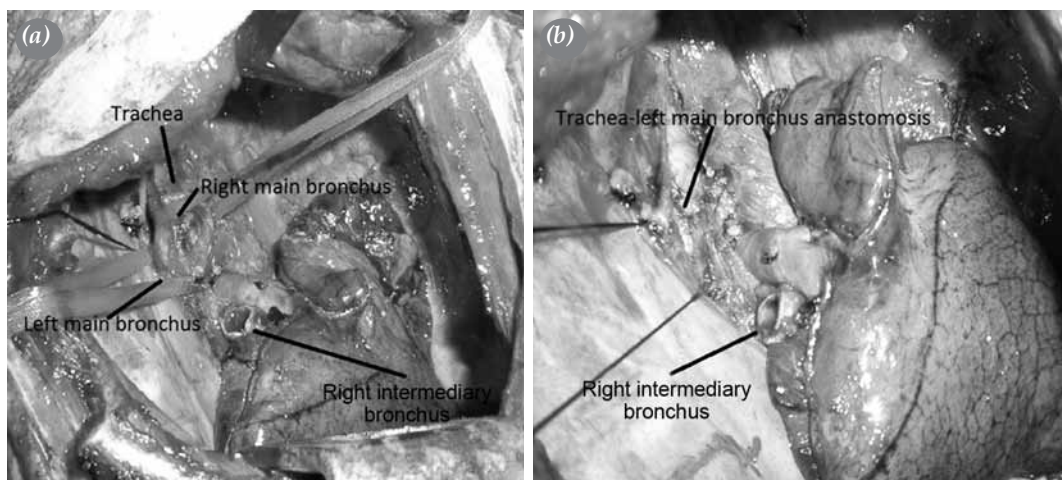


Figure 1. Operative view after (a) a sleeve right upper lobectomy; (b) tracheal left main bronchus anastomosis (the right intermediary bronchus will be anastomosed to the left main bronchus).

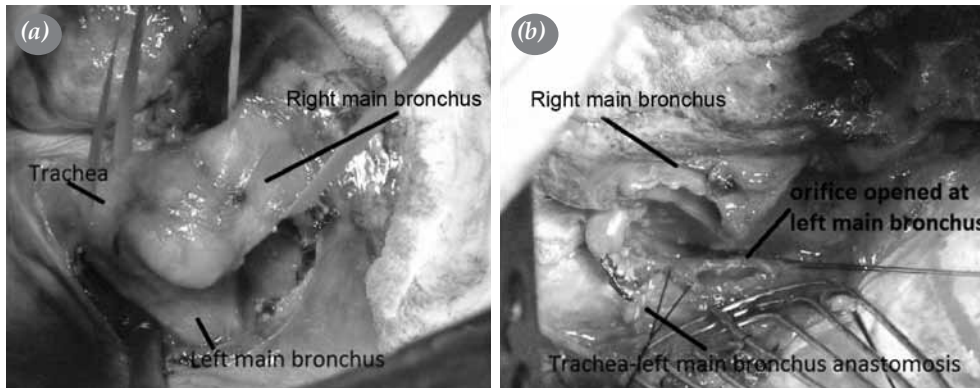


Figure 2. (a) Tumor in the right main bronchus extending to the tracheal carina. (b) View after the anastomosis of the trachea and left main bronchus. The right main bronchus will be anastomosed to the orifice that is shown.

Case 3– A 46-year-old man was admitted with cough that had been ongoing for three months. He had been a smoker for 20 years and was receiving bronchodilator therapy. His physical examination was normal. A plain chest radiography was also normal, but thoracic CT identified a 2 cm tumoral lesion at the tracheal carina level. In addition, an FOB revealed a tumoral mass at the tracheal bifurcation that was partially obstructing both main bronchi. The pathological results of the biopsy indicated a non-small-cell carcinoma. On a PET-CT examination, this lesion was hypermetabolic (SUVmax of 15), and an additional subcarinal lymph node was observed. A cranial MRI was normal.

We first performed a rigid bronchoscopy and observed the tumor originating from the tracheal carina and partially obstructing both main bronchi. The patient then underwent a cervical mediastinoscopy, and samples were taken from both

paratracheal nodal stations. The immediate results were negative for tumor metastasis, so we performed a right posterolateral thoracotomy. The tracheal carina and both main bronchi were released, the tracheal carina was resected, and the distal trachea was anastomosed to the proximal end of the left main bronchus using interrupted 3-0 polyglactin sutures. An end-to-side anastomosis was then made between the right main bronchus and the right lateral side of the distal trachea while maintaining greater than a 1 cm distance between the anastomoses (Figure 3). The pathological results indicated a T₄N₀M₀ squamous cell carcinoma. The patient received adjuvant radiotherapy and is still being follow-up at six months later.

DISCUSSION

Tumors invading the tracheal carina can be curatively resected, even though they are defined as being

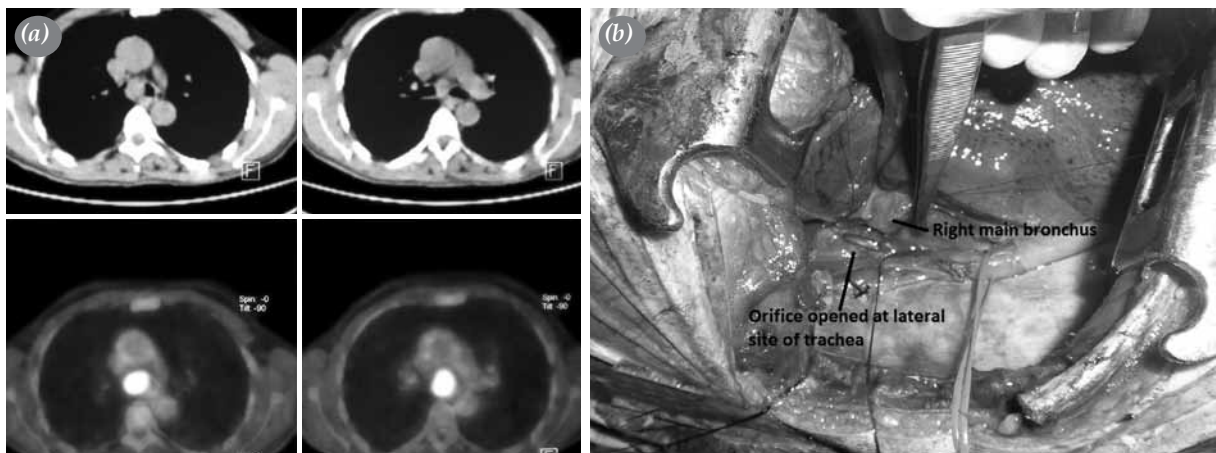


Figure 3. (a) Computed tomographic view of the tumor located at the tracheal carina. (b) Orifice opened at the lateral site of the trachea for the anastomosis with the right main bronchus.

locally advanced. Carinal resections are technically challenging and require considerable expertise, and the tension on the anastomoses should be kept at a minimum to prevent complications. Several methods for tracheal reconstruction after carinal resection have been previously described. In the double-barrel method, the two main bronchi undergo side-by-side anastomosis and then are anastomosed to the distal carina.^[3] This method best simulates the original carina, but to avoid tension at the site of the anastomosis, it is most often used after a small segmental resection of the carina without the resection of the lung and main bronchus.

In Barclay's method, the distal trachea is anastomosed end-to-end to one of the main bronchi and then the second bronchus is anastomosed end-to-side to the medial side of the first bronchus.^[1] In this method, the tension on both anastomoses is reduced, but the vascular supply to the anastomosis site becomes an important issue. The surgeon should perform minimal dissection to preserve the vascular supply to the bronchus, and there should be at least 1 cm between the two anastomoses.^[4] We used the Barclay method for two of our cases. In Case 1, the RUL and tracheal carina were resected together, and because the remaining intermediary bronchus did not extend to the trachea, it was anastomosed to the medial side of the left main bronchus. Similarly, the RUL was not resected in Case 2, but the right main bronchus was shortened and anastomosed to the left main bronchus. If a lobectomy is not performed, or a long segment main bronchus is not resected, the main bronchus can be anastomosed end-to-side to the lateral side of the lower trachea rather than to the second medial site of the main bronchus. Anastomotic tension can be relieved by releasing the pulmonary ligament or incising the pericardium around the inferior pulmonary vein, which helps the lung to move upward. We used this method in Case 3 to bring the right main bronchus to the level of the trachea. If the bronchus can easily reach the trachea, it is our opinion that anastomosing the right main bronchus to the trachea is superior to the left main bronchus because of the wider caliber of the tracheal lumen.

Yamamoto et al.^[3] proposed an alternative carinal reconstruction method to that of Barclay in which an anastomosis between the trachea and the left main bronchus is done at the beginning. However, rather than performing a complete anastomosis, they anastomose the posterolateral and posterior walls and leave the medial wall open. They then insert and anastomose the right main bronchus to this medial orifice. They

claim this method decreases tension at the anastomosis sites. We believe this approach is similar to the double-barrel method and provides the same advantages and disadvantages.

We began each of our operations with a rigid bronchoscopy to explore the location and extent of the tumor. Additionally, we preferred to intubate with a single-lumen tube for Cases 2 and 3 for three reasons. First, a double-lumen tube may have caused disruption or bleeding of the carinal tumor. Second, a double-lumen tube would have needed to be withdrawn when the left bronchus was cut. Finally, the double-lumen tube would have needed to be replaced with a single-lumen tube after the carinal resection, which would have been difficult with the patient in the lateral decubitus position. Dissection of the tracheal carina while the right lung was ventilating was not problematic.

In Case 1, we used a double-lumen tube because we initially were unsure of the carinal resection, so we first performed an upper sleeve lobectomy. After we divided the left main bronchus from the trachea, we placed a sterile small-sized intubation tube into the left main bronchus to directly ventilate the left lung. Both the carinal resection and the reconstruction were then performed with ease because the right lung was not being ventilated. The orotracheal tube was withdrawn slightly, but it was not completely removed because ventilation was maintained through this tube after carinal reconstruction. We routinely released both hila but did not perform extensive dissection to avoid disrupting the vascular supply to the bronchi. The pulmonary ligament was released in all three of our cases, but a pericardial incision around the inferior vein was needed only in Case 3. We prefer to use absorbable suture materials for our tracheal and bronchial anastomoses. Furthermore, we used interrupted sutures for the end-to-end anastomosis since we believe this is safer. In order to be faster, we also used continuous suturing because the orotracheal tube used for ventilation was leaking air from the side orifice, and ventilation of the right lung was causing difficulties.

A mediastinoscopy may be helpful for evaluating the lymph nodes, directly observing the tracheal invasion of the tumor, and also releasing the anterior pretracheal plane and decreasing the tension on the anastomoses.^[5] We preferred a right thoracotomy in our cases since this is our standard approach. A median sternotomy may alternatively be performed, but it requires mobilization of the great vessels with which we are less familiar.

Complication rates of between 29% and 49% after carinal resection and reconstruction have been reported in the literature.^[6,7] Most of these complications are related to the anastomosis site and are likely affected by the surgical technique.^[7,8] In our cases, we did not need to cover the anastomosis by a viable tissue (intercostal muscle or pleura) because we believe that the mediastinal fatty tissue is a natural coverage for the anastomosis in the middle mediastinum. In most of the similar series in the literature, covering the anastomosis after carinal reconstructions was not suggested,^[4,5,8,9] and we also never cover the anastomosis after a sleeve lobectomy in our practice. We believe that the two key factors for postoperative success are performing careful but limited tissue dissection and decreasing the tension on the anastomosis, and we have not experienced any complications related to our technique.

In conclusion, we believe that tumors that invade that tracheal carina can be safely resected. Careful dissection, manipulation, and selection of the appropriate reconstructive method are all vitally important for ensuring a successful outcome.

Declaration of conflicting interests

The authors declared no conflicts of interest with respect to the authorship and/or publication of this article.

Funding

The authors received no financial support for the research and/or authorship of this article.

REFERENCES

1. Barclay RS, McSwan N, Welsh TM. Tracheal reconstruction without the use of grafts. *Thorax* 1957;12:177-80.
2. Mathey J, Binet JP, Galey JJ, Evrard C, Lemoine G, Denis B. Tracheal and tracheobronchial resections; technique and results in 20 cases. *J Thorac Cardiovasc Surg* 1966;51:1-13.
3. Yamamoto K, Miyamoto Y, Ohsumi A, Imanishi N, Kojima F. Surgical results of carinal reconstruction: an alternative technique for tumors involving the tracheal carina. *Ann Thorac Surg* 2007;84:216-20.
4. Di Rienzo G, Go T, Macchiarini P. Simplified anastomotic technique for end-to-side bronchial reimplantation onto the trachea or contralateral main bronchus after complex tracheobronchial resections. *J Thorac Cardiovasc Surg* 2002;124:632-5.
5. Mitchell JD, Mathisen DJ, Wright CD, Wain JC, Donahue DM, Allan JS, et al. Resection for bronchogenic carcinoma involving the carina: long-term results and effect of nodal status on outcome. *J Thorac Cardiovasc Surg* 2001;121:465-71.
6. Grillo HC. Carinal reconstruction. *Ann Thorac Surg* 1982;34:356-73.
7. Jiang F, Xu L, Yuan F, Huang J, Lu X, Zhang Z. Carinal resection and reconstruction in surgical treatment of bronchogenic carcinoma with carinal involvement. *J Thorac Oncol* 2009;4:1375-9.
8. Mitchell JD, Mathisen DJ, Wright CD, Wain JC, Donahue DM, Moncure AC, et al. Clinical experience with carinal resection. *J Thorac Cardiovasc Surg* 1999;117:39-52.
9. Macchiarini P, Altmayer M, Go T, Walles T, Schulze K, Wildfang I, et al. Technical innovations of carinal resection for nonsmall-cell lung cancer. *Ann Thorac Surg* 2006;82:1989-97.