

Diaphragmatic hydatid cyst: report of three cases

Diyafragmatik kist hidatik: Üç olgu sunumu

Yener Aydın,¹ Mesut Özgökçe,² Muhammet Emin Naldan,³ Atıla Türkyılmaz,¹ Atilla Eroğlu¹

Institution where the research was done:

Departments of Thoracic Surgery, Medical Faculty of Atatürk University, Erzurum, Turkey

Author Affiliations:

Departments of ¹Thoracic Surgery, ²Radiology and ³Anesthesiology and Reanimation,
Medical Faculty of Atatürk University, Erzurum, Turkey

The incidence of diaphragmatic hydatid cysts, isolated or involving other organs, is very rare. Preoperative diagnosis of complicated hydatid cysts located at the diaphragm is challenging. In some cases with a liver cyst the cyst cannot be detected during laparotomy. In this article, we report three diaphragmatic cyst cases who were treated surgically in our clinic within the past 10 years. Cystectomy and primary diaphragm repair using posterolateral thoracotomy were applied to all three cases with an intraoperative diagnosis. There was a ruptured diaphragmatic cyst in only one case, while other cysts were intact and located in multiple organs. A preoperative diagnosis of diaphragmatic hydatid cysts is difficult, and standard treatment is surgery for all intrathoracic hydatid cyst cases.

Key words: Diaphragm; hydatid cyst; surgery.

An isolated diaphragmatic cyst that does not involve the liver or lung is quite rare, with diaphragmatic invasion being seen in only 1% of all liver cysts.^[1] The diagnosis can occur incidentally, and it may resemble lung or liver cysts on computed tomography (CT). However, it has been reported that during a laparotomy, these cysts might not be detected in some patients who were diagnosed preoperatively with a liver cyst.^[2] In this study, three patients with diaphragmatic hydatid cysts are presented along with a review of the literature.

İzole veya diğer organ tutulumları ile birlikte olan diyafragma kist hidatiklerinin görülme sıklığı çok nadirdir. Diyaframda yerleşmiş olan komplike kist hidatiklerde ameliyat öncesi tanıda zorluklar yaşanabilmektedir. Karaciğer kisti olan bazı olgularda, laparotomi sırasında kist tespit edilememektedir. Bu yazıda kliniğimizde son 10 yıl içinde cerrahi tedavi uygulanan üç diyafragmatik kist olgusu sunuldu. Ameliyat sırasında tanı konan her üç olguya da posterolateral torakotomi ile kistektomi ve primer diyafram tamiri uygulandı. Yalnızca bir olguda rüptüre diafragmatik kist mevcut iken, diğer olgularda kistler sağlam ve çoklu organ yerleşimli idi. Diyafragmatik kist hidatiklerin ameliyat öncesi tanısı zor olup, standart tedavisi tüm toraks içi kist hidatik olgularında olduğu gibi cerrahidir.

Anahtar sözcükler: Diyafram; kist hidatik; cerrahi.

CASE REPORTS

The first case involved a 65-year-old female who had undergone surgery for a liver hydatid cyst three years earlier. Her posteroanterior (PA) chest X-ray was normal. However, CT detected a homogeneous cystic lesion with relatively smooth borders on the lateral side of the diaphragm which matched the localization of the anterior basal segment at the lower lobe of the right lung. Furthermore, it showed border discrimination with the liver (Figure 1). A pulmonary hydatid cyst was diagnosed, and the decision was made to operate.



Available online at
www.tgkdc.dergisi.org
doi: 10.5606/tgkdc.dergisi.2014.6285
QR (Quick Response) Code

Received: November 29, 2011 *Accepted:* May 14, 2012

Correspondence: Yener Aydın, M.D. Atatürk Üniversitesi Tıp Fakültesi Göğüs Cerrahisi Anabilim Dalı, 25240 Erzurum, Turkey.

Tel: +90 535 - 784 89 70 e-mail: dryeneraydin@hotmail.com

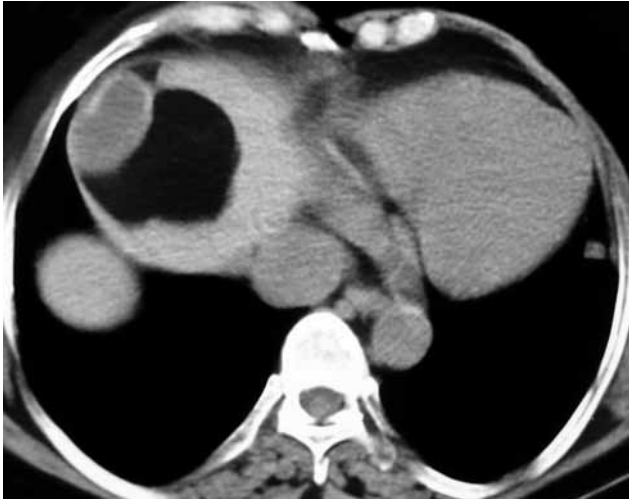

Figure 1. Computed tomographic image of the first case showing the homogeneous, smooth-bordered cystic lesion at the lateral portion of the diaphragm. Separation from the liver border at the localization was achieved correspondent to the anterior basal segment of the lower right lung.

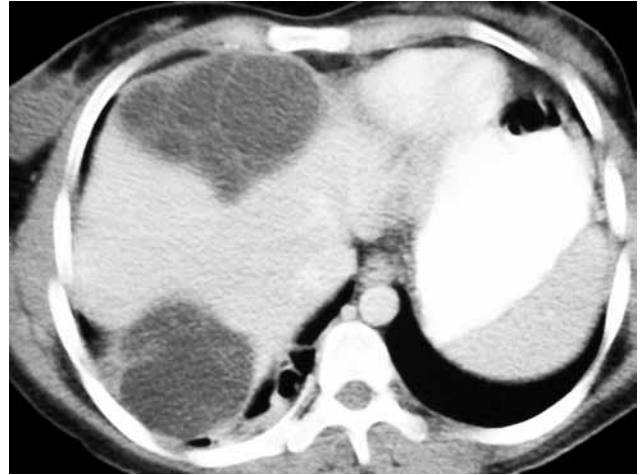


Figure 2. Computed tomographic image of the second case showing the multiloculated, hypodense, smooth-bordered cystic appearance at the fourth and eighth segments of the liver. No distinction could be made between the exophytic, septated, hypodense, smooth-bordered cystic area at the border and the liver since it was situated at posteriorly. It also shows the atelectatic area at the posterior segment of the lower lobe of the right lung.

The thorax was entered through the seventh intercostal space via a right posterolateral thoracotomy, and the muscle fibers of the diaphragm were split, revealing three hydatid cysts. One measured 4x5 cm in diameter and two others measured 1 cm.

In the second case, CT revealed multiple cystic lesions in the upper and lower lobes of the lungs

of a 25-year-old female. In addition, a smooth-bordered, multiloculated, hypodense cyst was present at the fourth and eighth segments of the liver together with atelectasis of the adjacent lung parenchyma. Furthermore, there was a well-defined border in the hypodense septated cystic area that

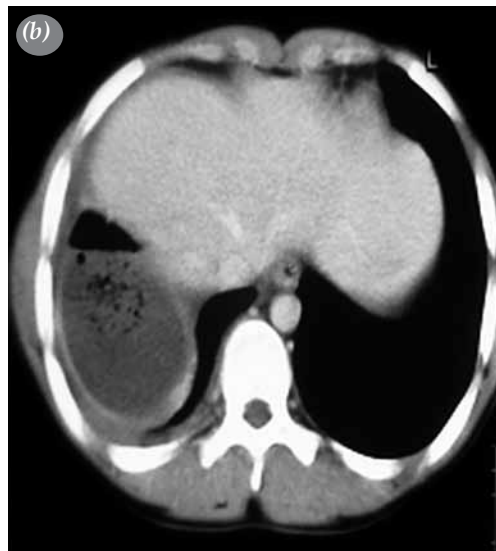
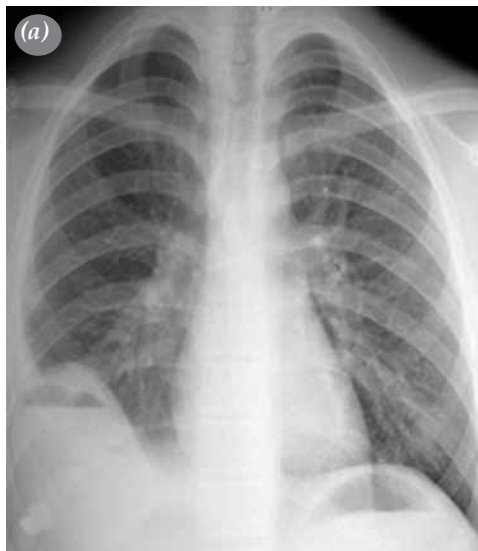

Figure 3. (a) Direct posteroanterior lung X-ray of the third case showing the air-fluid level. The right diaphragm contours are erased. **(b)** Computed tomographic image of the third case showing a lesion measuring approximately 8 cm in diameter at the posterobasal portion of the lower lobe of the right lung along with thick-walled abscesses containing internal air densities and the air-fluid level. Minimal pleural effusion is present where the right diaphragm contour was erased.

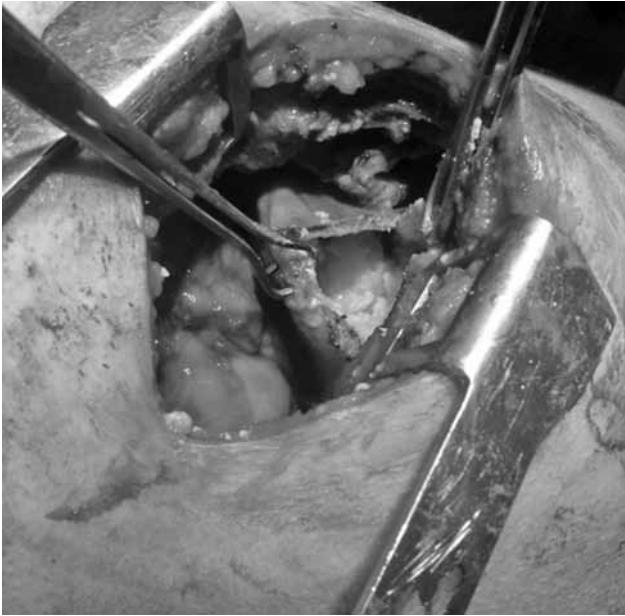

Figure 4. Operative view of the third case showing the diaphragmatic rupture of the hydatid cyst.

showed exophytic elongation. Moreover, no distinction could be made between the posterior border and the liver in this patient (Figure 2).

In the third case, a physical examination of a 16-year-old male with consolidation at the right costophrenic sinus and decreased breathing sounds at the base of the right lung. A posteroanterior chest X-ray contour of the diaphragm was blunted so that the air fluid level could be seen (Figure 3a), and CT revealed a 8 cm lesion. This lesion was thought to be a thick-walled abscess that was also detected which contained internal air densities as well as an air-fluid level at the posterobasal portion of the right lower lobe (Figure 3b). The decision to operate was made

because the evidence suggested a ruptured pulmonary hydatid cyst. The thorax was entered through the sixth intercostal space via a right posterolateral thoracotomy, which revealed a ruptured hydatid cyst that had settled on the diaphragm. Thus, a cystotomy was performed, and the cyst membranes were removed (Figure 4).

The cyst membranes were also extracted in the other two cases, and the defects at the diaphragm were primarily repaired using silk (no: 0) sutures (Table 1). The patients had no postoperative complications during follow-up, and the mean discharge time was postoperative day seven (5-10 days). All medical treatments were completed after 30 days (3-10 day intervals) and each of the patients was started on 800 mg of albendazole per day. The patients were also evaluated using a liver function test, and the first and third cases underwent a hemogram at the postoperative 15th day. The second case was referred to the general surgery outpatient clinic. After an average of 43 months of follow-up (22-65 months), no recurrences had been detected.

DISCUSSION

The involvement of the diaphragm in thoracic hydatid cysts is quite rare, with most cases being related to liver cysts. In addition, there have been only a few reports of primary diaphragmatic hydatid cysts without lung or liver involvement in the literature.^[2] In one of our cases, an isolated diaphragmatic cyst was diagnosed.

As seen in two of our patients, side pain is a common occurrence when the clinical symptoms are similar to those of diaphragmatic cysts, but cough and dyspnea can also occur.^[2] Furthermore, fever and pneumonia can be present when the cyst is perforated, as was the case with our three patients.

Diagnosis of diaphragmatic hydatid cyst is possible in some cases via precise, preoperative topographic

Table 1. Patient characteristics

	Case 1	Case 2	Case 3
Age (years)	65	25	16
Sex	Female	Female	Male
Symptoms	Right side pain, back pain, emesis, vomiting, and swelling	Abdominal pain, emesis, vomiting, and dyspnea	Chest pain, fever, and cough
Hydatid cysts in other organs	Liver	Lung and liver	No
Localization	Laterally	Everywhere	Costophrenic sinus
Number of diaphragmatic cysts	Three	Eight	One
Approach	Seventh intercostal space	Seventh intercostal space	Sixth intercostal space
Hydatid cyst size	4x5 cm	10x10 cm	8x5 cm
Feature of the diaphragmatic cyst	Intact	Intact	Ruptured
Resection of the diaphragm	No	No	No
Recurrence	No	No	No

research of the lung, liver, diaphragm, and other abdominal organs. In addition, ultrasonography (USG), CT, and magnetic resonance imaging (MRI) can be used in conjunction with chest radiography to detect the localization of a hydatid cyst that has settled in the thorax. However, this becomes more complicated when the hydatid cyst is perforated. In addition, patients can sometimes be affected by benign and malignant diseases such as tumor metastasis, abscesses, emphysema, and infarcts caused by the enhancement of variable radiological images.^[1] Kabiri et al.^[3] reported an accurate diagnosis ratio of 82% when abdominal echocardiography and thoracic CT were used in a study involving 27 diaphragmatic hydatid cysts. Detecting cysts that have settled in the diaphragm is usually difficult; therefore most of these cases are diagnosed during surgery. For example, many patients have undergone operations with a preoperative diagnosis of liver or lung cysts, but a diaphragmatic hydatid cyst was found during the surgical procedure.^[2] In our study, a preoperative radiological study indicated a lung cyst in the first and third cases and a liver cyst in the second, but surgery revealed the presence of a diaphragmatic cyst in all three patients.

It is thought that hydatid cysts reach the diaphragm when perforation of the cysts occurs in the lungs, liver dome, and diaphragm, but this hypothesis has been difficult to prove in clinical and experimental studies. Interestingly, Işıtmangil et al.^[4] noted that intrathoracic extrapulmonary hydatid cyst disease arises from lymphatic drainage from the diaphragm.

Spontaneous rupture of a diaphragmatic hydatid cyst is quite rare, and there have been only two reported cases in the literature.^[3] However, one of our

cases was a spontaneous rupture, making it the third reported case.

The best treatment modality for diaphragmatic hydatid cysts is surgery, the usual recommendation for cases involving intrathoracic hydatid cysts, and the preferred procedure is a thoracotomy, which we performed in all three of these cases.

In conclusion, a hydatid cyst that has settled at the diaphragm is rare, and preoperative diagnosis can be difficult. The only definitive treatment is surgery, with the best exposure being achieved via a thoracotomy.

Declaration of conflicting interests

The authors declared no conflicts of interest with respect to the authorship and/or publication of this article.

Funding

The authors received no financial support for the research and/or authorship of this article.

REFERENCES

1. Meteroglu F, Isık AF, Elbeyli L. Complicated diaphragmatic cyst hydatid having difficulty in diagnosis: two cases. *Dicle Medical Journal* 2010;37:294-6.
2. Ücvet A, Tözüm H, Kul C, Özsinan F, Gürsoy S, Yıldız S. Primary diaphragmatic hydatid cyst. *Archives of Lung* 2007;8:71-3.
3. Kabiri H, Al Aziz S, El Maslout A, Benosman A. Diaphragmatic hydatidosis: Report of a series of 27 cases. *Rev Pneumol Clin* 2001;57:13-9. [Abstract]
4. Isitmangil T, Toker A, Sebit S, Erdik O, Tunc H, Gorur R. A novel terminology and dissemination theory for a subgroup of intrathoracic extrapulmonary hydatid cysts. *Med Hypotheses* 2003;61:68-71.