

## An unusual presentation of a cardiac papillary fibroelastoma: a case report

*Nadir yerleşimli kardiyak papiller fibroelastom tablosu: Olgu sunumu*

Kürşad Öz,<sup>1</sup> İbrahim Faruk Aktürk,<sup>2</sup> Mustafa Özer Ulukan,<sup>3</sup> Burak Ersoy,<sup>1</sup> Ersin Ereğli<sup>1</sup>

*Institution where the research was done:*

Departments of Cardiovascular Surgery, Mehmet Akif Ersoy Training and Research Hospital, İstanbul, Turkey

*Author Affiliations:*

Departments of <sup>1</sup>Cardiovascular Surgery, <sup>2</sup>Cardiology, Mehmet Akif Ersoy Training and Research Hospital, İstanbul, Turkey

<sup>3</sup>Departments of Cardiovascular Surgery, Gaziosmanpaşa Taksim Training and Research Hospital, İstanbul, Turkey

In this article, we report an uncommon case of cardiac fibroelastoma originating from the left atrial septum. The mass moved from the mitral valve through the left ventricle in each atrial systole. However, the patient was free of any cardiac or cerebral symptom. Based on the echocardiographic findings, the mass was considered the left atrial myxoma and the patient was primarily scheduled for surgery. The mass which adhered to the left atrial septum was excised with the septum. Surgical septal defect was closed with an autologous pericardial patch. Intraoperative transesophageal echocardiography revealed no residual mass with a normal mitral valve function. The definitive diagnosis is made by histopathological examination. Papillary fibroelastomas originating from septum are extremely rare, but have high-risk for cerebrovascular embolism due to their location. Despite histopathologically benign nature, early diagnosis and treatment is of utmost importance due to fatal complication risks.

**Keywords:** Atrial septum; cardiac tumor; papillary fibroelastoma.

Cardiac papillary fibroelastomas (CPFs) are rare tumors that predominantly originate from the heart valves and occur at a rate of 0.28%. They are the third most common primary cardiac tumors (8-10%) behind myxomas and lipomas,<sup>[1,2]</sup> but seldom is there involvement of the interatrial septum. Although CPFs are benign in nature, they can cause severe thromboembolic complications regardless of the size of the tumor.<sup>[3]</sup> These small

Bu çalışmada atriyal septumun sol tarafından köken alan ender görülen kardiyak fibroelastom olgusu sunuldu. Bu kitle her atriyal sistolde mitral kapaktan sol ventriküle doğru hareketliydi. Ancak, hastada herhangi kardiyak veya serebral semptom yoktu. Ekokardiyografik bulgulara göre kitle sol atriyal miksona olarak kabul edildi ve hastaya öncelikli olarak ameliyat planlandı. Sol atriyal septuma yapışık olan kitle, septum ile birlikte eksize edildi. Cerrahi olarak oluşan septal defekt, otolog perikardiyal yama ile kapatıldı. Ameliyat sırası çekilen transözofageal ekokardiyografide artık kitle saptanmadı ve mitral kapak fonksiyonu normaldi. Kesin tanı histopatolojik inceleme ile kondu. Septumdan köken alan papiller fibroelastomalar oldukça nadir görülür, ancak yerleşim yeri nedeniyle serebrovasküler emboli açısından yüksek risklidir. Histopatolojik olarak benign karakterde olmasına rağmen, fatal komplikasyon risklerinden dolayı erken tanı ve tedavi çok önemlidir.

**Anahtar sözcükler:** Atriyal septum; kardiyak tümör, papiller fibroelastom.

lesions are usually identified on an echocardiogram by their pediculated, multilobulated appearance which resembles an anemone in water, and they can be accurately diagnosed via a histopathological examination.<sup>[4]</sup> These tumors are generally benign; however, they present with a wide variety of symptoms and may be associated with strokes or transient ischemic attacks due to a cerebral embolism.<sup>[5]</sup>

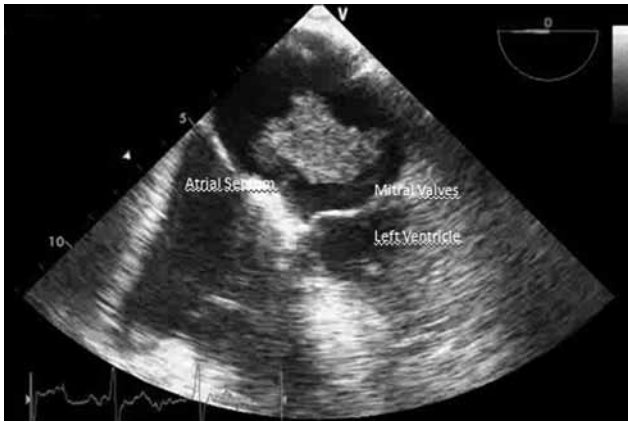

Available online at  
www.tgkdc.dergisi.org  
doi: 10.5606/tgkdc.dergisi.2014.9549  
QR (Quick Response) Code

Received: November 19, 2013 Accepted: February 17, 2014

Correspondence: Kürşad Öz, M.D. Mehmet Akif Ersoy Eğitim Araştırma Hastanesi, Kalp ve Damar Cerrahisi Kliniği, 34303 Küçükçekmece, İstanbul, Turkey.

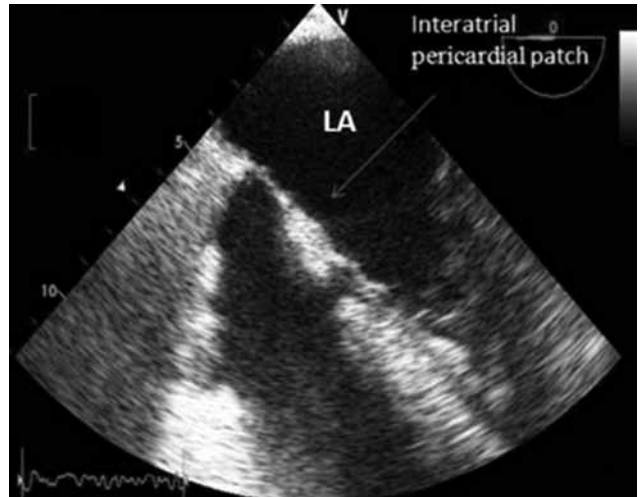
Tel: +90 212 - 692 20 00 e-mail: drkursadoz@gmail.com



**Figure 1.** Intracardiac mass adhering to the left interatrial septum.

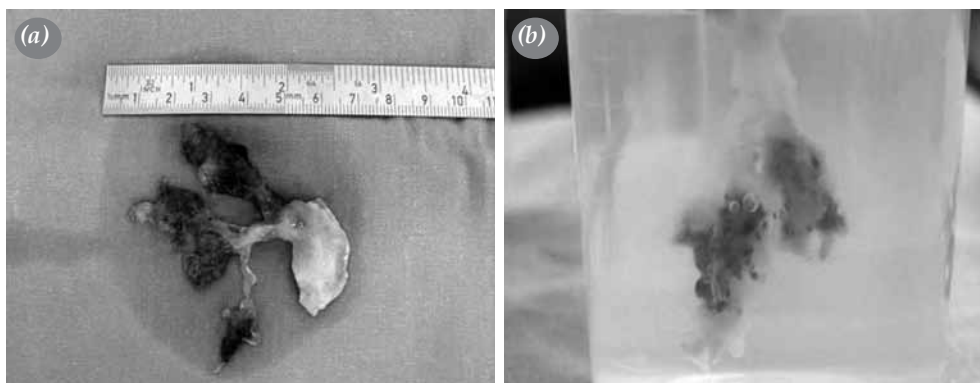
### CASE REPORT

A 74-year-old male was referred to our hospital with an unclear, left-sided intracardiac mass. In his history, he had no specified neurological symptoms such as headaches, vertigo, paresia, or plegia, but he did have hypertension. At his cardiac examination, the patient was in sinus rhythm and had a 2/6 systolic murmur in the mitral auscultation area. An electrocardiogram showed normal sinus rhythm at a rate of 80 beats/minute. Transthoracic echocardiography (TTE) and transesophageal echocardiography (TEE) revealed multiple mobile masses originating from the atrial septum and moving toward the left ventricle through the mitral valve at each atrial systole (Figure 1). However, the inflammation markers were negative, and his physical examination and laboratory tests of other systems were normal. Based on the echocardiographic findings, an urgent operation was planned. This surgery was managed by standard cardiopulmonary bypass (CPB) with aortic and

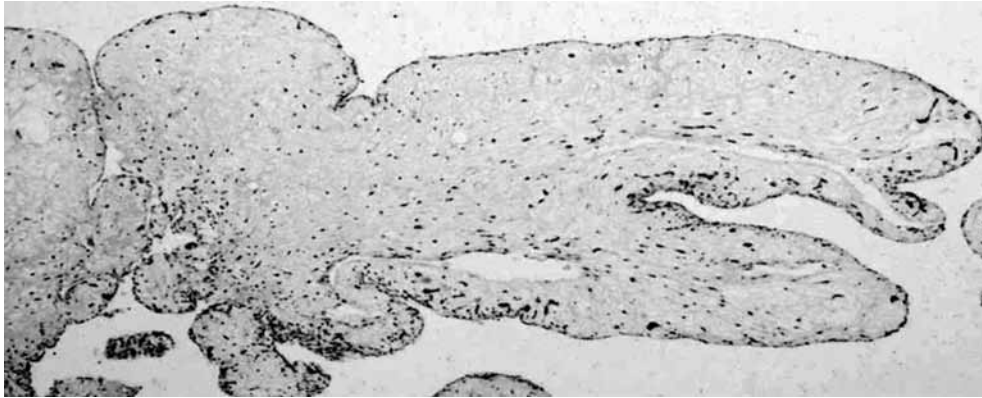


**Figure 2.** Appearance of the interatrial pericardial patch (postoperative image).

bicaval venous cannulation after performing a median sternotomy. In addition, antegrade cardioplegia was used for myocardial protection. A right atriotomy was performed, and the left atrium was then reached via a transeptal incision. The tumor was adhering to the left side of the atrial septum and was completely removed with together interatrial septum. The surgically created atrial septal defect (ASD) measured approximately 20x25 mm and was closed with an autologous pericardial patch. Perioperative TEE confirmed the presence of normal valvular functions, and no residual left atrial mass was seen (Figure 2). The patient's intracardiac tumor measured 65x50x55 mm and was pediculated and multilobulated outside of the water but looked like an anemone or “windflower” inside the water (Figure 3a, b). The histopathological examination demonstrated that the CPF contained a papillary proliferation along with a



**Figure 3.** (a) Macroscopic appearance of the pediculated, multilobulated intracardiac mass shown outside the water. (b) It measured 65x50x55 mm and had the appearance of an anemone, or “windflower” inside the water.



**Figure 4.** The papillary fibroelastoma contains a papillary proliferation that includes a central eosinophilic fibroelastic stroma and a paler myxomatous matrix covered by endothelial cells (H-E x 100).

few fibroblasts and collagenous tissue. Furthermore, it was covered with endothelial cells (Figure 4).

On the third postoperative day, the atrial fibrillation (AF) should be resolved, and normal sinus rhythm was restored after infusion of amiodarone. The patient was then discharged from hospital on the seventh postoperative day without any neurological or cardiac complications.

## DISCUSSION

Cardiac papillary fibroelastomas are most often diagnosed sporadically at the time of cardiac disease investigations or autopsies. The incidence rate for them is ambiguous because most patients are asymptomatic. The reported frequency of CPFs in one autopsy series was 0.0017-0.33%, with most of the tumors affecting the heart valves.<sup>[1]</sup> Cardiac papillary fibroelastomas usually occur on the aortic and mitral valves but can sometimes be found on the tricuspid and pulmonary valves. When the mitral valve is involved, the tumors are most often on the atrial mid-portion of the heart. In these situations, the clinician may be confused as to whether a patient has an organized mobile thrombus, pediculated myxoma, or fibroelastoma.<sup>[2,6]</sup>

Although the left ventricle is mostly involved as a nonvalvular tumor location, atrial septal involvement is very rare. In the largest retrospective series (n=725) undertaken so far, a histopathological examination of extravalvular sites diagnosed CPFs at the left ventricle at a rate of 0.752% while the rates were 0.013% and 0.011% at the left atrium and interatrial septum, respectively. In addition, the right ventricle contained CPFs at rate of 0.012% while they were found at the low rate of 0.002% at both the eustachian valve and left atrial appendage.<sup>[7]</sup>

Cardiac papillary fibroelastomas are often reported in conjunction with cerebrovascular accidents; however, the clinical presentation is also related to the part of the cardiac structure that has the tumor involvement. Mitral valve tumors are also associated with cerebrovascular accidents, whereas aortic valve tumors may be affiliated with myocardial infarction and sudden death.<sup>[8,9]</sup> In our case, the mobile CPF was moving toward the left ventricle in each atrial systole, so the patient had a higher risk of systemic embolization or even sudden cardiac death.

With regard to the echocardiographical image and anatomic localization of our patient, the left atrial mass was at first thought to be an atrial myxoma. However, after the surgical excision of the mass, it did not resemble this type of tumor macroscopically, and an accurate diagnosis took place after the histopathological examination.

A recent study proposed that CPFs may be related to a chronic form of viral endocarditis based on the presence of dendritic cells and cytomegalovirus in some patients. However, the histochemical presence of fibrin, hyaluronic acid, and laminated elastic fibers supports the hypothesis that CPFs may be related to organizing thrombi. Immunohistochemical studies have also put forth the idea of virus-induced local growth while theories involving the microthrombus and valve degeneration have suggested that CPFs are acquired not congenital lesions.<sup>[10]</sup>

Left atrial CPFs are extremely rare, histologically benign tumors, but they pose the potential risk of cerebrovascular emboli owing to their anatomical position. Even though many papillary fibroelastomas do not cause symptoms, early diagnosis is still of the utmost importance to prevent patients from fatal

complications. Therefore, both TTE and TEE should be used for diagnosis, and symptomatic patients should undergo surgical excision of the tumor. Our case demonstrates that the clinician may be confronted with various possible diagnoses, and while rare, the possibility of CPFs originating from the left atrial septum should not be disregarded.

Warfarin or antiplatelet therapy may be used in the treatment of small asymptomatic lesions that were diagnosed on echocardiography, and these may be useful for preventing thromboembolic events.<sup>[5]</sup> In addition, some studies have reported that mitral valve CPFs larger than 10 mm in diameter have a higher risk for systemic emboli, but a case of embolization due to a CPF of 3 mm in diameter has also been documented.<sup>[4,5]</sup> Thus, the decision for surgical intervention must be made after careful evaluation. Because of probable complications such as emboli, myocardial ischemia, and sudden death, surgical excision is suggested for larger lesions or for those close to the coronary ostia. In our case, the large tumor presented a high risk of embolization and sudden death, so surgical excision was necessary. To the best of our knowledge, there are no reports that have focused on recurrence rates after the surgical excision of CPFs; hence, follow-up studies should be carried out to address this topic.

#### **Declaration of conflicting interests**

The authors declared no conflicts of interest with respect to the authorship and/or publication of this article.

#### **Funding**

The authors received no financial support for the research and/or authorship of this article.

#### **REFERENCES**

1. Grande AM, Ragni T, Viganò M. Primary cardiac tumors. A clinical experience of 12 years. *Tex Heart Inst J* 1993;20:223-30.
2. Boodhwani M, Veinot JP, Hendry PJ. Surgical approach to cardiac papillary fibroelastomas. *Can J Cardiol* 2007;23:301-2.
3. Ömeroğlu SN, Göksedef D, Balkanay OO, Deşer SB, İkitimur B, Öz B, et al. Papillary fibroelastoma situated in the subvalvular structure of the mitral valve. *Turk Gogus Kalp Dama* 2013;21:232-4.
4. Strecker T, Agaimy A, Marwan M, Zielezinski T. Papillary fibroelastoma of the aortic valve: appearance in echocardiography, computed tomography, and histopathology. *J Heart Valve Dis* 2010;19:812.
5. Kucukarslan N, Oz S, Ulusoy E, Kuralay E., Tatar H. Five-year follow-up of a papillary fibroelastoma involving the mitral valve in a young patient. *Turk Gogus Kalp Dama* 2005;13:354-5.
6. Fayad G, Modine T, Le Tourneau T, Azzaoui R, Decoene C, Copin MC, et al. An unusual case of papillary fibroelastoma “invading” the mitral valve. *J Thorac Cardiovasc Surg* 2006;132:1472-3.
7. Gowda RM, Khan IA, Nair CK, Mehta NJ, Vasavada BC, Sacchi TJ. Cardiac papillary fibroelastoma: a comprehensive analysis of 725 cases. *Am Heart J* 2003;146:404-10.
8. Jain D, Maleszewski JJ, Halushka MK. Benign cardiac tumors and tumorlike conditions. *Ann Diagn Pathol* 2010;14:215-30.
9. Burke A, Jeudy J Jr, Virmani R. Cardiac tumours: an update: Cardiac tumours. *Heart* 2008;94:117-23.
10. Dylan V. Miller. Cardiac Tumors. *Surgical Pathology Clinics*. 2012;5:453-83.