

## Huge mediastinal cystic lesion: a case report

*Dev mediastinal kistik lezyon: Olgu sunumu*

**Amita Yadav, Rajendra Mathur, Sanjeev Devgarha, Viju Abraham, Anula Sisodia**

Department of Cardiothoracic and Vascular Surgery, Sawai Man Singh Medical College and Hospital, Jaipur, India

### ABSTRACT

Thymic cysts are rare, and because most are asymptomatic when small in size, they are usually detected incidentally as unsuspected masses on chest radiographs. In this article, we report a rare case of a huge thymic cystic lesion abutting the major vessels of the mediastinum. Chronic respiratory and cardiac symptoms developed in a patient who presented with a mediastinal cystic mass after which widening of the mediastinal shadow was confirmed on chest radiographs. Thymic cysts should be added to the list of thymic abnormalities that may occur in patients with compressive mediastinal masses, which may be life threatening.

**Keywords:** Anterior mediastinal mass; chest; thymic cyst.

Among the mediastinal cysts, those that are thymic make up between 3 and 28.6% of all reported cases.<sup>[1-3]</sup> These tumors are generally asymptomatic and are usually diagnosed accidentally during a radiological evaluation of the chest for unrelated conditions. In addition, symptoms appear later when the mass exhibits compressive features. In addition, one rare case of a mediastinal thymic cyst mimicking a pericardial cyst has been reported.<sup>[1]</sup> Herein, we present the case of a patient with a large thymic cyst abutting the major vessels of the mediastinum.

### CASE REPORT

A 40-year-old female patient was admitted to our facility with a cough, palpitations, and dyspnea on exertion that had persisted for two months. She had no history of pneumonia or pleural effusion. A preoperative chest radiograph showed a large left anterosuperior mediastinal mass that had been previously described as

### ÖZ

Timik kistler nadirdir ve boyutları küçük iken çoğu asemptomatik olduğundan genellikle göğüs radyografilerinde şüphelenilmeyen kitleler olarak tesadüfen tespit edilirler. Bu yazıda mediastenine ana damarlarına bitişik dev bir timik kistik lezyona ilişkin nadir bir olgu sunuldu. Mediastinal kistik bir kitle ile başvuran hastada kronik solunumsal ve kardiyak semptomlar gelişti, ardından mediastinal gölgenin genişlediği göğüs radyografilerinde teyit edildi. Timik kistler ölümcül olabilen bası yapan mediastinal kitleleri olan hastalarda gelişebilen timik anormallikler listesine eklenmelidir.

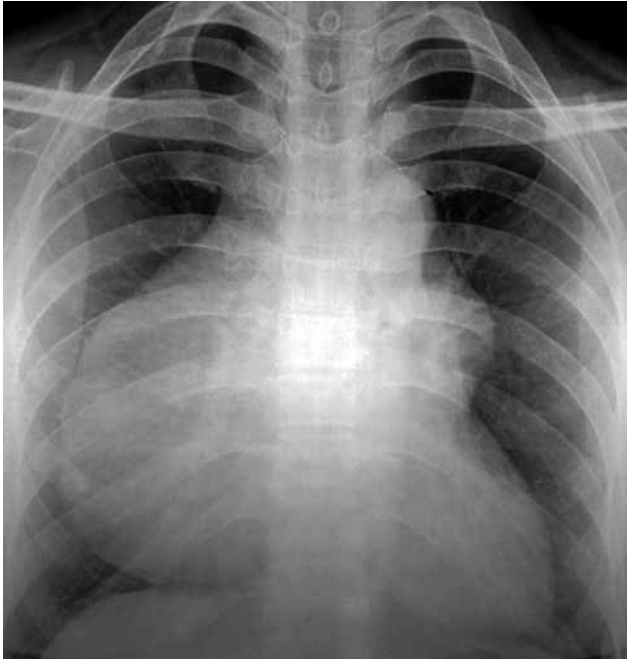**Anahtar sözcükler:** Anterior mediastinal kitle; göğüs; timik kist.

an asymptomatic “pericardial cyst” on a previous chest radiograph. Furthermore, the patient’s family history was non-contributory, and there was no past history of pneumonia and chest pain. Moreover, the patient’s hemodynamic parameters and laboratory data were also within normal limits.

A chest X-ray (Figure 1) showed a homogenous opacity in the anterosuperior mediastinum adjacent to the right heart contour, but the lung transparency and cardiac silhouette were normal. Echocardiography detected an ejection fraction (EF) of 55%, minimal pericardial effusion localized to the right side of heart, normal chamber dimensions, and no regional wall motion abnormalities.

The patient then underwent chest computed tomography (CT) which revealed a cystic lesion in the anterior mediastinum extending from the level of thoracic inlet to the T<sub>10</sub> vertebra. The lesion

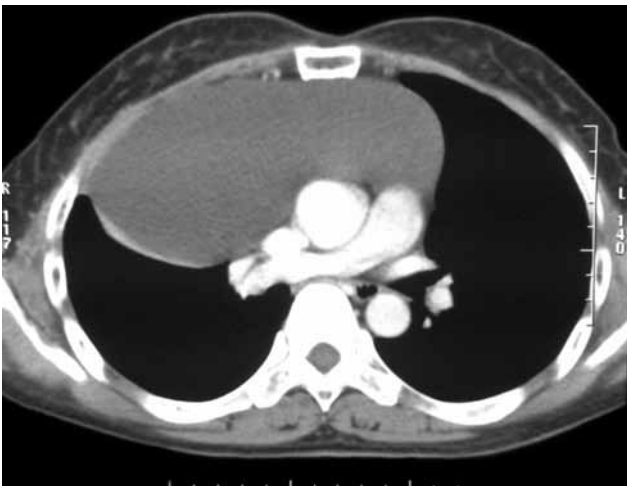




**Figure 1.** A chest X-ray showed a homogenous opacity in the anterosuperior mediastinum.

was abutting the mediastinal vascular structures, anterolateral chest wall, and anterior pericardium via a fat plane, and tiny, discrete foci of fat densities were seen within the lesion. In addition, a curvilinear segment of collapse was visible adjacent to the lateral margin of lesion, but there was no evidence of any abnormal calcification (Figure 2).

A median sternotomy was then performed in order to excise the cyst, and this revealed a huge, elongated cyst



**Figure 2.** Chest computed tomography which revealed a cystic lesion in the anterior mediastinum extending from the level of thoracic inlet to the T<sub>10</sub> vertebra. T.

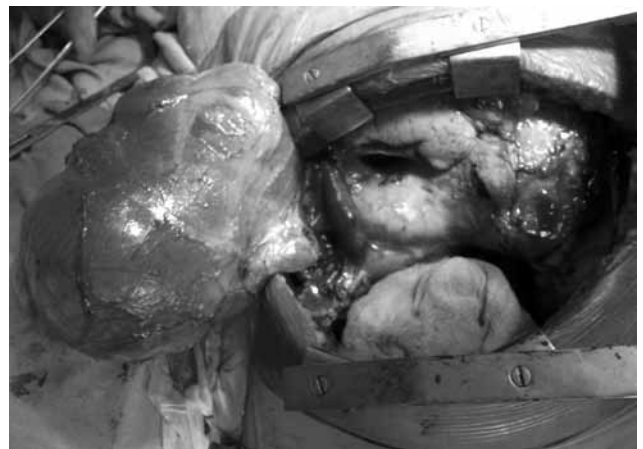with two non-communicating components originating from the thoracic inlet that were attached to the pericardial surface of the mediastinum by adhesions. Furthermore, it was abutting the superior vena cava (SVC) as well as the brachiocephalic, carotid, and subclavian arteries and was also occupying half of the right hemithorax laterally. The patient left the operating room in good condition, and her postoperative recovery was favorable.

On gross appearance (Figure 3), the external surface of the cyst was smooth. Moreover, it contained thin serohemorrhagic fluid and gross amorphous parietal material.

A microscopic examination of the cyst wall indicated that it was composed of a thick layer of hyalinized connective tissue with lymphoid foci and a central skeleton of Hassall's corpuscles and nodular aggregates of foamy cells. There was no epithelial lining focally, and pathological examination revealed two loculations in the resected specimen. A tissue diagnosis of the benign thymic cysts was made because the cyst wall contained thymic lymphoid tissue; however, there was no evidence of malignancy.

## DISCUSSION

In the anterior mediastinum, tumors and cysts of a thymic origin, germ cell tumors, parathyroid adenoma, lymphoma, and intrathoracic goiters are prevalent.<sup>[1]</sup> The thymus develops from the third pharyngeal pouch together with the inferior parathyroid glands at the fifth week of gestation. The developing thymus maintains its close relationship with the parietal pericardium and descends with the pericardium between the 7<sup>th</sup> and 8<sup>th</sup> gestational weeks to assume its characteristic location in the



**Figure 3.** Gross appearance, the external surface of the cyst was smooth.

superior anterior mediastinum anterior to the great vessels.<sup>[4]</sup>

Thymic cysts may be congenital or acquired. Congenital thymic cysts are remnants of the thyropharyngeal ducts and therefore can occur in the neck or mediastinum. These cysts are usually <6 cm in diameter. In addition, they can be uniloculated or multiloculated and have thin walls. However, acquired cysts are multiloculated with variable cyst wall thickness and range in size from 3 to 17 cm.

The common symptoms for thymic cysts are chest pain, dyspnea, and a cough, but hoarseness of voice<sup>[3]</sup> and respiratory distress have been reported in rare cases. In 1897, Loupaltl recorded the presence of the first congenital mediastinal thymic cyst during the necropsy of an 18-year-old woman, and the first incidence in the United States occurred in a report by Spees in 1938 when he discovered a thymic cyst in a 25-year old man during a necropsy.<sup>[7,8]</sup>

The prognosis for thymic cysts is excellent. Total surgical removal is recommended, and no local recurrence have ever been reported. There have also never been, to the best of our knowledge, any reports of malignant degeneration associated with congenital thymic cysts. Nevertheless, a preoperative diagnosis is almost never made. In fact, the actual diagnosis sometimes does not occur until after a pathological examination of the surgical specimen.

### Conclusion

Our case was unusual because of the huge size of the lesion abutting the major vessels of the mediastinum and also because it occupied half of the right hemithorax. In our patient, the radiological and operative findings were able to establish the nature of

the mass to ensure optimal surgical treatment. Even though these cysts are rare, the possibility of their presence should be kept in mind when symptoms similar to our case are present.

### Declaration of conflicting interests

The authors declared no conflicts of interest with respect to the authorship and/or publication of this article.

### Funding

The authors received no financial support for the research and/or authorship of this article.

### REFERENCES

1. Strollo DC, Rosado de Christenson ML, Jett JR. Primary mediastinal tumors. Part 1: tumors of the anterior mediastinum. *Chest* 1997;112:511-22.
2. Esme H, Eren S, Sezer M, Solak O. Primary mediastinal cysts: clinical evaluation and surgical results of 32 cases. *Tex Heart Inst J* 2011;38:371-4.
3. Takeda S, Miyoshi S, Minami M, Ohta M, Masaoka A, Matsuda H. Clinical spectrum of mediastinal cysts. *Chest* 2003;124:125-32.
4. Moore KL, Persaud TV. The pharyngeal apparatus. In: Moore KL, Persaud TVN, editors. *The developing human: Clinically oriented embryology*. 7th ed. Philadelphia: Saunders; 2003. p. 202-40.
5. Krongrad E, Gunnlaugsson GH, Feldt RH, McGoon DC. Mediastinal masses following corrective surgery for congenital heart disease. *Mayo Clin Proc* 1970;45:748-54.
6. Sltzer RA, Mills DS, Baddock SS, Felson B. Mediastinal thymic cyst. *Dis Chest* 1968;53:186-96.
7. Indeglia RA, Shea MA, Grage TB. Congenital cysts of the thymus gland. *Arch Surg* 1967;94:149-52.
8. Speer FD. Thymic cyst: Report of a thymus presenting cysts of three types. *N Y Med Coll Flower Hosp Bull* 1938;1:142-50.