

A unique case of Poland's syndrome associated with Sprengel's deformity and contralateral gynecomastia

Sprengel deformitesi ve kontralateral jinekomastili nadir bir Poland sendromu olgusu

Nurettin Yiyit,¹ Nurettin Noyan,² Serkan Arıbal³

Institution where the research was done:

Gülhane Military Medical Academy Haydarpaşa Training Hospital, İstanbul, Turkey

Author Affiliations:

¹Department of Thoracic Surgery, Gülhane Military Medical Academy Haydarpaşa Training Hospital, İstanbul, Turkey

²Department of Plastic Surgery, Kasımpaşa Military Hospital, İstanbul, Turkey

³Department of Radiology, Aksaz Military Hospital, Muğla, Turkey

A 19-year-old male patient was admitted to our facility due to chest wall and breast asymmetry. Clinical and radiological examinations revealed the absence of the sternocostal head of the right pectoralis major muscle and right serratus anterior muscle, hypoplasia of the right pectoralis minor muscle, an elevated right small scapula, and contralateral gynecomastia (Figures 1a and 2a-c). The right nipple-areola complex (NAC) was also smaller and had a superior localization (Figure 1a). The patient was diagnosed with Poland's syndrome accompanied by Sprengel's deformity and contralateral gynecomastia. A medial dermal NAC pedicle was then used for the gynecomastia repair. The aesthetic result was reasonable, and the patient was fairly satisfied with the results (Figure 1b).

Poland's syndrome is a rare congenital anomaly characterized by the partial or complete absence of the pectoral muscle. It may be accompanied by breast and nipple abnormalities, a paucity of subcutaneous tissue, rib deformity, axillary and pectoral alopecia, and unilateral hand anomalies,^[1] but many additional anomalies, such as Sprengel's deformity (a congenital elevated and small scapula),

may also be present.^[1] Gynecomastia is the benign enlargement of the male breast, and to the best of our knowledge, only one patient with both Poland's syndrome and gynecomastia has been reported in the literature.^[2] However, to the best of our knowledge, our patient was the first to be diagnosed with the combination of Poland's syndrome, Sprengel's

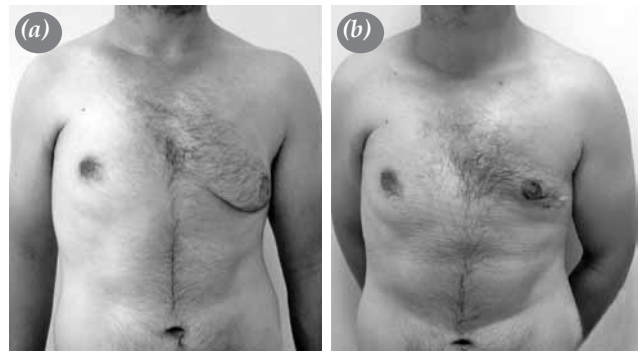

Figure 1. (a) Photograph of the anterior chest wall showing the absence of the sternocostal head of the right pectoralis major muscle along with the left-sided gynecomastia. (b) Photograph of the anterior chest wall after correcting the gynecomastia.



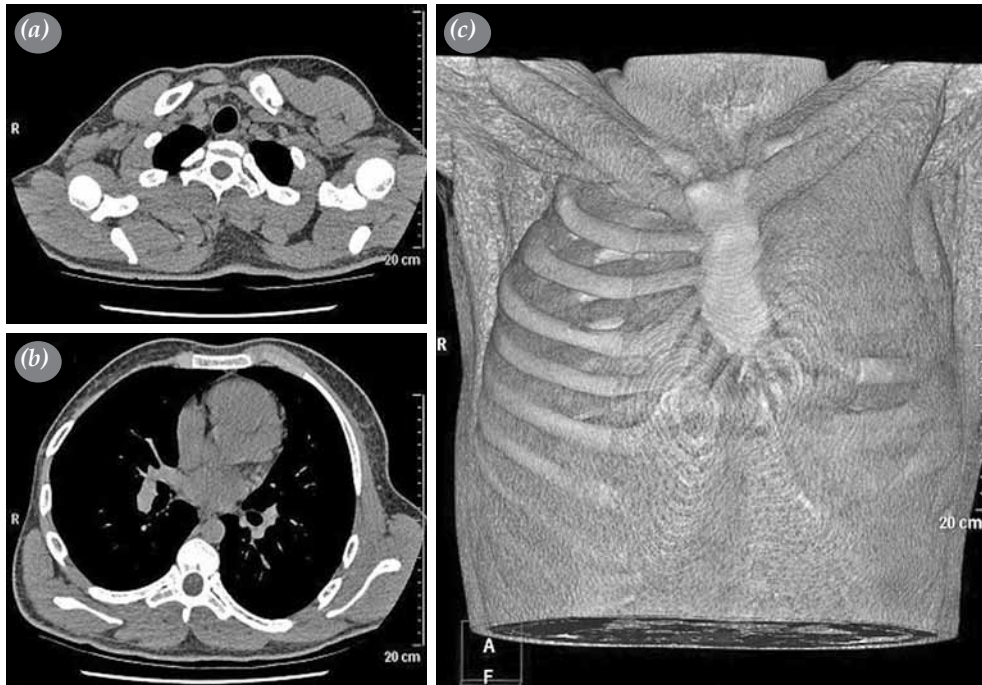


Figure 2. (a) Axial noncontrast-enhanced computed tomography showing the absence of the sternocostal head of the right pectoralis major muscle and the hypoplasia of the right pectoralis minor muscle. (b) Axial noncontrast-enhanced computed tomography showing the absence of the right serratus anterior muscle and the hypoplasia of the right scapula. (c) Three-dimensional volume rendering showing the absence of the sternocostal head of the right pectoralis major muscle along with the absence of the right serratus anterior muscle.

deformity, and gynecomastia. For patients with Poland's syndrome and contralateral gynecomastia, the first treatment modality should be to correct the latter condition.

Declaration of conflicting interests

The authors declared no conflicts of interest with respect to the authorship and/or publication of this article.

Funding

The authors received no financial support for the research and/or authorship of this article.

REFERENCES

1. Fokin AA, Robicsek F. Poland's syndrome revisited. *Ann Thorac Surg* 2002;74:2218-25.
2. Mahoney J, Hynes B. Concurrent Poland's syndrome and gynecomastia: a case report. *Can J Surg* 1990;33:58-60.