

Right-sided levoatriocardinal vein associated with partial anomalous pulmonary venous return

Parsiyel pulmoner venöz dönüş anomalisi ile birliktelik gösteren sağ taraflı levoatriyokardinal ven

Aysel Türkvatın,¹ Adem Kiriş,¹ Pelin Ayyıldız,² Alper Güzeltaş²

Departments of ¹Radiology, ²Cardiology, İstanbul Mehmet Akif Ersoy Thoracic and Cardiovascular Surgery Training and Research Hospital, İstanbul, Turkey

A 2.45-kg female neonate with respiratory distress, feeding difficulty, and growth failure was admitted to our hospital. Transthoracic echocardiography showed hypoplastic left heart syndrome including mitral atresia, aortic valve hypoplasia, hypoplastic left ventricle and aorta, an intact interatrial septum and large patent ductus arteriosus. An abnormal connection between the left atrium and the superior vena cava was demonstrated. Multi-slice computed tomography (MSCT) angiography (Somatom Definition, 256-slice dual source CT, Siemens Medical Systems, Erlangen, Germany) revealed a right-sided levoatriocardinal vein (LACV) connected the superior vena cava and the left atrium via the right

middle pulmonary vein. The right superior pulmonary vein abnormally draining into the LACV was also detected by MSCT (Figure 1). Initially, the patient underwent hybrid stage 1 Norwood procedure.

Levoatriocardinal vein is a very rare congenital anomaly which is an anomalous pulmonary-to-systemic collateral vein connecting the left atrium or one of the pulmonary veins to a systemic vein. In most cases, left-sided obstructive lesions including mitral atresia, hypoplastic left heart syndrome, and cor triatrium are observed and LACV is the only route of communication between two atriums.^[1,2]

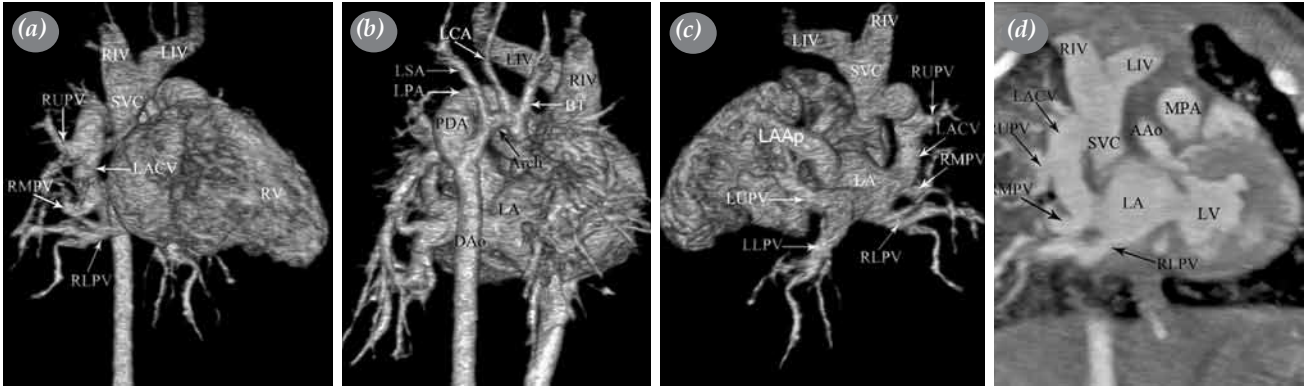


Figure 1. (a) Anterior, (b) posterior and (c) oblique posterior (d) volume rendering and coronal multiplanar re-formatted multi-slice computed tomography angiography images showing a right-sided levoatriocardinal vein connecting the superior vena cava and the left atrium via the right middle pulmonary vein. The right upper pulmonary vein abnormally drains into the levoatriocardinal vein. Hypoplastic ascending aorta and aortic arch and large patent ductus arteriosus between the left pulmonary artery and descending aorta are also shown.

RIV: Right innominate vein; LIV: Left innominate vein; RUPV: Right upper pulmonary vein; SVC: Superior vena cava; RMPV: Right middle pulmonary vein; LACV: Levoatriocardinal vein; RV: Right ventricle; RLPV: Right lower pulmonary vein; LCA: Left carotid artery; LSA: Left subclavian artery; LPA: Left pulmonary artery; PDA: Patent ductus arteriosus; BT: Brachiocephalic trunk; Arch: Aortic arch; LA: Left atrium; DAo: Descending aorta; LAAp: Left atrial appendage; LUPV: Left upper pulmonary vein; LLPV: Left lower pulmonary vein; MPA: Main pulmonary artery; AAo: Ascending aorta; LV: left ventricle.



Available online at
www.tgkdc.dergisi.org
doi: 10.5606/tgkdc.dergisi.2016.11208
QR (Quick Response) Code

Received: November 19, 2014 Accepted: June 11, 2015

Correspondence: Aysel Türkvatın, MD. İstanbul Mehmet Akif Ersoy Göğüs Kalp ve Damar Cerrahisi Eğitim ve Araştırma Hastanesi, 34303 Küçükçekmece, İstanbul, Turkey.

Tel: +90 532 - 591 66 00 e-mail: aturkvatan@yahoo.com

Levoatriocardinal vein is usually located in the left side, originating from the left atrium and draining into the left innominate vein. Right-sided LACV is extremely rare anomaly which was reported only a few cases in the literature.^[3] In recent years, MSCT angiography has become principal imaging modality for the evaluation of thoracic vascular anomalies thanks to its advantages of widespread availability, short acquisition times, high spatial resolution and three-dimensional capability.^[4] It is useful to delineate the origin, course, and drainage site of LACV and to show associated cardiovascular abnormalities.

Declaration of conflicting interests

The authors declared no conflicts of interest with respect to the authorship and/or publication of this article.

Funding

The authors received no financial support for the research and/or authorship of this article.

REFERENCES

1. Bernstein HS, Moore P, Stanger P, Silverman NH. The levoatriocardinal vein: morphology and echocardiographic identification of the pulmonary-systemic connection. *J Am Coll Cardiol* 1995;26:995-1001.
2. Paudel G, Ng BY, Law IH. Hypoplastic left heart with intact atrial septum and levoatriocardinal vein: a challenge in identifying aortic arch branches. *Cardiol Young* 2015;25:171-3.
3. Beitzke A, Mächler H, Stein JI. Mitral atresia with premature closure of the oval foramen, right-sided levoatriocardinal vein and thrombus formation in the left atrium. *Int J Cardiol* 1987;14:221-4.
4. Dyer KT, Hlavacek AM, Meinel FG, De Cecco CN, McQuiston AD, Schoepf UJ, et al. Imaging in congenital pulmonary vein anomalies: the role of computed tomography. *Pediatr Radiol* 2014;44:1158-68.