

An interesting view of diaphragmatic hydatid cyst

Diyaframatik kist hidatiğin ilginç bir görünümü

Yener Aydın,¹ Hayri Oğul,² Bayram Altuntaş,¹ Atilla Eroğlu¹

Departments of ¹Thoracic Surgery, ²Radiology, Medical Faculty of Atatürk University, Erzurum, Turkey

A 26-year-old female patient presented with nausea, anorexia, and vomiting. Posteroanterior chest X-ray showed right diaphragmatic eventration (Figure 1a). Sagittal T₁-weighted magnetic resonance image revealed multicystic lesion in the diaphragm (Figure 1b). In the axial chest computed tomography and coronal T₂-weighted magnetic resonance imaging, multicystic type 3 hydatid cyst was observed along the right hemidiaphragm. Cysts were observed in the left hemidiaphragm extension of the diaphragm (Figure 2a, b). In the axial T₂-weighted magnetic resonance imaging, multiple type 3 hydatid cyst was observed arising from the diaphragm (Figure 2c). The patient underwent a right posterolateral thoracotomy. Hydatid cyst originated from the diaphragm. There was no association with lung and liver (Figure 3a). The cyst membranes were extracted and the defect at the diaphragm was primarily repaired using silk sutures (Figure 3b).

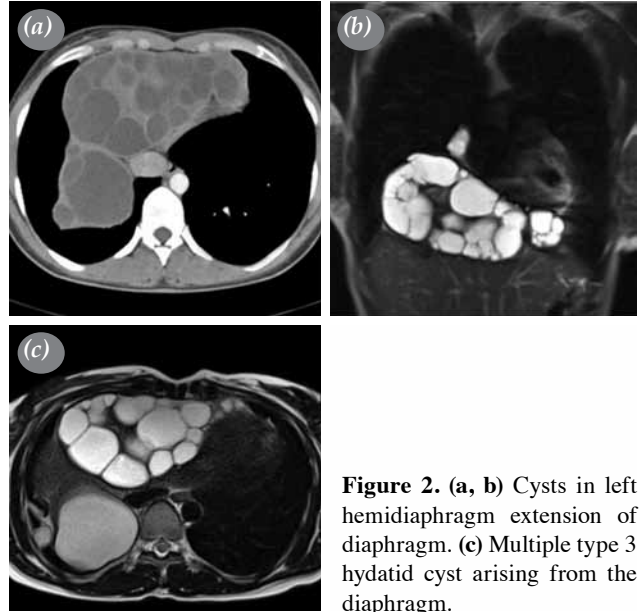


Figure 2. (a, b) Cysts in left hemidiaphragm extension of diaphragm. (c) Multiple type 3 hydatid cyst arising from the diaphragm.

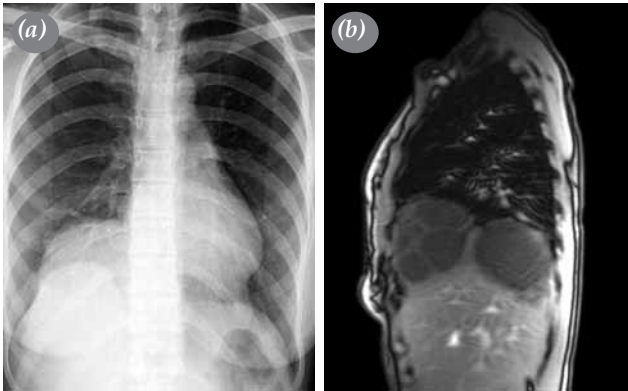


Figure 1. (a) Posteroanterior chest X-ray showing right diaphragmatic eventration. (b) Sagittal T₁-weighted magnetic resonance image revealing multicystic lesion in diaphragm.

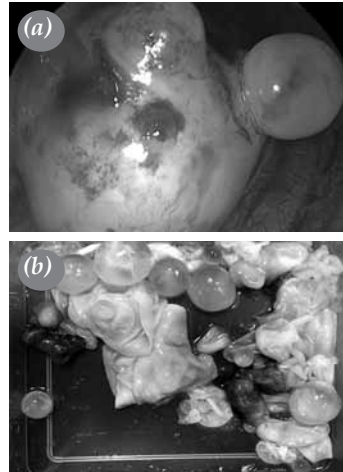


Figure 3. (a) Hydatid cyst originated from the diaphragm. (b) Cyst membranes were extracted and defect at diaphragm was primarily repaired using silk sutures.



Diaphragmatic hydatid cyst is extremely rare. It is seen as particularly associated with hepatic cysts.^[1] Diagnosis of diaphragmatic hydatid cyst is difficult and standard treatment is surgery.

Declaration of conflicting interests

The authors declared no conflicts of interest with respect to the authorship and/or publication of this article.

Funding

The authors received no financial support for the research and/or authorship of this article.

REFERENCES

1. Aydin Y, Ozgokce M, Naldan ME, Turkyilmaz A, Eroglu A. Diaphragmatic hydatid cyst: a report of three cases. Turk Gogus Kalp Dama 2014;22:672-5.