

Surgical management of primary mediastinal hydatid cysts: a 30-year experience

Primer mediastinal kist hidatiklerin cerrahi tedavisi: 30 yıllık deneyim

Atilla Eroğlu, Yener Aydın, Bayram Altuntaş, Ali Bilal Ulaş

Departments of Thoracic Surgery, Medical Faculty of Atatürk University, Erzurum, Turkey

ABSTRACT

Background: This study aims to evaluate the results of a relatively large cohort of patients with primary mediastinal hydatid cysts who were treated with surgery.

Methods: We retrospectively evaluated 24 patients with primary mediastinal hydatid cysts (14 males, 10 females; mean age 32 years; range 11 to 73 years) who were diagnosed between January 1985 and January 2015 and surgically treated in our clinic. Of the patients, nine were performed right thoracotomy, seven were performed left thoracotomy, five were performed video assisted thoracoscopic surgery, and three were performed median sternotomy. The most frequently performed procedure was total cystectomy (n=19, 79.2%). Five patients required cystotomy and partial cystectomy due to dense adhesion to vital structures (20.8%).

Results: One patient developed pleural effusion in the postoperative period. The median duration of hospital stay was 6.5 days (range, 1 to 13 days). Surgical treatment outcomes of cysts were satisfactory. Patients were administered 10 mg/kg/day oral albendazole postoperatively in divided doses twice a day. No morbidity, mortality, or recurrence was observed postoperatively.

Conclusion: Although primary mediastinal hydatid cysts are rare, they should be kept in mind in differential diagnosis of mediastinal cysts particularly in endemic regions. Recently, thoracoscopic treatment of mediastinal hydatid cysts is carried out efficiently and safely.

Keywords: Hydatid cyst; mediastinum; surgery.

ÖZ

Amaç: Bu çalışmada cerrahi ile tedavi edilen primer mediastinal kist hidatikli, nispeten geniş bir hasta grubunun sonuçları değerlendirildi.

Çalışma planı: Ocak 1985 - Ocak 2015 tarihleri arasında tanısı konulan ve kliniğimizde cerrahi olarak tedavi edilen primer mediastinal kist hidatikli 24 hasta (14 erkek, 10 kadın; ort. yaş 32 yıl; dağılım 11-73 yıl) retrospektif olarak değerlendirildi. Hastaların dokuzuna sağ torakotomi, yedisine sol torakotomi, beşine video yardımcı torakoskopik cerrahi, üçüne ise median sternotomi uygulandı. En sık uygulanan işlem total kistektomi idi (n=19, %79.2). Vital yapılara ciddi adezyon nedeni ile beş hastada kistotomi ve parsiyel kistektomi gerekti (%20.8).

Bulgular: Ameliyat sonrası dönemde bir hastada pleural efüzyon gelişti. Medyan hastanede kalış süresi 6.5 gün idi (dağılım, 1-13 gün). Kistlerin cerrahi tedavi sonuçları tatmin edici idi. Ameliyat sonrasında hastalara günde iki kez bölünmüş dozlarda 10 mg/kg/gün oral albendazol verildi. Ameliyat sonrası morbidite, mortalite ve nüks gözlenmedi.

Sonuç: Primer mediastinal kist hidatikler nadir görülmesine rağmen özellikle endemik bölgelerde mediastinal kistlerin ayırıcı tanısında akılda tutulmalıdır. Son zamanlarda mediastinal kist hidatiklerin torakoskopik tedavisi etkili ve güvenli bir şekilde uygulanabilmektedir.

Anahtar sözcükler: Kist hidatik; mediasten; cerrahi.



Hydatid cyst infestation is one of the oldest diseases in humans and animals. Hydatid cyst is a cystic disease caused by the larval form of *Echinococcus granulosus*, with its most common localization being in the liver and lung. Primary mediastinal hydatid cysts are very rare, being noted in less than 1% of thoracic hydatid cysts and less than 0.1% of all localizations.^[1,2]

The pathogenesis of mediastinal localization of hydatid cyst remains controversial. The mechanism of primary mediastinal infection by the parasite is unknown. Hydatid cysts are rarely present in the mediastinum; the parasite localizes in the region after passing the hepatic and pulmonary filters, probably via an arterial branch of the thoracic aorta or via lymphatics.^[3] Contrary to mucosal surfaces, serosal surfaces like pleura or peritoneum constitute a friendly microenvironment for the development of hydatid cysts.^[4] Mediastinal hydatidosis is most commonly secondary to pulmonary infection. Micro rupture, mostly asymptomatic or leakage of echinococcal fluid during surgery may result in mediastinal contamination. Posttraumatic micro rupture of the pulmonary hydatid cyst may also lead to mediastinal seeding.

A review of the literature, which consists of case reports, small case series, and expert opinion, shows that there is little consensus regarding the diagnosis and management. Although there seems to be an agreement regarding some aspects of the treatment, these conclusions are often based on limited data given the rarity of this mediastinal pathology.^[1-3]

Specific controversial issues regarding surgical management include indication for operation, specific procedures performed, and optimal surgical approach (thoracotomy, sternotomy, open/minimally invasive).^[1,4] Therefore, in this study, we aimed to evaluate the results of a cohort of patients with primary mediastinal hydatid cysts who were treated with surgery.

PATIENTS AND METHODS

We retrospectively reviewed our experience with primary mediastinal hydatid cysts treated at the Atatürk University of Medical Faculty over a 30-year period between January 1985 and January 2015. The data were extracted from hospital records. The study was approved by the Faculty Institutional Review Board. The study was conducted in accordance with the principles of the Declaration of Helsinki.

For preoperative evaluation and investigations, patients who were candidates for surgery of the mediastinal cyst underwent a complete history and

physical examination. Investigations performed included chest X-ray, computed tomography (CT), and abdominal ultrasound. Data on preoperative variables, including sex, age, symptoms, location of cyst, size of cyst, type of operative intervention, duration of hospital stay, and postoperative outcomes, were collected. The diagnosis of primary mediastinal hydatid cyst was surgically confirmed in all cases.

A total of 24 patients (14 males; 10 females; mean age 32 years; range 11 to 73 years) underwent surgery for mediastinal hydatid cyst. Seventy five percent of patients were symptomatic (n=18) and the most common symptoms were cough (58.3%), chest pain (50%), and dyspnea (20.8%). Only two patients had been previously operated for lung hydatid cyst. In one patient, a small liver hydatid cyst was detected. Anterior localizations were present in ten patients (41.7%), posterior in nine (37.5%), and middle localizations in five (20.8%). The mean size of the cyst was 6.6 cm (range, 3 to 13.5 cm). Fourteen cysts were intact while 10 were ruptured.

Preoperative workup included X-ray and CT of thorax and abdomen in most patients (Figure 1, 2). Bronchoscopy was performed in two patients (8%) for middle mediastinal cysts and barium swallow examination, and upper endoscopy was performed in five (21%) for posterior mediastinal cysts. Additional workup such as magnetic resonance imaging (MRI), ultrasonography, endobronchial ultrasonography, endoscopic ultrasonography, and echocardiograph were obtained less commonly. In 18 patients, indirect hemagglutination tests were obtained for hydatid cyst and results were positive in six patients (33%). Five cases had eosinophilia (20%).

The approaches utilized included right thoracotomy (n=9), left thoracotomy (n=7) video assisted thoracoscopic surgery (VATS) (n=5), and median sternotomy (n=3). Various operative approaches are summarized in Table 1. The VATS approach was performed in the last five patients. One patient with anterior-superior giant cyst was converted from VATS to mini thoracotomy. There were dense adhesions surrounding the vascular structures. After a needle aspiration of the cyst, the content was immediately removed via cystotomy. Extensive washing of mediastinal cavity was performed with 10% povidone-iodine solution diluted to 50% as a scolicidal agent. The most common procedure performed was total cystectomy in 79.2% of patients (n=19). Five patients required cystotomy and partial cystectomy due to dense adhesions surrounding the vital structures.

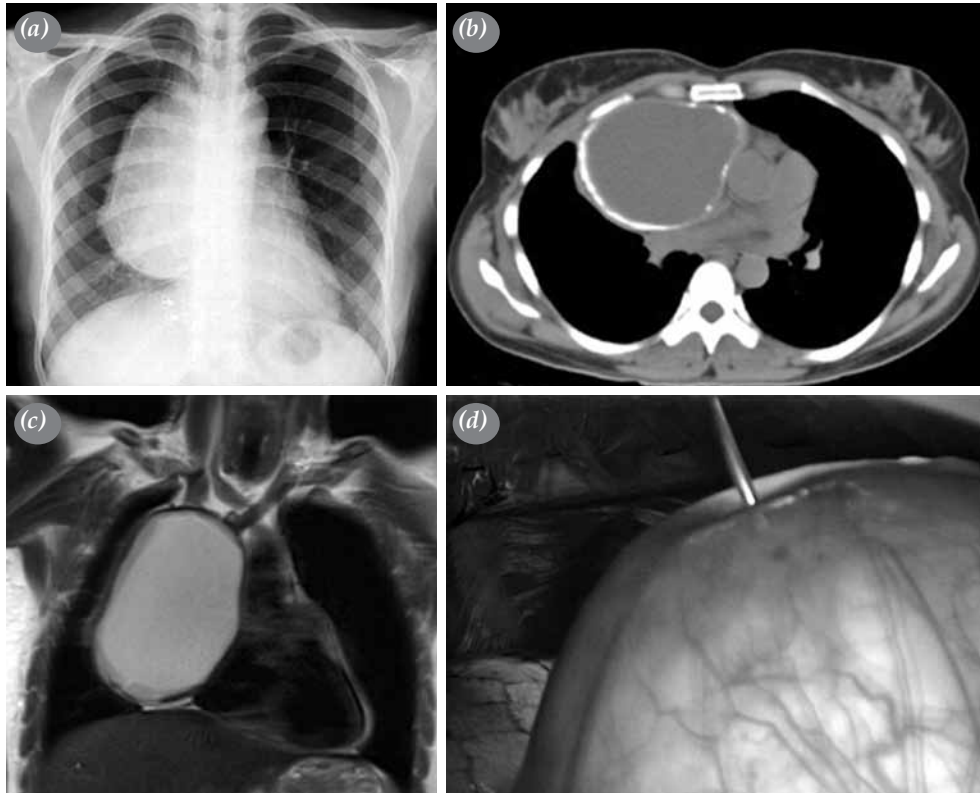


Figure 1. Anterior mediastinal hydatid cyst in a 41-year-old female patient. (a) Chest X-ray and (b) axial tomography of chest show a calcified cystic lesion. (c) Coronal magnetic resonance imaging section shows cystic-mass lesion about 14 cm in diameter. (d) Thoracoscopy shows aspiration of rock water.

RESULTS

One patient developed pleural effusion in the postoperative period. There was no morbidity, mortality, late complications or recurrence postoperatively. The median duration of hospital stay was 6.5 days (range 1 to 13 days). Surgical treatment results of cysts were

satisfactory. Patients were administered 10 mg/kg/day oral albendazole postoperatively in divided doses twice a day for a 28-day cycle followed by a 14-day albendazole-free interval, for a total of three cycles. Post-hospital evaluations were performed every three months during the first year, and annually during the

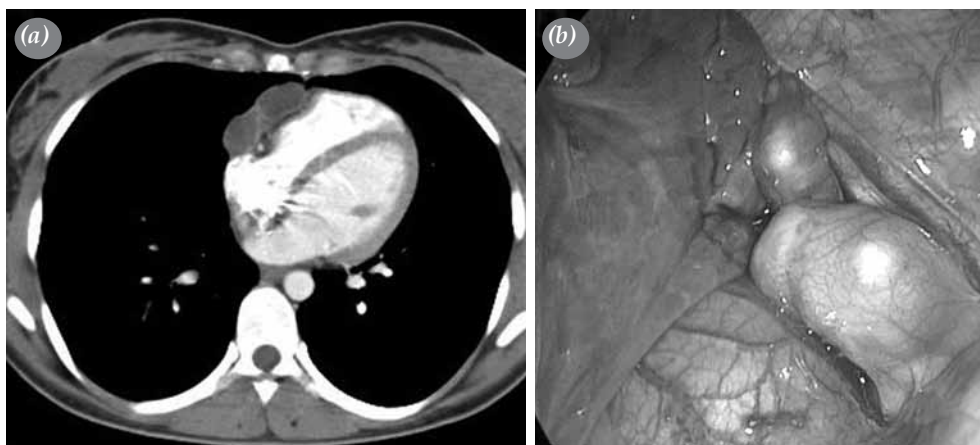


Figure 2. (a) Computed tomography scan shows two cysts located in paracardiac area and (b) their thoracoscopic images.

Table 1. Surgical techniques applied to patients

Features	Anterior-superior		Middle		Posterior	
	n	%	n	%	n	%
Symptomatic	6	60	5	100	7	78
Thoracotomy	5	50	4	80	7	78
Right	3	-	2	-	4	-
Left	2	-	2	-	3	-
Video assisted thoracoscopic surgery	2	20	1	20	2	22
Right	1	-	1	-	2	-
Left	1	-	-	-	-	-
Sternotomy	3	30	-	-	-	-
Partial	2	-	-	-	-	-
Total	1	-	-	-	-	-
Total pericystectomy	8	80	3	60	8	89
Partial pericystectomy	2	-	2	-	1	-
Total	10	-	5	-	9	-

following period. The standard was to obtain an X-ray image during each visit.

DISCUSSION

Hydatid disease still remains an important health problem in developing countries such as Turkey.^[5,6] Turkey is an endemic area for hydatid cysts. Mediastinal hydatid cysts form only 0.1% of all hydatid cysts.^[1,2,7] In our clinic, 804 patients with thoracic hydatid disease were treated surgically in a 30-year period and of these, only 24 patients had primary mediastinal hydatid cyst (3%). Hydatid cysts are usually seen in anterior or posterior mediastinum. Middle mediastinal localization is even more rare.^[1] In our study, mediastinal hydatid cysts were located in the anterior-superior mediastinum in 10 patients, in the posterior mediastinum in nine patients, and in the middle component in five patients. In contrast to our previous study, anterior localization was more common.^[1]

In general, mediastinal hydatid cysts are clinically and radiologically indistinguishable from other mediastinal cystic lesions. Most patients are symptomatic. Complications and symptoms of cyst depend on location, size, and involvement of adjacent structures. Cystic lesion is usually detected incidentally on a routine chest radiograph. Chest radiograph and thoracic CT can attract the physician's attention to hydatid disease in endemic regions.^[8] All our patients underwent direct radiography and CT. Computed tomography scans give useful information about anatomical features of the cyst, the morphology, density and borders of the lesions. However, there is no pathognomonic sign of hydatid cysts. Mediastinal hydatid cyst usually appears as a round cyst. The

presence of calcifications in the wall of cyst increases suspicions of a hydatid disease.^[9] Plain radiograph findings have been described in several ways if rupture of cyst occurs with the air around or within the endocyst, an air-fluid level and the collapsed, crumpled membranes floating in the fluid. When the patient presents with vital structures or spinal involvement is probable, MRI can be more useful than a thoracic CT.^[10] As hydatid cyst primarily involves the liver, abdominal ultrasound should be performed in all cases. Except for one patient, ultrasonography of the abdomen showed normal results in all of our patients. Esophagoscopy was performed in five patients with posterior mediastinal cyst and bronchoscopy was performed in two patients with middle mediastinal cyst. In these patients, no evidence of endoluminal lesions was found. Although transthoracic needle aspiration can be useful for the diagnosis of mediastinal hydatid cyst, it increase the risk of dissemination and anaphylactic shock.^[11,12] There are several controversies in the management of mediastinal hydatid cyst, including the indications for surgery. While most surgeons agree that surgical intervention is indicated for symptomatic patients, the management of patients presenting with minimal to no symptoms or those with very small cyst remains somewhat controversial. Progression of symptoms in this patient population is uncommon. In contrast, other physicians have supported a more aggressive approach.^[10,11] We strongly supported surgical intervention in all of our patients. Size of the cyst alone is not a clear indication for operation. Risk of life-threatening complications such as rupture, secondary infection, fistula, compression of vital structures, anaphylactic shock, and sepsis within mediastinal hydatid cyst is quite high.^[11,12] Most of the patients in

the present series were symptomatic, supporting our inclination towards surgical approach. The authors of this study believe that all detected cases of mediastinal cysts are an indication for surgery. However, older patients or those with comorbidities, which are contraindications to surgery, or with moderately or mildly manifested symptoms of a mediastinal cyst, can be treated conservatively. However, surgery should be the first choice of treatment if symptoms are life-threatening.

Surgery of mediastinal cysts is both diagnostic and curative. Mediastinal hydatid cysts are generally in close contact with neighboring vital structures and differential diagnoses are made via surgical intervention. The choice of an appropriate surgical technique depends on the cyst location. In our study, we managed 16 patients via thoracotomy, three via median sternotomy, and five via VATS. The principal treatment method of mediastinal hydatid cysts is total excision. If total excision of the cyst is not possible due to cyst localization or invasion of vital organs, a hydatid cyst can be managed by partial cystectomy after the lamellar membrane has been removed. In our study, total excision of the cyst was achieved in 19 of the cases while partial cystectomy was performed in the five remaining cases.

In our clinic, we began each operation for mediastinal cyst with the VATS technique in the last five years. An invasion or adhesion of important neighboring anatomical structures (e.g. esophagus, trachea, or vena cava superior) resulted in conversion to mini-thoracotomy. In those cases, total removal was impossible, so conversion was necessary to achieve radical resection. Video assisted thoracoscopic surgery in mediastinal cysts is not always feasible and an alternative is to conduct open procedures.^[13] In all of our cases, the cyst was visible through the thoracotomy site. Of course, if access through thoracotomy is difficult, full or partial sternotomy may also be performed. Access can be useful especially in cases with anterior cysts.

The VATS technique involves optic system insertion into the pleural cavity and dividing the pleural layer over the cystic wall. In our cases, the average duration of hospital stay for patients who were performed VATS was four days (this duration was seven days after thoracotomy). We also observed shorter pleural drainage duration in patients who underwent VATS. In the case of posterior cysts, the source of bleeding can be intercostal arteries. If the cyst is located on tracheo-esophageal groove or aortopulmonary window, the surgeon should be careful to avoid an

injury of the left recurrent laryngeal nerve, which can cause vocal cord paralysis and wheezing after surgery.^[14] Anterior mediastinal cysts are often close to innominate veins and the internal mammary artery, which are the common sources of bleeding and reasons for conversion. Middle mediastinal hydatid cysts sometimes communicate with the bronchial tree or trachea. Consequences of an injury may be massive air leak or empyema requiring open surgery.^[14] Only severe adhesions are contraindications to perform VATS. Other reasons for conversion are poor exposure of the cyst, bleeding and presence of giant cyst. In cases of more serious complications, it is usually safer and necessary to convert to an open procedure. In the patients with large cysts, it was necessary to puncture and aspirate them. That treatment was usually provided at the end of the procedure, after previous careful preparation of the cyst walls. In the case of accidental disruption of the continuity of the cyst, the content was immediately aspirated. The puncture procedure was sometimes performed prior to preparation to reveal anatomical relations more clearly and depended on the preferences of the center where it was performed.^[14-19]

One of the strengths of this study is that, to our knowledge, it is the largest study to date investigating the surgical treatment of mediastinal hydatid cyst. In addition, we approached all of our patients with surgical intervention. However, our study has several limitations, which are usual for retrospective studies, such as selection bias. In addition, longer follow-up is required to fully evaluate the durability of the relief of symptoms and improvement in the quality of life after surgery. Although our clinical outcomes are good, larger series are needed for evaluation of surgical treatment results in mediastinal hydatid cysts. Additionally, we do not have knowledge on the effectiveness and long-term results of drug treatment since all our patients underwent surgery.

In conclusion, in this large series reporting on the surgical treatment of mediastinal hydatid cyst, excellent outcomes were obtained with surgical approach during intermediate term follow-up with no surgical morbidity or mortality. A minimally invasive approach to the management of mediastinal hydatid cyst is safe and effective when performed by surgeons experienced in open and minimally invasive surgery and techniques. The optimal approach and procedures to be performed should be determined on an individualized basis and requires a thorough preoperative investigation.

Declaration of conflicting interests

The authors declared no conflicts of interest with respect to the authorship and/or publication of this article.

Funding

The authors received no financial support for the research and/or authorship of this article.

REFERENCES

1. Eroğlu A, Kürkçüoğlu C, Karaoğlanoğlu N, Tekinbaş C, Kaynar H, Onbaş O. Primary hydatid cysts of the mediastinum. *Eur J Cardiothorac Surg* 2002;22:599-601.
2. Rakower J, Milwidsky H. Primary mediastinal echinococcosis. *Am J Med* 1960;29:73-83.
3. Kabiri el H, Zidane A, Atoini F, Arsalane A, Bellamari H. Primary hydatid cyst of the posterior mediastinum. *Asian Cardiovasc Thorac Ann* 2007;15:60-2.
4. Karavias DD, Vagianos CE, Kakkos SK, Panagopoulos CM, Androulakis JA. Peritoneal echinococcosis. *World J Surg* 1996;20:337-40.
5. Karaoglanoglu N, Kurkcuoglu IC, Gorguner M, Eroglu A, Turkyilmaz A. Giant hydatid lung cysts. *Eur J Cardiothorac Surg* 2001;19:914-7.
6. Kurkcuoglu IC, Eroglu A, Karaoglanoglu N, Turkyilmaz A, Tekinbas C, Basoglu A. Surgical approach of pulmonary hydatidosis in childhood. *Int J Clin Pract* 2005;59:168-72.
7. Eroglu A, Kurkcuoglu IC, Karaoglanoglu N. Primary hydatid cysts of the mediastinum - Reply to Purohit. *Eur J Cardiothorac Surg* 2003;23:258.
8. Aghajanzadeh M, Khajeh Jahromi S, Hassanzadeh R, Ebrahimi H. Posterior mediastinal cyst. *Arch Iran Med* 2014;17:95-6.
9. Aydin Y, Gursan N, Turkyilmaz A, Eroglu A. Mediastinal calcified hydatid cyst. *Ann Thorac Surg* 2011;92:85.
10. Aydin Y, Ogul H, Turkyilmaz A, Eroglu A. Surgical treatment of mediastinal cysts: report on 29 cases. *Acta Chir Belg* 2012;112:281-6.
11. Traibi A, Atoini F, Zidane A, Arsalane A, Kabiri el H. Mediastinal hydatid cyst. *J Chin Med Assoc* 2010;73:3-7.
12. Kürkçüoğlu IC, Eroğlu A, Karaoğlanoğlu N, Polat P. Tension pneumothorax associated with hydatid cyst rupture. *J Thorac Imaging* 2002;17:78-80.
13. Aydin Y, Araz O, Ozgokce M, Ince I, Alper F, Eroglu A. Video-Assisted Thoracoscopic Surgery of Mediastinal Cysts: Report of 13 Cases. *Indian J Surg* 2015;77:236-9.
14. Brzezinski D, Lochowski MP, Kozak J. Videothoracoscopy in the treatment of mediastinal cysts. *Wideochir Inne Tech Maloinwazyjne* 2014;9:393-7.
15. De Giacomo T, Diso D, Anile M, Venuta F, Rolla M, Ricella C, et al. Thoracoscopic resection of mediastinal bronchogenic cysts in adults. *Eur J Cardiothorac Surg* 2009;36:357-9.
16. Gossot D, Izquierdo RR, Girard P, Stern JB, Magdeleinat P. Thoracoscopic resection of bulky intrathoracic benign lesions. *Eur J Cardiothorac Surg* 2007;32:848-51.
17. Ulkü R, Eren N, Cakir O, Balci A, Onat S. Extrapulmonary intrathoracic hydatid cysts. *Can J Surg* 2004;47:95-8.
18. Gursoy S, Ucvet A, Tozum H, Erbaycu AE, Kul C, Basok O. Primary intrathoracic extrapulmonary hydatid cysts: analysis of 14 patients with a rare clinical entity. *Tex Heart Inst J* 2009;36:230-3.
19. Gozubuyuk A, Savasoz B, Gurkok S, Yucel O, Caylak H, Kavakli K, et al. Unusually located thoracic hydatid cysts. *Ann Saudi Med* 2007;27:36-9.