

Excision of mediastinal parathyroid adenoma under the guidance of gamma probe

Gama prob kılavuzluğunda mediastinal paratiroid adenomunun eksizyonu

Mehmet Ali Sakallı,¹ Murat Özkan,¹ Elgin Özkan,² Murat Akal¹

Departments of ¹Thoracic Surgery, ²Nuclear Medicine, Medical Faculty of Ankara University, Ankara, Turkey

ABSTRACT

Parathyroid adenomas are the most frequent cause of primary hyperparathyroidism. In this article, we report a 44-year-old male patient with fatigue, hypercalcemia and hyperparathyroidism. Parathyroid scintigraphy and thoracic computed tomography revealed a lesion consistent with parathyroid adenoma ectopically located in the anterior mediastinum. The parathyroid adenoma was excised successfully under the guidance of intraoperative gamma probe. It is essential to determine the localization of parathyroid adenomas preoperatively. Therefore; ultrasonography, parathyroid scintigraphy and guidance of intraoperative gamma probe in patients with positive parathyroid scintigraphy are crucial for diagnosis and success of surgical treatment.

Keywords: Gamma probe; intraoperative; parathyroid adenoma.

Primary hyperparathyroidism (PHPT) is among the rarely encountered endocrine disorders and frequently manifests with hypercalcemia. Its incidence in adult population is approximately less than 1%. Whilst adenoma in a single parathyroid gland accounts for 85% to 90% of PHPT patients, hyperplasia is responsible for the etiology in 10% to 15% and parathyroid carcinoma is responsible for the etiology in 1% to 2%. Parathyroid adenomas are localized adjacent to thyroid gland by 80% to 90%, whereas they are ectopic by 10%. Ectopic adenomas are found in the anterior mediastinum primarily in the parathyroid localization.^[1]

The main scanning methods used in the diagnosis of primary hyperparathyroidism include ultrasonography and parathyroid scintigraphy performed using

ÖZ

Paratiroid adenomları primer hiperparatiroidizmin en sık nedenidir. Bu yazıda yorgunluk, hiperkalsemi ve hiperparatiroidisi olan 44 yaşında bir erkek hasta sunuldu. Paratiroid sintigrafisi ve torasik bilgisayarlı tomografisinde, ektopik olarak ön mediastende yerleşim gösteren paratiroid adenomu ile uyumlu bir lezyon görüldü. Paratiroid adenomu ameliyat sırası gama prob kılavuzluğunda başarı ile eksize edildi. Paratiroid adenomlarının yerleşiminin ameliyat öncesinde belirlenmesi gereklidir. Bu nedenle; ultrasonografi, paratiroid sintigrafisi ve paratiroid sintigrafisi pozitif olan hastalarda ameliyat sırasında yapılan gama prob kılavuzluğu tanı ve cerrahi tedavinin başarısı için çok önemlidir.

Anahtar sözcükler: Gama prob; ameliyat sırası; paratiroid adenomu.

technetium-99m (99mTc) methoxyisobutylisonitrile (sestamibi). Computed tomography (CT) and magnetic resonance imaging (MRI) are useful additional scanning methods particularly to localize ectopic parathyroid adenomas.^[2] The use of combined radiological methods such as scintigraphy and ultrasonography or scintigraphy and CT enhances the success of clinical approach. For this purpose, the use of hybrid scanning systems such as single-photon emission computed tomography (SPECT)/CT is preferred. SPECT/CT gives more information on the anatomic localization of the lesion particularly in ectopic lesions and in the cases with the history of neck surgery.^[3] The basic therapeutic approach for PHPT is surgery. Surgical technique has become more advanced by the use of intraoperative gamma probe. In addition, it is possible



Available online at
www.tgkdc.dergisi.org
doi: 10.5606/tgkdc.dergisi.2016.12375
QR (Quick Response) Code

Received: September 11, 2015 Accepted: November 06, 2015

Correspondence: Murat Özkan, MD. Ankara Üniversitesi Tıp Fakültesi Göğüs Cerrahisi Anabilim Dalı, 06100 Sıhhiye, Ankara, Turkey.

Tel: +90 312 - 508 29 06 e-mail: muratoz73@hotmail.com

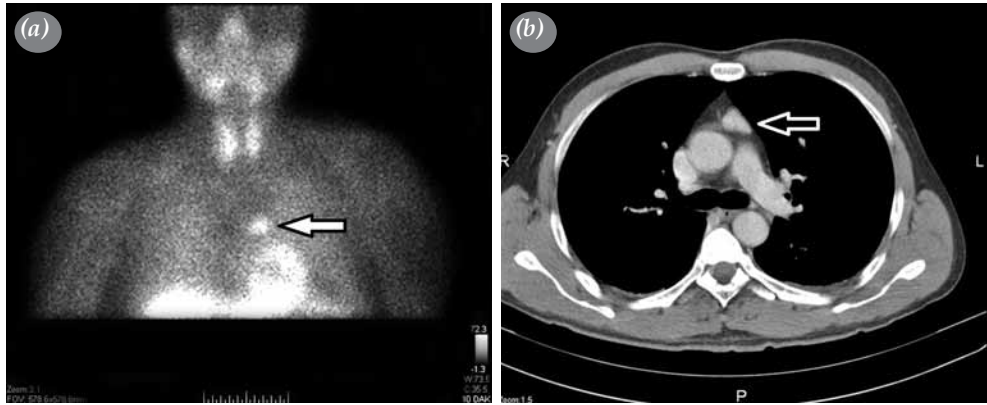


Figure 1. (a) Focal activity accumulation in mediastinum on preoperative parathyroid scintigraphy. (b) Preoperative thorax computed tomography revealing a concentrated soft tissue in anterior mediastinum.

to use gamma probe together with all methods of parathyroid surgery.^[4]

CASE REPORT

A 44-year-old male patient was referred with weakness and his biochemical tests revealed parathormone (PTH) value of 783.2 ng/L (normal range: 12-88 ng/L), and calcium concentration value of 13 mg/dL (normal range: 8.6-10.2 mg/dL). He was prediagnosed with hyperparathyroidism and hospitalized to be examined in the endocrinology clinic. Ultrasonography, which was performed to determine the etiology of hyperparathyroidism, demonstrated no pathology in the neck. Therefore, parathyroid scintigraphy was performed following intravenous injection of 15 mCi ^{99m}Tc-sestamibi while the patient was in the anterior position. On the parathyroid scintigraphy, the focal activity accumulation in thorax on the left side of the midline just in the upper neighborhood of the heart was reported to be consistent with parathyroid adenoma. Chest radiography was unremarkable. Thorax CT demonstrated a 20x14 mm soft tissue in the anterior mediastinum with contrast enhancement (Figures 1a, b). The patient was discussed at multidisciplinary meeting with the participation of thoracic surgeon, endocrinologist, nuclear medicine specialist and surgical treatment was decided for this anterior mediastinal mass. Median sternotomy was performed following intravenous injection of 15 mCi ^{99m}Tc-sestamibi, which was administered preoperatively, approximately two hours before surgery. Any lesion macroscopically consistent with adenoma was not observed and could not be palpated during exploration even it was 2 cm in diameter radiologically. Radioactivity count was obtained from the surgical

area using various-angled intraoperative gamma probe (Europrobe). Whilst 250-300 cps ground activity was obtained from the normal tissues because of mediastinal blood pool, higher counts (approximately 1000-1500 cps) than ground activity were obtained from the region consistent with the area observed on preoperative parathyroid scintigraphy (Figures 2a-c).

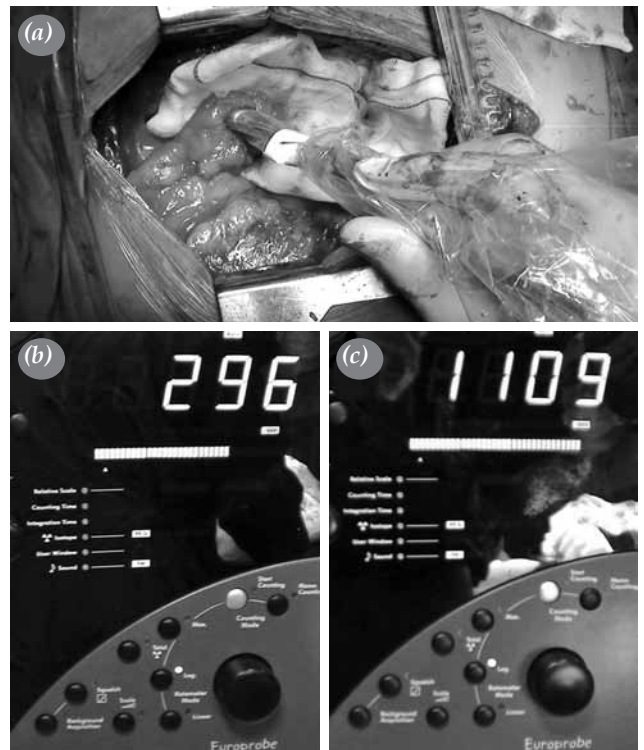

Figure 2. (a) Radioactivity count was obtained from surgical area. (b) Lower counts were obtained from normal tissues. (c) Higher counts were obtained from region consistent with focal activity accumulation on parathyroid scintigraphy.

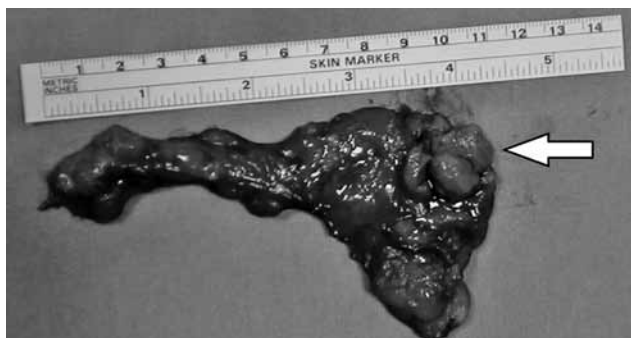

Figure 3. Specimen showing peripherally localized lesion was reported as parathyroid adenoma pathologically.

Whilst the tumor was located inside the soft tissue and it was not possible to distinguish the tumor, entire soft tissue in the left side of thoracic midline was widely excised under the guidance of gamma probe (Figure 3). Although intraoperative PTH monitoring was reported to be meaningful to ensure the total removal of the responsible lesion, we could not measure the intraoperative PTH because of the lack of equipment at our hospital. Serum calcium (8.9 mg/dL) and PTH (19 ng/L) values were within the normal ranges in the first postoperative day. The patient, of whom histopathological examination of the excised specimen revealed parathyroid adenoma, was discharged on the postoperative day seven, uneventfully.

DISCUSSION

The most common cause of PHPT is parathyroid adenoma and surgery is the basic approach for parathyroid adenoma. Ultrasonography and parathyroid scintigraphy are frequently used to determine the localization of parathyroid adenoma prior to surgical approach. Whilst no pathology was determined in the neck of the present patient by ultrasonography, parathyroid scintigraphy demonstrated activity accumulation, which is consistent with mediastinal parathyroid adenoma. Today, hybrid scanning methods such as single-session SPECT/CT are preferred particularly for determining exact localization of ectopic adenomas. Unfortunately, SPECT/CT scanning was not performed in our patient. Nevertheless, CT scan, which was performed in another session, demonstrated soft tissue lesion in the same region in thorax, where activity accumulation was observed.

Surgical intervention under the guidance of intraoperative gamma probe is recommended in those with positive parathyroid scintigraphy and particularly in the presence of resistant or recurrent

hyperparathyroidism as well as ectopic adenomas. Intraoperative gamma probe shortens duration of surgery by providing an easier surgical approach. Another advantage is the fact that it demonstrates success of surgery by *ex vivo* counts obtained by gamma probe from the tissue excised.^[5] Quillo et al.^[6] have reported the rule of 20% for this purpose. Accordingly, the tissue excised may be identified as parathyroid adenoma if it includes higher than 20% of the ground activity count while it is in the surgical area. Whilst there was no sign suggestive of parathyroid adenoma during exploration of the present case, high-count lesion was achieved with the help of gamma probe. This provided advantage in terms of duration of surgery. Since the *ex vivo* counts obtained from the excised material was higher than 20% of the ground activity, success of the surgery was confirmed and the surgery was completed.

Opinion on the success of surgery can be obtained by rapid intraoperative intact PTH measurement in the blood samples taken before and after the excision of adenoma. Accordingly, it is concluded that the adenoma has been successfully excised if serum PTH concentration decreases by 50% after surgery versus before surgery.^[7] Nevertheless, “*in vivo*” versus “*ex vivo*” count under the guidance of gamma probe ascertains that there is no pathological tissue left and thereby the surgery can be completed in the centers where rapid PTH level counting is not available.^[8]

In conclusion, parathyroid surgery performed under the guidance of parathyroid scintigraphy and gamma probe facilitates the localization and surgical excision of ectopic parathyroid pathologies.

Declaration of conflicting interests

The authors declared no conflicts of interest with respect to the authorship and/or publication of this article.

Funding

The authors received no financial support for the research and/or authorship of this article.

REFERENCES

1. Elgazzar A. Parathyroid gland. In: Elgazzar A, editor. The pathophysiologic basis of nuclear medicine. Chapter 7. Berlin: Springer; 2001. p. 141-6.
2. Mariani G, Gulec SA, Rubello D, Boni G, Puccini M, Pelizzo MR, et al. Preoperative localization and radioguided parathyroid surgery. J Nucl Med 2003;44:1443-58.
3. Harris L, Yoo J, Driedger A, Fung K, Franklin J, Gray D, et al. Accuracy of technetium-99m SPECT-CT hybrid images in predicting the precise intraoperative anatomical location of parathyroid adenomas. Head Neck 2008;30:509-17.

4. Rubello D, Casara D, Shapiro B. Recent advances in preoperative and intraoperative nuclear medicine procedures in patients with primary hyperparathyroidism. *Panminerva Med* 2002;44:99-105.
5. Ugur O, Kara PO, Bozkurt MF, Hamaloglu E, Tezel GG, Salanci BV, et al. In vivo characterisation of parathyroid lesions by use of gamma probe: comparison with ex vivo count method and frozen section results. *Otolaryngol Head Neck Surg* 2006;134:316-20.
6. Quillo AR, Bumpous JM, Goldstein RE, Fleming MM, Flynn MB. Minimally invasive parathyroid surgery, the Norman 20% rule: is it valid? *Am Surg* 2011;77:484-7.
7. Gil-Cárdenas A, Gamino R, Reza A, Pantoja JP, Herrera MF. Is intraoperative parathyroid hormone assay mandatory for the success of targeted parathyroidectomy? *J Am Coll Surg* 2007;204:286-90.
8. Onoda N, Ishikawa T, Nishiyama N, Kawabe J, Takashima T, Hirakawa K. Focused approach to ectopic mediastinal parathyroid surgery assisted by radio-guided navigation. *Surg Today* 2014;44:533-9.