



A simultaneous coronary artery bypass grafting on beating heart and right upper lobectomy in a patient with a lung adenocarcinoma

Akciğer adenokarsinomlu bir hastada eş zamanlı atan kalpte koroner arter baypas greftleme ve sağ üst lobektomi

Kivanç Atılğan¹, Ertan Demirdaş¹, Bayram Metin², Zafer Cengiz Er¹, Ferit Çiçekçiöglü¹

¹Department of Cardiovascular Surgery, Bozok University Research and Application Hospital, Yozgat, Turkey

²Department of Thoracic Surgery, Bozok University Research and Application Hospital, Yozgat, Turkey

ABSTRACT

A coexisting coronary heart disease may increase the operative mortality and morbidity rates of lung resection. A simultaneous or a two-stage procedure using myocardial revascularization prior to the pulmonary resection may reduce the postoperative morbidity and mortality. Herein, we present a 65-year-old male case of a lung adenocarcinoma in whom a simultaneous coronary artery bypass grafting on a beating heart and right upper lobectomy was performed.

Keywords: Adenocarcinoma; coronary artery bypass grafting; lung resection; mortality; morbidity.

A concomitant coronary heart disease (CHD) may remarkably increase the mortality or morbidity rates of the primary pulmonary operation in patients with lung cancer. Nearly 5% of the patients awaiting a major lung resection is in need of an invasive or non-invasive cardiac intervention,^[1,2] and also, among the given reports, 0.5% of the patients with CHD are reported as having accompanying lung cancer.^[3-5]

Given these facts, it turns out to be a controversial decision for the surgical process and steps as how to do: One or two-stage, and for single-stage surgery, there comes some other questions: which one is to do first? Coronary artery bypass grafting (CABG) or pulmonary resection? Shall we use cardiopulmonary bypass (CPB) or not?

In this article, we present a simultaneous coronary artery bypass grafting on a beating heart and right

ÖZ

Mevcut koroner kalp hastalığı, akciğer rezeksiyonunun cerrahi mortalite ve morbidite oranlarında bir artışa neden olabilir. Akciğer rezeksiyonundan önce miyokard revaskülarizasyonu ile eş zamanlı veya iki aşamalı işlem, ameliyat sonrası morbidite ve mortalite oranlarını azaltabilmektedir. Bu yazıda, eş zamanlı atan kalpte koroner arter baypas greftleme ve sağ üst lobektomi yapılan akciğer adenokarsinomlu 65 yaşında erkek bir olgu sunuldu.

Anahtar sözcükler: Adenokarsinom; koroner arter baypas greftleme; akciğer rezeksiyonu; mortalite; morbidite.

upper lobectomy in a 65-year-old male patient with a lung adenocarcinoma.

CASE REPORT

A 65-year-old man was admitted with coughing and stable angina pectoris for three months. Physical examination was unremarkable. Chest X-ray showed a right upper lung mass. A contrast computed tomography of the thorax demonstrated a 5.2x5.3 cm lesion in the right upper lobe (Figure 1). Bronchoscopic examination revealed a hyperemic endobronchial tumor at the right upper lobe, suggesting an adenocarcinoma. According to the positron emission tomography, the maximum standardized uptake value (SUVmax) of the lesion was observed to be 13, and there was no mediastinal lymph node uptake. Electrocardiography showed T-wave changes in the V3-6. On transthoracic echocardiography, left ventricular wall dysfunction

Received: October 23, 2017 Accepted: August 20, 2018

Correspondence: Kivanç Atılğan, MD. Bozok Üniversitesi Araştırma ve Uygulama Hastanesi Kalp ve Damar Cerrahisi Anabilim Dalı, 66100 Yozgat, Turkey.
Tel: +90 354 - 212 70 60 e-mail: kivancaatilgan@gmail.com

Cite this article as:

Atılğan K, Demirdaş E, Metin B, Er ZC, Çiçekçiöglü F. A simultaneous coronary artery bypass grafting on beating heart and right upper lobectomy in a patient with a lung adenocarcinoma. Turk Gogus Kalp Dama 2018;26(4):646-648.

©2018 All right reserved by the Turkish Society of Cardiovascular Surgery.

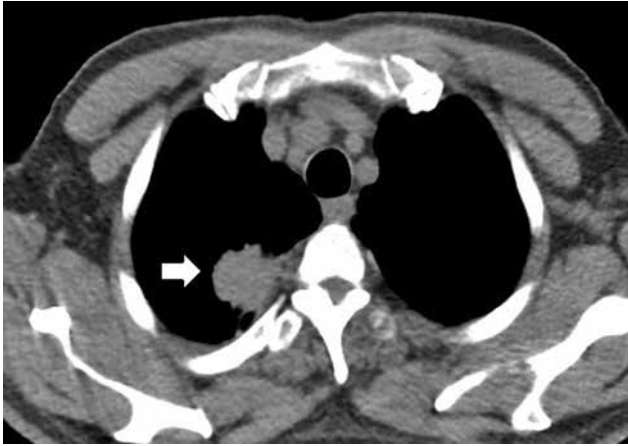


Figure 1. A contrast computed tomography image showing the lesion in the right upper lobe of the thorax (arrow).

was observed with an ejection fraction of 50%. Cardiac catheterization demonstrated 95% stenosis of the left anterior descending (LAD) coronary artery, while other coronary arteries did not have any occlusion higher than 30% (Figure 2).

A written informed consent was obtained from the patient. Following general anesthesia, double-lumen endotracheal intubation was performed. The patient underwent only median sternotomy. Although the left internal mammary artery (LIMA) is often harvested under systemic heparinization to avoid early graft failure,^[9] we preferred to harvest the LIMA before lung surgery without heparinization, due to the fact that heparinization would cause bleeding and a worse exposure eventually. Then, lobectomy of right upper lobe and mediastinal and a wide hilar lymph node excision were performed through median sternotomy. The frozen-section pathology result was reported as an adenocarcinoma for the excisional lung tissue and as the normal lymphatic tissue for the mediastinal lymph nodes. When the pulmonary resection and lymph node dissection were completed, hemostasis was secured prior to heparinization. After the lobectomy procedure, the patient underwent CABG on a beating heart without CPB. Anticoagulation was achieved using intravenous heparin (200 U/kg). The activated clotting time was maintained above 300 sec. The heart was stabilized using the Octopus suction stabilizer (Medtronic, Inc. Minneapolis, Minnesota, USA). The LIMA graft was anastomosed to the LAD with continuous 7-0 polypropylene on the beating heart. Two chest tubes for right, one for left, and one mediastinal tube were put in place, and the incision was closed in continuous layers. Postoperatively, the remaining right lung expanded without evidence of air

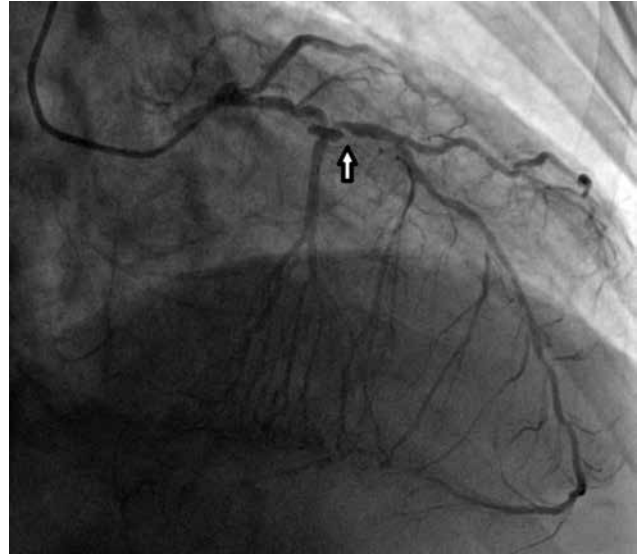


Figure 2. Coronary artery angiography showing the stenosis of the left anterior descending artery (arrow).

leaks and the patient had an uneventful postoperative recovery. Final pathology revealed a 4-cm, moderately differentiated adenocarcinoma, and a negative hilar lymph node with a free bronchial margin, pathological stage IB (T_{2a}N₀M₀). No oncologic treatment regimen was required. No complaints or clinical signs of recurrence were observed during the six-month follow-up period.

DISCUSSION

Five-year survival rate of patients undergoing pulmonary resection of Stage I non-small cell lung cancer has been estimated as 65 to 92%.^[6,7] If a patient has a coexisting CHD, the operative mortality and morbidity following lung resection significantly increase.^[8,9] A two-stage procedure, performing myocardial revascularization with CABG or percutaneous transluminal coronary angioplasty interventions prior to the pulmonary resection may reduce the postoperative morbidity and mortality.^[10,11] However, a two-staged procedure leads to an increase in the cost and morbidity of two separate procedures, and any complication related to the initial operation, mediastinal fixation, and adhesive tissue growth following the LIMA harvesting process, and pleural effusion in the left thoracic cavity may reduce the success of pulmonary resection. In addition, delaying the lung resection for two months for CABG and conventional stents and three months for drug-eluting stents due to a mandatory antiaggregant therapy may cause tumor growth and dissemination, which becomes a quite undesired situation for such an aggressive tumor type.^[12,13]

In single-stage procedures performing CABG before pulmonary resection may result in a remarkable difficulty in hilar exposure due to heparinization, which would be more difficult during CPB due to the need of higher doses of heparin.^[3,14] The additional disadvantages of CPB include perioperative coagulopathy, immunosuppression, and the entrance of tumoral cells into the systemic blood circulation. Therefore, the avoidance of CPB may be beneficial by reducing the associated morbidity in patients undergoing myocardial revascularization with suitable coronary anatomy.

We recommend in such cases applying surgery in a single-stage procedure. Due to hilar exposure difficulties related to heparinization, harvesting LIMA and saphenous grafts should be the first step of surgery. In eligible cases, the second step should be pulmonary resection. In case of critical CHD and hemodynamic instabilities, pulmonary resection may follow CABG procedure, which would result in an additional difficulty in hilar and pulmonary exposure not to damage the bypassing grafts. Therefore, hilar dissection prior to heparinization may be beneficial for the surgeon in performing pulmonary dissection after CABG.

In conclusion, applying a single-stage procedure in patients with lung cancer who are amenable to surgery and coexisting coronary heart disease is an effective and safe method.

Declaration of conflicting interests

The authors declared no conflicts of interest with respect to the authorship and/or publication of this article.

Funding

The authors received no financial support for the research and/or authorship of this article.

REFERENCES

1. Dyszkiewicz W, Jemielity M, Piwkowski C, Kasprzyk M, Perek B, Gasiowski L, et al. The early and late results of combined off-pump coronary artery bypass grafting and pulmonary resection in patients with concomitant lung cancer and unstable coronary heart disease. *Eur J Cardiothorac Surg* 2008;34:531-5.
2. Dyszkiewicz W, Jemielity MM, Piwkowski CT, Perek B, Kasprzyk M. Simultaneous lung resection for cancer and myocardial revascularization without cardiopulmonary bypass (off-pump coronary artery bypass grafting). *Ann Thorac Surg* 2004;77:1023-7.
3. Rao V, Todd TR, Weisel RD, Komeda M, Cohen G, Ikonomidis JS, et al. Results of combined pulmonary resection and cardiac operation. *Ann Thorac Surg* 1996;62:342-6.
4. Johnson JA, Landreneau RJ, Boley TM, Haggerty SP, Hattler B, Curtis JJ, et al. Should pulmonary lesions be resected at the time of open heart surgery? *Am Surg* 1996;62:300-3.
5. Miller DL, Orszulak TA, Pairolero PC, Trastek VF, Schaff HV. Combined operation for lung cancer and cardiac disease. *Ann Thorac Surg* 1994;58:989-93.
6. Danton MH, Anikin VA, McManus KG, McGuigan JA, Campalani G. Simultaneous cardiac surgery with pulmonary resection: presentation of series and review of literature. *Eur J Cardiothorac Surg* 1998;13:667-72.
7. Naruke T, Goya T, Tsuchiya R, Suemasu K. Prognosis and survival in resected lung carcinoma based on the new international staging system. *J Thorac Cardiovasc Surg* 1988;96:440-7.
8. Patel RL, Townsend ER, Fountain SW. Elective pneumonectomy: factors associated with morbidity and operative mortality. *Ann Thorac Surg* 1992;54:84-8.
9. Naunheim KS, Fiore AC, Wadley JJ, Kanter KR, McBride LR, Pennington DG, et al. The changing mortality of myocardial revascularization: coronary artery bypass and angioplasty. *Ann Thorac Surg* 1988;46:666-74.
10. Foster ED, Davis KB, Carpenter JA, Abele S, Fray D. Risk of noncardiac operation in patients with defined coronary disease: The Coronary Artery Surgery Study (CASS) registry experience. *Ann Thorac Surg* 1986;41:42-50.
11. Thomas P, Giudicelli R, Guillen JC, Fuentes P. Is lung cancer surgery justified in patients with coronary artery disease? *Eur J Cardiothorac Surg* 1994;8:287-91.
12. Okay T. Simultaneous lung cancer and heart disease. *Toraks Cerrahisi Bülteni* 2015;9: 269-82.
13. Samancılar Ö, Turhan K, Çağırıcı U, Çakan A, Özbaran M. Synchronous coronary artery and pulmonary operations in three patients with lung cancer and coronary artery disease. *Turk Gogus Kalp Dama* 2007;15:165-7.
14. Dalton ML Jr, Parker TM, Mistrot JJ, Bricker DL. Concomitant coronary artery bypass and major noncardiac surgery. *J Thorac Cardiovasc Surg* 1978;75:621-4.