



Case Report / Olgu Sunumu

Closure of an acquired aortocoronary venous fistula after coronary artery bypass grafting causing heart failure and stable angina: A case report

Koroner arter baypas greftleme sonrası kalp yetmezliği ve stabil anjina neden olan edinsel aorto-koroner venöz fistül kapatılması: Olgu sunumu

Hakan Göçer¹, Muhammed Abusharekh², Ertugrul Ercan², Ahmet Barış Durukan³

Institution where the research was done:

MedicalPark Uşak Hospital, Uşak, Turkey

Author Affiliations:

¹Department of Cardiology, MedicalPark Uşak Hospital, Uşak, Turkey

²Department of Cardiology, MedicalPark İzmir Hospital, Uşak, Turkey

³Department of Cardiovascular Surgery, MedicalPark Uşak Hospital, Uşak, Turkey

ABSTRACT

Iatrogenic aortocoronary venous fistula arising from anastomosing an aortocoronary graft to a cardiac vein is a rare complication following coronary artery bypass grafting. A 75-year-old male patient was admitted with recurrent angina accompanied by congestive heart failure six years after surgery. He was diagnosed with an acquired saphenous vein graft-to-cardiac vein fistula. Based on the estimation of risks versus benefits, the heart team decided to perform percutaneous closure with a vascular occlusion device. Subsequently, complaints and echocardiographic findings of the patient resolved.

Keywords: Arteriovenous fistula; cardiac vein; coronary artery bypass grafting; vascular closure device.

Acquired aortocoronary venous fistula (ACVF) is a rare, but critical complication of coronary artery bypass grafting (CABG) and leads to serious clinical consequences, such as coronary steal phenomenon, high-output heart failure, cardiac tamponade, and death.^[1] Although ACVFs have primarily been treated surgically, advanced percutaneous techniques seem to be promising in recent years. These include coil embolization, balloon occlusion, stenting unbypassed artery, covered stent deployment either by antegrade or retrograde delivery, double-umbrella or vascular occlusion devices.^[2]

ÖZ

Kardiyak vene anastomoz edilen aortokoroner greft sonucu oluşan iyatrojenik aortokoroner venöz fistül, koroner arter baypas greftleme sonrası görülen nadir bir komplikasyondur. Yetmiş beş yaşında erkek hasta ameliyattan altı yıl sonra konjestif kalp yetmezliğinin eşlik ettiği tekrarlayan anjina ile başvurdu. Hastaya edinsel safen ven grefti-kardiyak ven fistülü tanısı kondu. Risk ve fayda değerlendirmesine dayanarak, kalp ekibi vasküler oklüzyon cihazı ile perkütan kapama uygulama kararı aldı. Akabinde, hastanın şikayetleri ve ekokardiyografik bulguları düzeldi.

Anahtar sözcükler: Arteriovenöz fistül; kardiyak ven; koroner arter baypas greftleme; vasküler kapama cihazı.

Herein, we present a case of an acquired saphenous vein graft to cardiac vein fistula which was successfully occluded with a vascular occlusion device.

CASE REPORT

A 75-year-old male patient was referred to our clinic due to recurrent stable angina attacks and progressive exertional dyspnea. The Canadian Cardiovascular Society grading of angina was III. He underwent CABG in an external center 10 years ago with saphenous venous grafts (SVG) to left anterior descending (LAD) artery, right circumflex artery (RCA), and obtuse

Received: June 16, 2019 Accepted: August 03, 2019 Published online: October 23, 2019

Correspondence: Ahmet Barış Durukan, MD. MedicalPark Uşak Hastanesi Kalp ve Damar Cerrahisi Bölümü, 64200 Uşak, Turkey.
Tel: +90 276 - 227 65 65 e-mail: barisdurukan@yahoo.com

Cite this article as:

Göçer H, Abusharekh M, Ercan E, Durukan AB. Occlusion of an acquired aortocoronary venous fistula after coronary artery bypass grafting causing heart failure and stable angina: A case report. Turk Gogus Kalp Dama 2019;27(4):580-582

©2019 All right reserved by the Turkish Society of Cardiovascular Surgery.

marginal (OM) where proximal anastomosis of the OM SVG was performed on LAD SVG (which was later understood that it was anastomosed to the great cardiac vein accidentally). Following CABG, there were no significant complaints. Six year later, symptoms appeared which progressively increased for the past four years.

Electrocardiography during admission revealed non-specific ST and T-wave changes with findings of biatrial enlargement. Transthoracic echocardiography demonstrated dilated heart chambers with a pulmonary-to-systemic flow ratio (Q_p/Q_s) of 2.1, supporting important left-to-right shunt. It would be more reliable, if the Q_p/Q_s ratio was measured with catheterization rather than echocardiography. Pulmonary

hypertension, biatrial enlargement, and normal left ventricular systolic function were observed. Coronary angiography and subsequent selective coronary vein graft angiography revealed anastomosed SVG-to-great cardiac vein, consequently flowing into the coronary sinus (Figure 1a, 1b). After estimation of risks versus benefits, the heart team decided percutaneous closure of ACVF due to symptoms and signs of high-output heart failure and recurrent angina episodes, despite optimal medical treatment.

There was progression of the lesion in the OM, compared to preoperative angiography. The RCA was severely stenosed, LAD was totally occluded, and RCA graft was also occluded. The OM and RCA were stented. The venous graft ostium showed severe angulation

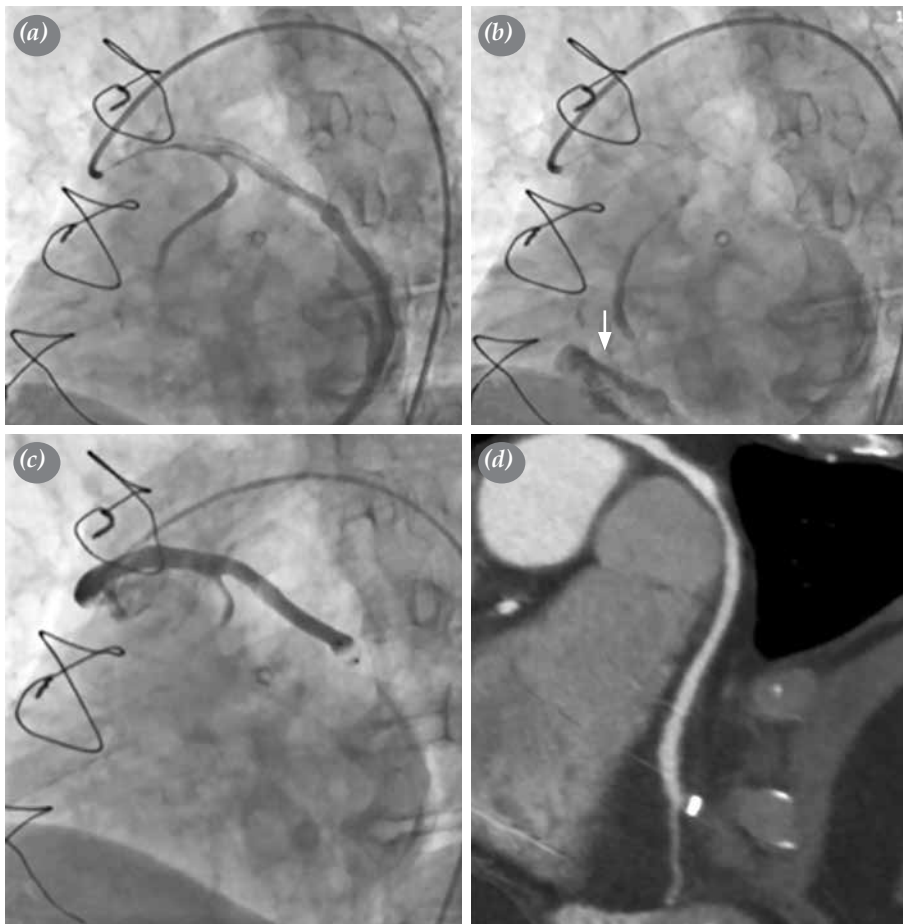


Figure 1. (a) Selective aorta-saphenous vein graft angiography showing an inadvertently anastomosed saphenous vein graft to great cardiac vein. Obtuse marginal graft is weak due to steal. (b) The graft consequently flowing into right atrium [white arrow]. (c) The occluder's (Amplatzer Vascular Plug II, 6-mm) placement to appropriate location and control angiography showing complete occlusion of acquired fistula. (d) Post-procedural cardiac computed tomographic angiography showing appropriate position of occluder and complete occlusion of fistula.

and, therefore, coronary balloon was inflated at the distal graft, and simultaneously the occluder (6-mm Amplatzer® Vascular Plug II; St. Jude Medical, St. Paul, MN, USA) was progressed and positioned to the appropriate location and balloon was, then, deflated and removed (antegrade anchoring technique). Control vein graft angiography after five min showed complete occlusion of the ACVF (Figure 1c). Subsequently, murmur disappeared and echocardiography revealed a decline in the cardiac chamber diameters with normal Qp/Qs. During follow-up, exercise tolerance capacity of the patient improved and complaints were completely resolved. Post-procedural CT angiography demonstrated appropriate position of the occluder and confirmed the complete occlusion (Figure 1d). A written informed consent was obtained from the patient.

DISCUSSION

Acquired ACVF is an extremely rare complication of aortocoronary bypass surgery caused by improperly anastomosing an aortocoronary graft to a cardiac vein.^[3,4] Myocardial scar associated with previous infarction or surgery, fibrosis, and adhesions in the pericardium may be the potential cause by deteriorating familiar anatomy. Similarly, thick epicardial fat tissue complicates differentiation of arteries from nearby veins and cause a false anastomosis. Apart from iatrogenic causes, ACVF is rarely seen as a complication of the aneurysm formation of the aortocoronary graft carrying a high probability of catastrophic outcomes.^[4] In the present case, the underlying cause is still unclear.

Acquired ACVF may result in significant morbidities such as coronary steal phenomenon, leading to myocardial ischemia, high-output heart failure, infective endocarditis, significant systemic-to-pulmonary shunt, pulmonary hypertension, hemothorax caused by rupture, and cardiac tamponade.^[5] Our patient demonstrated cardiac failure, cardiac angina, and increased systemic-to-pulmonary shunt. In our patient, since the native coronary disease was progressed and symptoms resolved after fistula occlusion concomitant with OM and RCA stenting, symptoms upon admission may be also related with the nature of the progressive disease.

Considering the lack of data due to its rarity, it is reasonable to make the most optimal decision by the heart team. Spontaneous closure without an intervention in two asymptomatic cases, and good response to medical treatment alone in three cases have been reported in the literature.^[5] Nevertheless, ligation of the fistula and surgical re-bypassing is most commonly reported treatment option.^[5] Given the high mortality and morbidity risk of redo surgery, less invasive techniques have been adopted in recent years. To date, various advanced percutaneous techniques have been described which are promising alternatives. Coil embolization, balloon occlusion of the fistula, stenting of the unbypassed artery, covered stent deployment either by antegrade or retrograde delivery, double-umbrella or vascular occlusion devices should be considered alternative modalities.^[5]

In conclusion, despite the surgical preference in aortocoronary fistula are more favorable, percutaneous interventions are feasible and safe in experienced hands.

Declaration of conflicting interests

The authors declared no conflicts of interest with respect to the authorship and/or publication of this article.

Funding

The authors received no financial support for the research and/or authorship of this article.

REFERENCES

1. Gardner JD, Maddox WR, Calkins JB Jr. Iatrogenic aortocoronary arteriovenous fistula following coronary artery bypass surgery: A case report and complete review of the literature. *Case Rep Cardiol* 2012;2012:652086.
2. Braun P, Hölting R, Stroh E, May E, Atmaca N, Krian A, et al. Coil embolization of an AV-fistula between the left thoracic artery and vein after coronary artery bypass surgery. *Z Kardiol* 1999;88:812-4. [Abstract]
3. Ornek E, Kundi H, Kiziltunc E, Cetin M. Treatment of iatrogenic aortocoronary arteriovenous fistula with coronary covered stent. *Case Rep Cardiol* 2016;2016:9126817.
4. Calkins JB Jr, Talley JD, Kim NH. Iatrogenic aorto-coronary venous fistula as a complication of coronary artery bypass surgery: patient report and review of the literature. *Cathet Cardiovasc Diagn* 1996;37:55-9.
5. Sreenivasan J, Ayub M, Yadav N, Golzar Y. Rare cause of late recurrent angina following coronary artery bypass grafting: Iatrogenic aortocoronary arteriovenous fistula causing coronary steal. *Case Rep Cardiol* 2018;2018:6913737.