



Case Report / Olgu Sunumu

Aortic valve replacement using valve-in-valve procedure in a patient with left atrial appendage thrombus

*Sol atriyal apendikte trombüsü olan bir hastada kapak içine kapak işlemi ile
aort kapak replasmanı*

Mehmet Erdoğan¹, Engin Bozkurt²

Institution where the research was done:

Ankara Atatürk Training and Research Hospital, Ankara, Turkey

Author Affiliations:

¹Department of Cardiology, Ankara City Hospital, Ankara, Turkey

²Department of Cardiology, Ankara Yıldırım Beyazıt University Faculty of Medicine, Ankara, Turkey

ABSTRACT

In recent years, indications and age range of patients who are eligible for transcatheter aortic valve replacement have been increasingly extended. The presence of a thrombus in the left atrial appendage is an exclusion criterion in many studies using transcatheter aortic valve replacement. An 86-year-old male patient was admitted with symptomatic severe aortic stenosis secondary to degeneration of a 22-mm bioprosthetic valve implanted 14 years ago. Transesophageal echocardiography revealed a thrombus in the left atrial appendage and it was confirmed by contrast-enhanced computed tomography. The balloon-expandable valve was successfully implanted into the degenerated aortic bioprosthesis. In conclusion, we aimed to show that valve-in-valve transcatheter aortic valve replacement can be performed in a patient with thrombus in the left atrial appendage.

Keywords: Atrial fibrillation, left atrial appendage thrombus, transcatheter aortic valve replacement, valve-in-valve.

In recent years, indications of transcatheter aortic valve replacement (TAVR) have been extended to comprise patients with a moderate surgical risk. As the population ages, the number of patients with bioprosthetic valve failure proportionally increases and these patients are often referred to redo valve surgery.

Valve-in-valve (ViV) procedure is a promising technique for redo aortic valve surgeries.^[1] The success of the procedure depends on four main concepts:

ÖZ

Son yıllarda transkateter aort kapak replasmanı için uygun olan hastaların endikasyonları ve yaş aralığı giderek genişlemektedir. Transkateter aort kapak replasmanının uygulandığı birçok çalışmada sol atriyal apendikte trombüs varlığı bir dışlanma kriteridir. Seksen altı yaşında erkek hasta, 14 yıl önce implante edilen 22 mm'lik bir biyoprotez kapağın dejenerasyonuna bağlı semptomatik ciddi aort darlığı ile başvurdu. Transözofageal ekokardiyografide sol atriyal apendikte trombüs görüldü ve kontrastlı bilgisayarlı tomografi ile doğrulandı. Balon ile genişleyen kapak, dejenere olmuş aort biyoprotezine başarıyla yerleştirildi. Sonuç olarak, sol atriyal apendikte trombüsü olan bir hastada kapak içine kapak yöntemi ile transkateter aort kapak replasmanının yapılabileceğini göstermeyi amaçladık.

Anahtar sözcükler: Atriyal fibrilasyon, sol atriyal apendiks trombüsü, transkateter aort kapak replasmanı; kapak içine kapak.

(i) understanding transcatheter heart valve design; (ii) a detailed understanding of the design or anatomy; (iii) correct sizing of the chosen transcatheter heart valve prosthesis for the existing surgical heart valve; and (iv) the ideal implantation position for the transcatheter heart valve.^[2]

In this article, we report our TAVR technique using ViV in an octogenarian case with a left atrial appendage (LAA) thrombus.

Received: August 20, 2019 Accepted: November 03, 2019 Published online: January 23, 2020

Correspondence: Mehmet Erdoğan, MD. Ankara Atatürk Eğitim ve Araştırma Hastanesi, Kardiyoloji Kliniği, 06800 Çankaya, Ankara.

Tel: +90 312 - 552 60 00 e-mail: mhmerdogan@windowslive.com

Cite this article as:

Erdoğan M, Bozkurt E. Aortic valve replacement using valve-in-valve procedure in a patient with left atrial appendage thrombus. Turk Gogus Kalp Dama 2020;28(1):205-208

CASE REPORT

A frail 86-year-old male patient was referred to our clinic with symptoms of dyspnea. His medical history revealed aortic valve surgery with a 22-mm Sorin® (Sorin Group Inc., Arvada, CO, USA) bioprosthetic valve 14 years ago. Transthoracic echocardiography (TTE) showed that ejection fraction was 55%, degeneration in the aortic bioprosthetic valve with restricted leaflet motion, and a mean gradient of 55 mmHg along with moderate tricuspid regurgitation and a systolic pulmonary artery pressure (sPAP) of 90 mmHg. Transesophageal echocardiography (TEE) revealed a thrombus in the LAA which was later confirmed by contrast-enhanced computed tomography (CT) (Figure 1a, b). In addition, CT demonstrated degenerated bioprosthetic valve leaflets, annulus, calcification distribution, and landmarks of the transcatheter valve (Figure 2a, b). The heart team decided to proceed with ViV-TAVR, as the patient was deemed to be inoperable due to multiple comorbidities.

A written informed consent was obtained from the patient.

Using retrograde transfemoral route, a 23-mm SAPIEN® (Edwards Lifesciences, LLC, Irvine, CA, USA) balloon-expandable valve was successfully implanted (Figure 3a, b). The peri-procedural activated clotting time was between 250 and 300 sec. There was no sign of coronary obstruction or aortic regurgitation in the post-procedural follow-up using aortic root angiography (Figure 3c). An aortic mean gradient of 18 mmHg was detected on control echocardiography with a persistent LAA thrombus (LAAT), but no evidence of thrombus embolization. Post-procedural neurological examination of the patient was normal without any neurological deficit.

At the beginning of the procedure, TEE revealed persistent LAAT, despite adequate anticoagulation with warfarin therapy. For persistent thrombus in the LAA, the use of potent anticoagulants such as dabigatran was

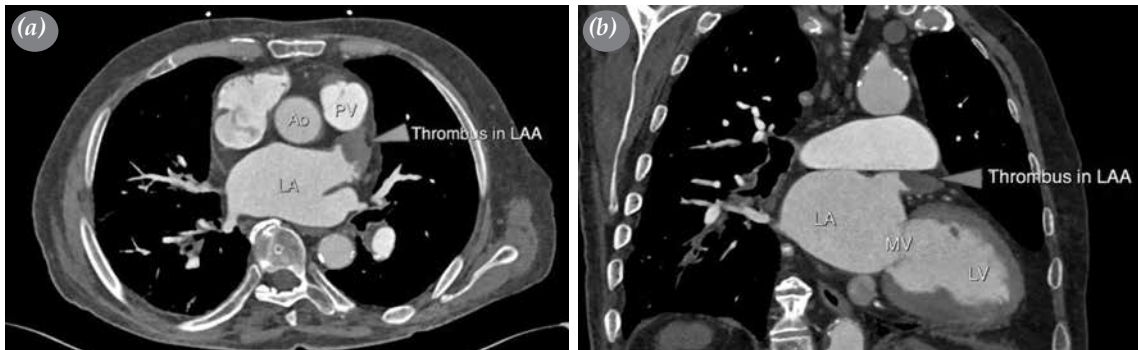


Figure 1. (a, b) Contrast-enhanced computed tomography images showing a thrombus in left atrial appendix.
PV: Pulmonary valve; Ao: Aortic valve; LA: Left atrium; LAA: Left atrial appendix; MV: Mitral valve; LV: Left ventricle.

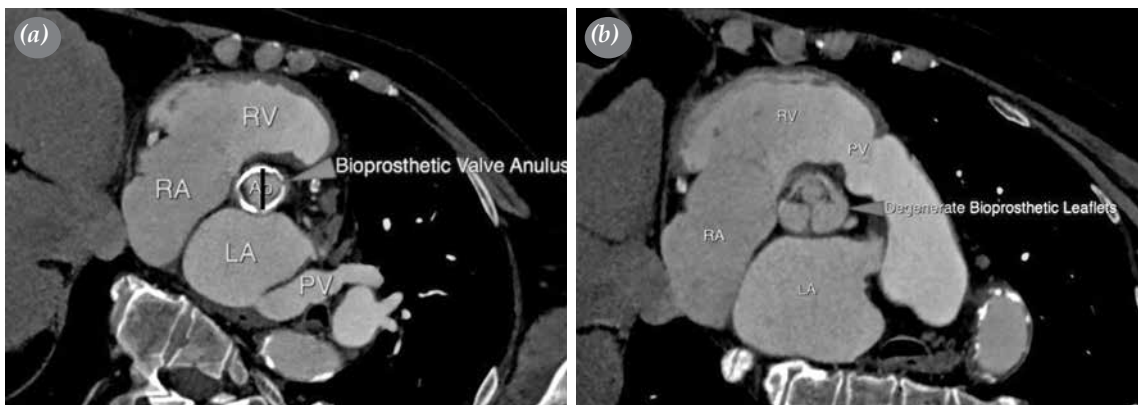


Figure 2. (a, b) Contrast-enhanced computed tomography images showing degenerated bioprosthetic leaflet and annulus.

RV: Right ventricle; RA: Right atrium; LA: Left atrium; PV: Pulmonary vein (image A); PV: Pulmonary valve (image B).

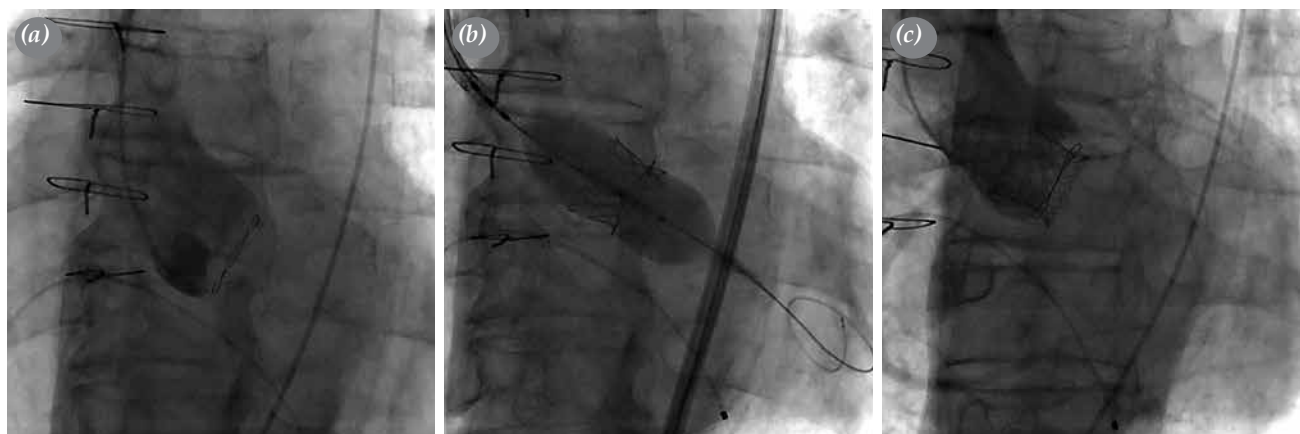


Figure 3. (a) Demonstration of coronary ostia with pigtail angiography and fluoroscopic view of degenerated bioprosthetic valve annulus. (b) Implantation of the balloon-expandable valve into the degenerated bioprosthetic valve under rapid ventricular pacing. (c) Aortic root angiography after implantation and evaluation of coronary obstruction and paravalvular aortic regurgitation.

not considered, due to the advanced age, weakness, and frailty of the patient which are all associated with an increased risk for bleeding. In addition, the balloon-expandable aortic bioprosthetic valve requiring a rapid ventricular pacing was preferred over the self-expandable valve, although thrombus increased the risk for expulsion, since the stent struts of the balloon-expandable valve was thought to be better aposed with the balloon into the degenerated bioprosthetic valve. Also, due to the higher risk for paravalvular aortic insufficiency and bioprosthetic valve migration, the self-expandable valve was not considered, despite the lack of rapid ventricular pacing requirements.

DISCUSSION

To the best of our knowledge, this is the first case of LAAT in the literature in whom ViV-TAVR was applied due to severe aortic stenosis. This case highlights two significant issues. First, in randomized clinical trials using TAVR, nearly all patients with LAAT were not included in the study. Second, the TAVR procedure is usually performed in combination with the ViV procedure to failed bioprosthetic valves, rather than native aortic valves. However, due to the ultimately limited durability of the bioprosthetic valve, structural degenerations occur in subsequent decades after implantation. Traditionally, redo surgery is the standard treatment for patients with degenerated bioprosthetic valves. The ViV-TAVR procedure is recommended as the most optimal alternative treatment in this patient group.^[1] In a recent study, three-year follow-up results of patients who underwent ViV-TAVR due to bioprosthetic valve failure demonstrated improved survival rates and an excellent quality of life.^[3]

Aortic valve predilatation is conventionally performed with standard occlusive balloons for patients with balloon-expandable valve implantation. The sizing of the standard occlusive balloons (frequently used 20, 23, 25×40 mm) are selected according to the annulus diameter. In case of known predilatation, the procedure is often performed with rapid ventricular pacing to prevent proper balloon positioning, slippage, and jump. However, rapid ventricular pacing has several disadvantages such as left ventricular stunning, decreased cardiac output, and stroke.^[4] It has been also shown that stroke rates are lower in patients without balloon aortic valvuloplasty.^[5] In order to reduce the risk for stroke, the choice of self-expandable valve which does not always require balloon predilatation may be considered. This condition may be suitable for degenerated bioprosthetic valves with mild-to-moderate calcification and a relatively large annulus. On the contrary, for the degenerated bioprosthetic valves with heavy calcification, it would be more appropriate to prefer balloon-expandable valves due to stronger radial force, as in our case.

Stroke is a serious complication of TAVR with a reported incidence of 5% within 30 days.^[6] Embolization of the calcified material, thrombus formation, damage of the atheromatous debris during guidewire or device manipulation, or cerebral hypoperfusion during rapid ventricular pacing are potential causes of stroke. Embolization of LAAT has been also shown as the cause of stroke during the TAVR procedure.^[7] In a recent study, the incidence of LAAT was found to be 11% in patients who underwent TAVR and 32% in patients with a history of atrial fibrillation (AF).^[7] Also, in this study, the

presence of LAAT was associated with a five-times higher risk for procedural stroke. In the literature, there is a limited number of data and small number of cases on this patient population. In a study conducted by Ayhan et al.,^[8] TAVR was successfully performed without stroke complication in six patients with LAAT who were diagnosed with symptomatic severe aortic stenosis and AF. Similarly, the present case indicates that ViV-TAVR procedure can be successfully applied to a patient with LAAT.

In conclusion, indications and age range of patients who are eligible for transcatheter aortic valve replacement have been increasingly extended. Therefore, it can be speculated that there would be an increase in the number of left atrial appendage thrombus cases, since the number of transcatheter aortic valve replacement applied to elderly patients has been on the rise. On the other hand, as the number of these procedures for younger patients increases, the number of patients requiring valve-in-valve technique can be expected to increase. As a result, there is still an unmet need to improve operator experience, to develop sophisticated transcatheter valve systems, and to design clinical studies including this patient population.

Declaration of conflicting interests

The authors declared no conflicts of interest with respect to the authorship and/or publication of this article.

Funding

The authors received no financial support for the research and/or authorship of this article.

REFERENCES

1. Ye J, Cheung A, Yamashita M, Wood D, Peng D, Gao M, et al. Transcatheter aortic and mitral valve-in-valve implantation for failed surgical bioprosthetic valves: An 8-year single-center experience. *JACC Cardiovasc Interv* 2015;8:1735-44.
2. Bapat VN, Attia R, Thomas M. Effect of valve design on the stent internal diameter of a bioprosthetic valve: a concept of true internal diameter and its implications for the valve-in-valve procedure. *JACC Cardiovasc Interv* 2014;7:115-27.
3. Webb JG, Murdoch DJ, Alu MC, Cheung A, Crowley A, Dvir D, et al. 3-Year outcomes after valve-in-valve transcatheter aortic valve replacement for degenerated bioprostheses: the partner 2 registry. *J Am Coll Cardiol* 2019;73:2647-55.
4. Shivaraju A, Thilo C, Sawlani N, Ott I, Schunkert H, von Scheidt W, et al. Aortic Valve Predilatation with a Small Balloon, without Rapid Pacing, prior to Transfemoral Transcatheter Aortic Valve Replacement. *Biomed Res Int* 2018;2018:1080597.
5. García E, Martín P, Hernández R, Rodríguez V, Fernández A, Gama V, et al. Feasibility and safety of transfemoral implantation of Edwards SAPIEN XT prosthesis without balloon valvuloplasty in severe stenosis of native aortic valve. *Catheter Cardiovasc Interv* 2014;83:791-5.
6. Smith CR, Leon MB, Mack MJ, Miller DC, Moses JW, Svensson LG, et al. Transcatheter versus surgical aortic-valve replacement in high-risk patients. *N Engl J Med* 2011;364:2187-98.
7. Palmer S, Child N, de Belder MA, Muir DF, Williams P. Left atrial appendage thrombus in transcatheter aortic valve replacement: incidence, clinical impact, and the role of cardiac computed tomography. *JACC Cardiovasc Interv* 2017;10:176-84.
8. Ayhan H, Durmaz T, Keleş T, Aslan AN, Sarı C, Kasapkara H, et al. Transcatheter aortic valve implantation in patients with left atrial appendix thrombus. *Russ J Cardiol* 2014;105:19-22.