

Electrophysiological evaluation of efficacy of clipping in thoracic sympathectomy: An experimental cadaveric study

Torakal sempatektomide klips etkinliğinin elektrofizyolojik değerlendirmesi: Deneysel bir kadavra çalışması

Hakan Salcı¹, Hilal Acar¹, Mevüt Özgür Taşkapılıoğlu², Hüseyin Melek³, Ahmet Sami Bayram³

Institution where the research was done:
Uludağ University Faculty of Medicine, Bursa, Turkey

Author Affiliations:

¹Department of Surgery, Uludağ University, Faculty of Veterinary Medicine, Bursa, Turkey

²Department of Brain and Nerve Surgery, Uludağ University Faculty of Medicine, Bursa, Turkey

³Department of Thoracic Surgery, Uludağ University Faculty of Medicine, Bursa, Turkey

ABSTRACT

Background: This study aims to examine the efficacy of clipping in thoracic sympathectomy based on electrophysiological evaluation and to investigate whether nerve conduction can be formed by collateral nerve extensions as a result of the clipping procedure to different levels of sympathetic nerve.

Methods: Newly sacrificed six sheep hemithoraces were studied between August 2016 and October 2016. Thoracic sympathectomy was performed by clipping at T2, T3, T4, and T5 sympathetic chain levels and their branches. Electrophysiological studies were performed with an electromyography device and the filter range was 1 Hz with 20 µV/D amplification. Signals were processed digitally; bipolar subdermal needle electrodes were used as stimulation and recording electrodes (Ø 0.75 mm); and the ground electrode was placed in the intercostal muscle where the thoracic sympathectomy procedure would be performed.

Results: Electrophysiological evaluations showed that clips placed on the main sympathetic chain branches and sympathetic nerve trunk prevented collateral impulse conduction and stimulated potentials were not recorded. However, sympathetic conduction continued at the same intensity after removal of the clips.

Conclusion: Clipping of different regions of the sympathetic nerve provides electrophysiological blockage of the sympathetic nerve, and conduction continues after removal of the clips. However, the short- and long-term postoperative electrophysiological results after removal of the clips over the sympathetic nerve is still a question mark.

Keywords: Clipping, electrophysiology, thoracic sympathectomy.

ÖZ

Amaç: Bu çalışmada torakal sempatektomide elektrofizyolojik değerlendirme ile klips etkinliği incelendi ve farklı sempatik sinir düzeylerinde klips uygulanması sonucu sinir iletiminin kollateral sinir uzantıları ile sağlanıp sağlanmayacağı araştırıldı.

Çalışma planı: Ağustos 2016 - Ekim 2016 tarihleri arasında taze sakrifiye edilmiş altı koyun hemitoraksı üzerinde çalışıldı. Torakal sempatektomi T2, T3, T4 ve T5 sempatik zincir seviyeleri ve dallarından klipslenerek yapıldı. Elektrofizyolojik çalışmalar, bir elektromiyografi cihazı ile yapıldı ve 1 Hz, 20 µV/D filtre aralığı kullanıldı. Sinyaller dijital olarak işlendi; stimülatör ve kayıt elektrodu olarak bipolar subdermal iğne elektrotlar (Ø 0.75 mm) kullanıldı ve toprak elektrot torakal sempatektomi işleminin yapılacağı interkostal kas içine yerleştirildi.

Bulgular: Elektrofizyolojik değerlendirmeler, ana sempatik zincir dalları ve sempatik sinir gövdesi üzerine yerleştirilen klipslerin kollateral uyarı iletimini önlediğini ve uyarılmış potansiyellerin kaydedilmediğini gösterdi. Ancak klipslerin uzaklaştırılmasından sonra sempatik iletim aynı yoğunlukta devam etti.

Sonuç: Sempatik sinire farklı bölgelerden klips uygulanması, sempatik sinirin elektrofizyolojik blokajını sağlar ve klipsler çıkarıldıktan sonra iletim devam eder. Ancak sempatik sinir üzerindeki klipslerin çıkarılmasından sonra kısa ve uzun dönem ameliyat sonrası elektrofizyolojik sonuçlar halen bir soru işaretidir.

Anahtar sözcükler: Klips, elektrofizyoloji, torakal sempatektomi.

Received: January 27, 2020 Accepted: March 03, 2020 Published online: October 21, 2020

Correspondence: Hakan Salcı, MD. Bursa Uludağ Üniversitesi, Veteriner Fakültesi, Cerrahi Anabilim Dalı, 16059 Nilüfer, Bursa, Türkiye.

Tel: +90 224 - 294 08 41 e-mail: hsalci@uludag.edu.tr

Cite this article as:

Salcı H, Acar H, Taşkapılıoğlu MÖ, Melek H, Bayram AS. Electrophysiological evaluation of efficacy of clipping in thoracic sympathectomy: An experimental cadaveric study. Turk Gogus Kalp Dama 2020;28(4):669-673

©2020 All right reserved by the Turkish Society of Cardiovascular Surgery.

This is an open access article under the terms of the Creative Commons Attribution-NonCommercial License, which permits use, distribution and reproduction in any medium, provided the original work is properly cited and is not used for commercial purposes (<http://creativecommons.org/licenses/by-nc/4.0/>).

Thoracic sympathectomy (TS) is a surgical procedure performed to reduce various sympathetic disorders by reducing vasomotor tone and decreasing peripheral vascular resistance.^[1] Indications for TS are palmar hyperhidrosis, flushing,^[1-8] cold intolerance, reflex sympathetic dystrophy, distal occlusions of the arms, long QT syndrome, peripheral vascular insufficiency, axillary sweating, angina pectoris, and Raynaud's syndrome.^[1-5,7,9,10]

Thoracic sympathectomy is performed as resection, ablation or division of the thoracic sympathetic chain to prevent adrenergic effect of the arms.^[11,2,5,11-14] In recent years, for the treatment of hyperhidrosis, the application of metal clips to the sympathetic chain has become widespread.^[15-18] Compensatory sweating is the most common complication of TS.^[4,5,7,8] If the complication occurs, the metal clips should be removed and nerve conduction should be restored.^[6,8,17]

In the present study, we aimed to examine the efficacy of clipping in TS based on electrophysiological evaluation and to investigate whether nerve conduction could be formed by collateral nerve extensions as a result of the clipping procedure to different levels of sympathetic nerve.

MATERIALS AND METHODS

In this study, newly sacrificed three 1.5-year-old thoracic sheep cadavers without any pathology were used between August 2016 and October 2016. A total of six hemithoraces were evaluated. The study was conducted in accordance with Uludag University Committee on Animal Research Ethics and the principles of the European Union Directive on the Protection of Animals used for Scientific Purposes.

After a median sternotomy, the visibility of both hemithoraces was achieved, and care was taken not to damage the nerves and ganglia of the sympathetic system during removal of the other thoracic organs. Following dissection of the parietal pleura, TS was performed by applying a single titanium clip at the T2, T3, T4, and T5 levels of the sympathetic chain with the aid of a right-angled, U-shaped endoscopic multiple clip applier.

Thoracic sympathectomy was applied to the first cadaver by clipping from T2 and T3 levels in the right hemithorax and T3 in the left hemithorax. The clips were, then, applied on the right hemithorax of the second cadaver at the level of T4 and T5 and at the level of the lower branch sympathetic chain of the left hemithorax. In the third cadaver, the clips were

applied at the T3 level of the right hemithorax and at the T3 level lower branch sympathetic chain in the left hemithorax (Figure 1).

Electrophysiological studies of all sympathetic nerves were performed using the Medtronic Keypoint 4 (Medtronic Inc., MN, USA) electromyography device. The filter range was 1 Hz with 20 μ V amplification. In addition, the signals were processed digitally to minimize artifact. Bipolar subdermal needle electrodes were used as stimulation and recording electrodes (\varnothing 0.75 mm). The ground electrode was placed in the intercostal muscle where the TS procedure would be performed. To evaluate the different levels of sympathetic nerve activity in each hemithorax, a disposable bipolar needle electrode was placed on the nerve branch in the direct sympathetic chain through an invasive method to stimulate the nerve. Stimulated potentials from the caudal end of the nerve were recorded by stimulating at a current intensity of 10.4 to 10.6 mA and 1 ms from the cranial end of the sympathetic nerve branch. The sympathetic nerve was tested with the same stimulation technique for the presence of conduction before, after, and after removal of the clip. Observation of stimulated potentials

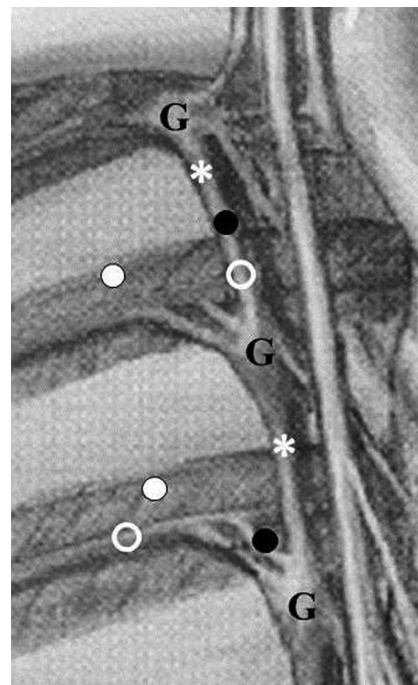


Figure 1. A schematic view showing the electrophysiological study on cadaveric material.

Black point: Clipping regions on nerves; G: Ganglion; White asterisk: Stimulation electrode; White point: Ground electrode; White ring: Recording electrode.

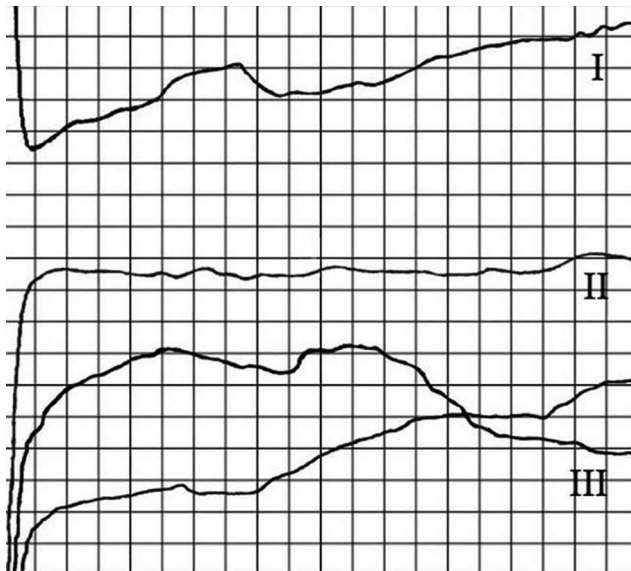


Figure 2. Evoked potentials of sympathetic nerve.
I: Evoked potentials from sympathetic nerve before clip; II: Application of a clip and no evoked potential from sympathetic nerve; III: Revert evoked potentials from sympathetic nerve after clip removal. (AVJ: 20µV/D, 1 ms/D).

after stimulation was interpreted as conduction, and the absence of potentials was interpreted as non-conduction. The sympathetic nerve stimulation study is given schematically in Figure 1.

RESULTS

The first cadaver

In the right hemithorax, recording was possible from the distal parts of the nerve, when the nerve was proximally stimulated at 10.4 mA before TS with the clip. After the clip was placed on the main branch of the T2 and T3 sympathetic nerves, which was the site of choice for craniofacial hyperhidrosis, the stimulated potentials of the same intensity could not be recorded from the caudal. Direct nerve stimulation after removal of the clip showed that there was nerve conduction.

In the left hemithorax, stimulation was continued after the clip was placed on the lower branch of the sympathetic nerve at the T3 level. After the second clip was placed on the sympathetic nerve trunk, the nerve conduction was not continued despite stimulation at the same intensity. When the clip placed on the main branch was removed, the nerve conduction continued.

The second cadaver

In the right hemithorax, before TS, the sympathetic nerve was stimulated with 10.6 mA intensity and recording was obtained. The clips were applied to the T4 and T5 sympathetic nerve levels, which were used for the treatment of axillary hyperhidrosis. After the clip was placed on the main nerve branch, the stimulated potentials of the same intensity could not be recorded. In direct nerve stimulation after removal of the clip, evoked potentials were evident and the conduction was maintained (Figure 2).

In the left hemithorax, when the clip was placed on one of the lower sympathetic branch of the T4 ganglion and stimulated with 10.6 mA stimulus, the clipping process did not block the conduction and the conduction continued. However, after the second clip was placed on the sympathetic nerve body, the nerve conduction did not persist despite stimulation of the same intensity. When the clip placed on the main branch was removed, the conduction continued.

The third cadaver

In the right hemithorax, before TS, the sympathetic nerve was stimulated at 10.4 mA and recordings were obtained. The clips were placed in the main branch of the sympathetic nerve originating from the T3 ganglion, which was used in the treatment of palmar hyperhidrosis, and the conduction discontinued. After removal of the clip, the conduction continued.

In the left hemithorax, the stimulation continued, when the clip was placed on the lower nerve branch

Table 1. Clip localization on sympathetic chain and electrophysiological findings of clipping

| | | Localization of the clips | EP after clipping | EP after removal of the clips |
|--------------------|------------------|------------------------------------|-------------------|-------------------------------|
| The first cadaver | Right hemithorax | T2 and T3 nerves above main branch | - | + |
| | Left hemithorax | T3 ganglion lower branch | + | + |
| The second cadaver | Right hemithorax | T4 and T5 nerves above main branch | - | + |
| | Left hemithorax | T4 ganglion lower branch | + | + |
| The third cadaver | Right hemithorax | T3 nerve above main branch | - | + |
| | Left hemithorax | T3 ganglion lower branch | + | + |

EP: Evoked potential; (+): Recording evoked potentials, sympathetic nerve conduction available; (-): No recording any potentials.

of the T3 ganglion. After removal of the clip from the main nerve branch, the evoked potentials could not be recorded from the caudal parts of the clipping nerve.

The localization of the clips on the sympathetic chain and the electrophysiological findings of the efficacy of the clipping on sympathetic chain are given in Table 1.

DISCUSSION

Surgical treatment to reduce sympathetic activity is to ensure interruption of nerve conduction between sympathetic ganglia and sweat glands.^[10,14] For this purpose, endoscopic TS is often used as a reliable and minimally invasive method. For sympathectomy procedure, removal of the sympathetic ganglion or cutting of the sympathetic nerve branches is preferred.^[14] In the present study, we examined the electrophysiological efficacy of sympathectomy performed at different nerve levels and evaluated nerve blockade by clipping in the sympathetic nerve of a cadaveric material. Our study results showed that clipping of the sympathetic nerve at different neural regions led to electrophysiological blockage; however conduction continued following the removal of the clips.

In the treatment of primary hyperhidrosis, the nerve is clipped with titanium clips to prevent the conduction of sympathetic nerve stimulation.^[6,7,11] In a study, although 11% of patients had relapse over a five-year period, the clinical outcomes were similar to resection (sympathectomy) or sympathetic chain transection (sympatheticotomy).^[17] It is well documented that the use of metal clips is preferred over other methods, since it is theoretically thought that nerve stimulation can be achieved by removing the clips, when undesirable side effects develop.^[11,17,18] Considering its widespread use in surgery and favorable results reported in the literature, we performed sympathectomy with clips. Sympathectomy by clipping allows nerve blockage without traumatizing the nerves. In another study, nerve conduction was shown to be prevented with a pressure of 44 g on the nerve and the pressure applied by the clips was about 150 g.^[18] However, whether the nerve conduction can be restored after the removal of the clip is still controversial.^[17]

Previous studies have demonstrated that the application of clips in the rabbit sympathetic nerve causes degeneration of the nerve after 48 h and that the nerve degenerative process continues after the removal of the clip.^[18] However, it has been suggested that if the clip is removed within two weeks following

application, conduction can continue successfully.^[8] In this electrophysiological study, we observed that the transmission of stimulation in the sympathetic nerve occurred again shortly after removal of the clip. In addition, in the histological results of our previous study,^[6] the regenerative histological process and nerve conduction continued after the removal of the clip.

Surgical intervention to T2 sympathetic nerve ganglion is widely used in the treatment of palmar hyperhidrosis.^[1,5] However, since T3 and T4 nerves provide branches to the T2 ganglion, surgical interventions involving T3 and T4 are also recommended to prevent axillary and palmar hyperhidrosis.^[18] In a TS study, sympathetic chain ablation from the T3 level was reported to be the optimal procedure for palmar hyperhidrosis.^[14] In the present study, the clip applied to any side branches of the sympathetic chain did not block the sympathetic conduction alone and that the clip should be applied on the sympathetic chain. In addition, since the present study was *ex-vivo*, there was no clinical evaluation of whether the sympathetic nerve locations selected for clipping were suitable for recurrence and compensatory hyperhidrosis.

Since the current data regarding sympathetic nerve surgery includes subjective results, more useful comparisons cannot be made between the studies.^[12] To illustrate, it has been reported that the nerve conduction study in the sympathetic truncus cannot reveal reproducible evoked potentials, although nerve conduction in the phrenic and sural nerves is measured using the same stimulation technique.^[17] This finding indicates that cadaveric sympathetic nerve conduction study may lead to non-invasive electrophysiology evaluation of conduction presence during and after sympathectomy with clips.

In conclusion, clipping of different regions of the sympathetic nerve provides electrophysiological blockage of the sympathetic nerve, and conduction continues after removal of the clips. However, the short- and long-term postoperative electrophysiological results after removal of the clips over the sympathetic nerve is still a matter of debate.

Declaration of conflicting interests

The authors declared no conflicts of interest with respect to the authorship and/or publication of this article.

Funding

This study was supported by the Scientific Research Project grant of Bursa Uludag University, Faculty of Veterinary Medicine (Project no: BUAP(V)-2015/3).

REFERENCES

1. Inan BK, Kibici K. Thoracoscopic Sympathectomy. In: Khoo LT, Ozer AF, editors. Minimally Invasive Procedures in Spine Surgery. İstanbul: Intertip; 2016. p. 97-103.
2. Hynes CF, Yamaguchi S, Bond CD, Marshall MB. Reversal of sympathetic interruption by removal of clips. *Ann Thorac Surg* 2015;99:1020-3.
3. Tedoriya T, Sakagami S, Ueyama T, Thompson L, Hetzer R. Influences of bilateral endoscopic transthoracic sympathectomy on cardiac autonomic nervous activity. *Eur J Cardiothorac Surg* 1999;15:194-8.
4. Günay S, Eser I. Tek portlu torakal sempatektomi deneyimlerimiz ve komplikasyonlarımız. *Anato J Clin Investig* 2015;9:174-7.
5. Cubuk S, Deniz S, Candas FH. Endoskopik torakoskopik sempatektomi. In: Yücel O, editör. *Palmar Hiperhidrosis*. Ankara: Merkez Repro; 2012. s. 20-5.
6. Erol MM, Salcı H, Melek H, İlhan T, Özfiliz N, Bayram AS, et al. Can Thoracic Sympathetic Nerve Damage Be Reversed? *Thorac Cardiovasc Surg* 2015;63:720-2.
7. Sugimura H, Spratt EH, Compeau CG, Kattail D, Shargall Y. Thoracoscopic sympathetic clipping for hyperhidrosis: long-term results and reversibility. *J Thorac Cardiovasc Surg* 2009;137:1370-6.
8. Fibla JJ, Molins L, Mier JM, Vidal G. Effectiveness of sympathetic block by clipping in the treatment of hyperhidrosis and facial blushing. *Interact Cardiovasc Thorac Surg* 2009;9:970-2.
9. Berkan Ö, Saba T, Önen A, Uçarı H, Doğan K. Sempatektomi sonuçlarının değerlendirilmesi. *GKDC Dergisi* 1999;7:257-60.
10. Moraites E, Vaughn OA, Hill S. Endoscopic thoracic sympathectomy. *Dermatol Clin* 2014;32:541-8.
11. Neumayer C, Zacherl J, Holak G, Függer R, Jakesz R, Herbst F, et al. Limited endoscopic thoracic sympathetic block for hyperhidrosis of the upper limb: reduction of compensatory sweating by clipping T4. *Surg Endosc* 2004;18:152-6.
12. Loscertales J, Congregado M, Jimenez-Merchan R, Gallardo G, Trivino A, Moreno S, et al. Sympathetic chain clipping for hyperhidrosis is not a reversible procedure. *Surg Endosc* 2012;26:1258-63.
13. Pohjavaara P, Telaranta T, Väisänen E. The role of the sympathetic nervous system in anxiety: Is it possible to relieve anxiety with endoscopic sympathetic block? *Nord J Psychiatry* 2003;57:55-60.
14. Li X, Tu YR, Lin M, Lai FC, Chen JF, Dai ZJ. Endoscopic thoracic sympathectomy for palmar hyperhidrosis: a randomized control trial comparing T3 and T2-4 ablation. *Ann Thorac Surg* 2008;85:1747-51.
15. Schick CH, Bischof G, Cameron AA, Connery CP, de Campos JR, Hashmonai M, et al. Sympathetic chain clipping for hyperhidrosis is not a reversible procedure. *Surg Endosc* 2013;27:3043.
16. Panhofer P, Ringhofer C, Gleiss A, Jakesz R, Prager M, Bischof G, et al. Quality of life after sympathetic surgery at the T4 ganglion for primary hyperhidrosis: clip application versus diathermic cut. *Int J Surg* 2014;12:1478-83.
17. Thomsen LL, Mikkelsen RT, Derejko M, Schröder HD, Licht PB. Sympathetic block by metal clips may be a reversible operation. *Interact Cardiovasc Thorac Surg* 2014;19:908-13.
18. Candas F, Gorur R, Haholu A, Yiyit N, Yildizhan A, Gezer S, et al. The effects of clipping on thoracic sympathetic nerve in rabbits: early and late histopathological findings. *Thorac Cardiovasc Surg* 2012;60:280-4.