

Case Report / Olgu Sunumu

## Robotic redo mitral valve replacement combined with dysfunctional amplatzer plug resection on a beating heart

*Atan kalpte robotik redo mitral kapak replasmanı ile birlikte disfonksiyonel amplatzer plug çıkarılması*

Cengiz Bolcal<sup>1</sup>, Murat Kadan<sup>1</sup>, Emre Kubat<sup>1</sup>, Gökhan Erol<sup>1</sup>, Karabacak Kubilay<sup>1</sup>

Department of Cardiovascular Surgery, Health Sciences University, Gülhane Training and Research Hospital, Ankara, Turkey

### ABSTRACT

Redo-cardiac surgery is associated with high morbidity and mortality rates. Although redo surgery are relative contraindications for robotic surgery, robotic redo mitral valve surgery has been performed with endo-aortic occlusion techniques and on fibrillated heart successfully. Beating heart mitral valve surgery is another well-known option for redo cardiac surgery practice. Robotic beating heart surgery is not well-studied before. As a new point of view to robotic reoperation surgery, herein, we aimed to present a case who underwent redo robotic mitral valve replacement combined with dysfunctioned amplatzer plug resection on a beating heart.

**Keywords:** Amplatzer plug, beating heart, redo-cardiac surgery, robotic surgical procedure.

Resternotomy is a challenging issue due to its high risk for myocardial injury, possible graft injuries, and dense adhesions. Although previous sternotomy or right thoracotomy are considered as relative contraindications for robotic surgery, robot-assisted redo mitral valve (MV) cases have been described in the literature.<sup>[1,2]</sup> These cases were performed on an arrested heart using an endoaortic occlusion balloon (EAOB). More recently, Güllü et al.<sup>[3]</sup> reported their results about robotic cardiac surgery without cross-clamping. In this paper they used fibrillated heart technique safely, with good results. However, robotic redo MV surgery (MVS) on a beating heart has not been reported in the literature.

### ÖZ

Redo kalp cerrahisi, yüksek morbidite ve mortalite oranları ile ilişkilidir. Her ne kadar robotik cerrahi için reoperasyonlar göreceli kontrendikasyonlar olsa da, robotik redo mitral kapak cerrahisi endo-aortik oklüzyon teknikleriyle ve fibrilasyondaki kalp üzerinde başarıyla uygulanmaktadır. Atan kalpte mitral kapak cerrahisi ise redo kalp cerrahisi pratiğinde iyi bilinen diğer bir alternatiftir. Atan kalpte robotik kalp cerrahisi ise rutinde uygulanan ve iyi bilinen bir uygulama değildir. Bu yazımızda, robotik reoperasyon cerrahisine yeni bir bakış açısı katarak, atan kalpte robotik mitral kapak replasmanı ile birlikte disfonksiyonel amplatzer tıkaç rezeksiyonu yapılan bir olguyu sunuyoruz.

**Anahtar sözcükler:** Amplatzer tıkaç, atan kalp, redo-kalp cerrahisi, robotik cerrahi prosedür,

We present the case of a patient with a dysfunctional mitral prosthesis and Amplatzer plug, inserted in for paravalvular leak (PVL), who underwent totally robot-assisted redo MVS on a beating heart.

### CASE REPORT

A 51-year-old man who had prosthetic MV dysfunction and severe PVL was admitted to our clinic. His medical history included a mitral commissurotomy performed via left anterior thoracotomy in another center in 1998. The patient was also underwent mechanical MV replacement with sternotomy secondary to severe mitral stenosis in 2000. In the second operation, right pneumothorax occurred,

Received: December 25, 2020 Accepted: May 18, 2021 Published online: July 26, 2021

**Correspondence:** Emre Kubat, MD, SBÜ, Gülhane Eğitim ve Araştırma Hastanesi, Kalp ve Damar Cerrahisi Kliniği, 06010 Etilik, Ankara, Türkiye.

Tel: +90 312 - 304 52 11 e-mail: ekubat@gmail.com

### Cite this article as:

Bolcal C, Kadan M, Kubat E, Erol G, Kubilay K. Robotic redo mitral valve replacement combined with dysfunctional amplatzer plug resection on a beating heart. Turk Gogus Kalp Dama 2021;29(3):391-394

©2021 All right reserved by the Turkish Society of Cardiovascular Surgery.

This is an open access article under the terms of the Creative Commons Attribution-NonCommercial License, which permits use, distribution and reproduction in any medium, provided the original work is properly cited and is not used for commercial purposes (<http://creativecommons.org/licenses/by-nc/4.0/>).

and chest tube drainage was performed. After valve replacement, he was diagnosed severe hemolysis secondary to PVL. Two treatment attempts with an amplatzer plug were included in his history, but all of them were unsuccessful. These attempts failed due to the generation of partial valvular dehiscence. The patient presented for third-time surgery to our center with severe dyspnea and continuous palpitation. Atrial fibrillation was confirmed by an electrocardiogram. Transesophageal echocardiography (TEE) revealed a dilated left atrium (LA) (62 mm), increased pulmonary artery systolic pressure (45 mmHg), a dysfunctional MV prosthesis secondary to one stuck leaflet (transmitral gradient: 28/15 mmHg), and severe mitral PVL. A moderate atrial septal defect was also seen on TEE, probably secondary to the amplatzer device instrumentation. There were not any findings that indicated endocarditis. Coronary angiography, computed tomography, and laboratory test results were non-specific, except moderate hemolytic anemia. Written informed consent was obtained from the patient.

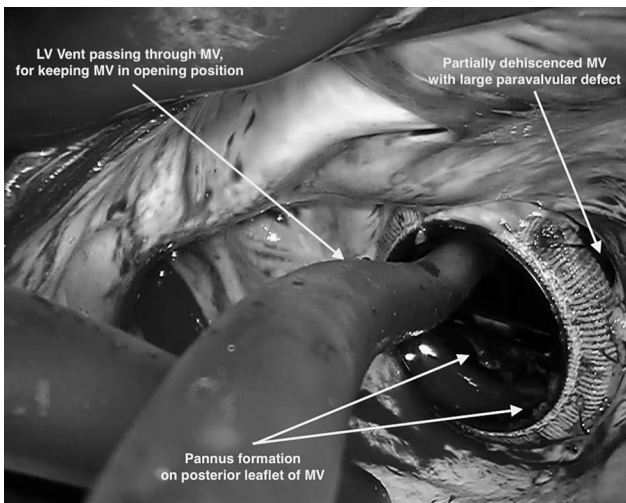
### Surgical procedure

DaVinci SI System (Intuitive Surgical Inc., CA, USA) was used. Surgical setup was almost same as detailed in our previous papers.<sup>[4,5]</sup> Briefly; right internal jugular vein was cannulated percutaneously for superior cava decompression. Common femoral artery and vein were also cannulated through 3 cm oblique groin incision with the Seldinger method by TEE guidance. After setup, Trendelenburg position

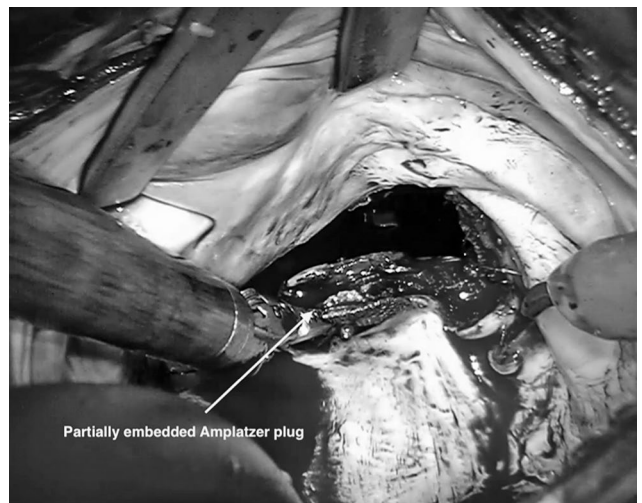
was used at an approximately 20-30 degree angle just before docking. A 30-degree endoscope was introduced to pleural cavity through the service port. Operative field was flooded with carbon dioxide. Cardiopulmonary bypass (CPB) was initiated, and the heart was decompressed with venous suction (-20 to -40 mmHg) in mild hypothermia (34°C).

After the cardiac adhesions were dissected, left atriotomy was performed through an interatrial groove on beating heart. Under TEE guidance, a vent catheter was pushed forward to left ventricle (LV) through the MV, to provide the MV at opening position. This maneuver provided LV drainage to the LA rather than the ascending aorta; therefore, the blood flow and also the possible air bubbles could not deliver into the systemic circulation. The LV vent was not removed until operation was completed. It was even placed into new prosthetic valve leaflets during implantation. An additional LA vent was also inserted into pulmonary vein (Figure 1).

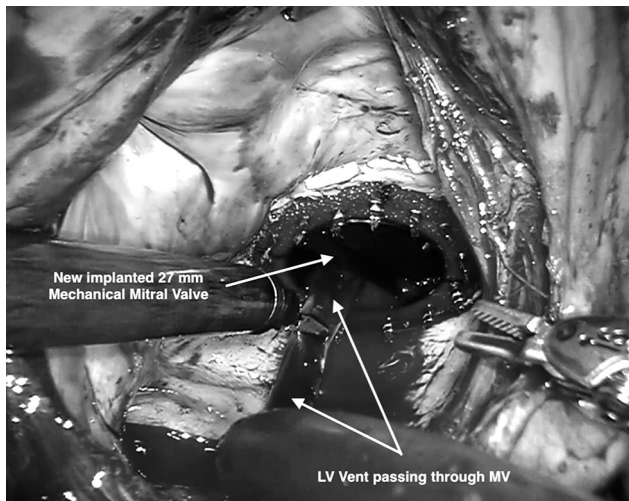
The dysfunctional prosthetic MV and large paravalvular defect were clearly visualized. There was a large pannus formation on the posterior leaflet, blocking its mobility. The valve was also partially dehiscent from mitral annulus (Figure 1). The previous operation was performed with polypropylene running suture technique. There were not any infected tissue, but culture samples were again taken for microbiologic analysis. After valve removal, the amplatzer plug was visualized partially embedded into the posterior annulus and removed carefully (Figure 2). The LA and the LV were irrigated to remove debris. Atrially placed pledgetted U-stitch sutures were inserted along



**Figure 1.** Dysfunctional, partially dehiscent mitral valve which were implanted using polypropylene running suture. Pannus formation and large paravalvular defect may also be seen. Left ventricular vent also passing through mitral valve.



**Figure 2.** A partially embedded Amplatzer plug seen after valve removal.



**Figure 3.** An image of new implanted mitral valve prosthesis.

the mitral annulus. A 27-mm Medtronic Open Pivot™ mechanical heart valve (Medtronic Inc., MN, USA) was introduced from working port, and the sutures were tied with CorKnot® (LSI Solutions Inc., NY, USA) system. An LV vent catheter was inserted into anterior leaflet of the new prosthesis before implantation to keep one leaflet open (Figure 3). Atrial septal defect was closed primarily, and LA was closed as usual. Transesophageal echocardiography was performed to assess valve functions and air removal. After de-airing procedure, LV vent was removed, and LA was closed completely. Operation were terminated with standardized techniques. CPB time was 127 min. Control TEE revealed a functional prosthetic valve without PVL.

Postoperative course was uneventful. Patient was weaned from mechanical ventilator in 4 h. Echocardiography revealed functional mechanical valve on postoperative Day 3. Microbiologic results were excluded endocarditis. Patient was discharged with warfarin treatment on postoperative Day 4 without any complications.

## DISCUSSION

Although previous sternotomy and thoracotomy are considered relative contraindications for robotic surgery, robot-assisted reoperations can be successfully performed.<sup>[3,6]</sup> For redo operations, main goals of robotic surgery are to avoid sternotomy, to use highly mobile instruments, to enable high-definition visualization, and to decrease CPB time by operating on the “target field only”. In this regard, aortic cross-clamping (ACC) is a major problem due to dense adhesions around the aorta that cannot be dissected with a robotically

approach. Endoaortic occlusion balloon seems to be useful for these patients; however, it poses serious complication risks associated with endoaortic balloon itself, such as implantation and fixing problems, increased dissection incidence, and cerebrovascular events secondary to balloon migration.<sup>[7]</sup> Current literature includes few cases of robotic redo cardiac operations on an arrested heart using EAOB.<sup>[2]</sup> In our case, we preferred not to use an endoaortic balloon due to possible complications detailed above.

Ventricular fibrillation (VF) of the heart is another option instead of ACC.<sup>[3]</sup> It is obviously a good alternative and may safely be used in daily practice for these patients. On the other hand, many authors have concluded that myocardial energy consumption reaches its highest level in VF.<sup>[8]</sup> Myocardial shear stress is also higher in a VF heart than in a beating or arrested heart.<sup>[8]</sup> Therefore, we did not use VF in our patient.

Beating-heart surgery is the last option for redo patients. There are some reports about conventional beating-heart MV surgery in literature.<sup>[9]</sup> We use robotic beating-heart approaches in our daily practice except for patient with significant aortic stenosis or insufficiency, severe generalized vascular disease and previous right thoracotomy.

For beating-heart surgery, air embolism and ventricular distention are major issues to be considered. We defined three important steps for preventing air embolism. First step is patient positioning: Trendelenburg position should be reached before docking. Second step includes insertion of a ventricular vent to LV before opening the LA completely. With this maneuver, MV is kept in the opening position, resulting in a lower LA pressure than ascending aorta; therefore, the LV blood and possible air bubbles flow into LA rather than into systemic circulation throughout surgery. In last step, LV vent catheter should be inserted into new prosthetic valve or ring before complete implantation, to provide the MV in opening position. In our case, neurological complications were not observed, and an uneventful postoperative period was ensured.

Most important limitations of robotic redo beating heart surgery may include; concomitant cardiac surgery such as coronary artery bypass and/or aortic valve surgery, significant aortic insufficiency, severe generalized vascular disease which may affect peripheral cannulation, dense adhesions such as previous right thoracotomy.

In conclusion, robot-assisted redo MVS on a beating heart is feasible and may be safely performed

by experienced surgeons with perfect visualization in selected patients in experienced centers.

#### **Declaration of conflicting interests**

The authors declared no conflicts of interest with respect to the authorship and/or publication of this article.

#### **Funding**

The authors received no financial support for the research and/or authorship of this article.

#### **REFERENCES**

1. Chitwood WR Jr. Robotic mitral valve surgery: Overview, methodology, results, and perspective. *Ann Cardiothorac Surg* 2016;5:544-55.
2. Patel H, Lewis CTP, Stephens RL, Angelillo M, Sibley DH. Minimally invasive redo mitral valve replacement using a robotic-assisted approach. *Innovations (Phila)* 2017;12:375-7.
3. Güllü AÜ, Şenay Ş, Ersin E, Demirhisar Ö, Whitham T, Koçyiğit M, et al. Robotic-assisted cardiac surgery without aortic cross-clamping: A safe alternative approach. *J Card Surg* 2021;36:165-8.
4. Bolcal C, Kadan M, Kubat E, Erol G, Doğanç S. Surgical treatment of a left ventricular apical thrombus via robotic surgery. *J Card Surg* 2019;34:216-8.
5. Kadan M, Kubat E, Erol G, Karabacak K, Akyol FB, Yıldırım V, et al. Early- and mid-term results of cryoablation of atrial fibrillation concomitant with robotic mitral valve surgery. *Anatol J Cardiol* 2021;25:266-72.
6. Spiller R, Symalla T, McCrorey M, Balkhy HH. Robotic-assisted third-time redo mitral valve replacement. *Ann Thorac Surg* 2019;108:e245-e247.
7. Mazine A, Pellerin M, Lebon JS, Dionne PO, Jeanmart H, Bouchard D. Minimally invasive mitral valve surgery: Influence of aortic clamping technique on early outcomes. *Ann Thorac Surg* 2013;96:2116-22.
8. Lee JH, Lee JE, Shin J, Song IK, Kim HS, Kim CS, et al. Clinical implications of hypothermic ventricular fibrillation versus beating-heart technique during cardiopulmonary bypass for pulmonary valve replacement in patients with repaired tetralogy of Fallot. *Interact Cardiovasc Thorac Surg* 2017;25:370-6.
9. Elghany Elsherif MA, Salama Ayyad MAK, Elsayy H, Elwahab AA. Outcome of pump assisted beating mitral valve replacement in patients with chronic severe mitral regurgitation and left ventricular dysfunction. A clinical randomized trial. *Journal of the Egyptian Society of Cardio-Thoracic Surgery* 2018;26:257-63.