

## Investigating the protective effect of glutamine against cerebral ischemia and bilateral carotid occlusion in rats

*Glutaminin sıçanlarda serebral iskemi ve bilateral karotis oklüzyonuna karşı koruyucu etkisinin araştırılması*

Shiraslan Bakhshaliyev<sup>1,2</sup>, Ergin Arslanoğlu<sup>1,3</sup>, Görkem Çitoğlu<sup>1,2</sup>, Mehmet Akif Önalın<sup>1,4</sup>, Kaan Altunyuva<sup>1,4</sup>, Çağla Canbay Sarılar<sup>1,5</sup>, Canan Küçükgergin<sup>6</sup>, Semra Doğru-Abbasoğlu<sup>6</sup>, Tuğçe Kıran<sup>7</sup>, Nilgün Bozbuğa<sup>1</sup>

*Institution where the research was done:*  
Istanbul University Istanbul Faculty of Medicine, Istanbul, Türkiye

### Author Affiliations:

<sup>1</sup>Department of Cardiovascular Surgery, Istanbul University Istanbul Faculty of Medicine, Istanbul, Türkiye

<sup>2</sup>Department of Pediatric Cardiovascular Surgery, Istanbul Mehmet Akif Ersoy Thoracic and Cardiovascular Surgery Training and Research Hospital, Istanbul, Türkiye

<sup>3</sup>Department of Pediatric Cardiovascular Surgery, Istanbul Kartal Koşuyolu High Speciality Training and Research Hospital, Istanbul, Türkiye

<sup>4</sup>Department of Pediatric Cardiovascular Surgery, Dr. Siyami Ersek Thoracic and Cardiovascular Surgery Training and Research Hospital, Istanbul, Türkiye

<sup>5</sup>Department of Cardiovascular Surgery, Şişli Hamidiye Etfal, Education and Research Hospital, Istanbul, Türkiye

<sup>6</sup>Department of Biochemistry, Istanbul University Istanbul Faculty of Medicine, Istanbul, Türkiye

<sup>7</sup>Department of Pathology, Bezmialem Vakıf University Faculty of Medicine Hospital, Istanbul, Türkiye

### ABSTRACT

**Background:** This study aims to investigate the protective effects of glutamine against cerebral injury resulting from cerebral ischemia-reperfusion by bilateral carotid occlusion in rats.

**Methods:** Eighteen Wistar albino rats were randomly divided into three equal groups: 1) control group; 2) ischemia-reperfusion group which underwent clamping of the carotid artery for 20 min; and 3) ischemia-reperfusion + glutamine group which was treated with two doses of glutamine (1 g/kg) prior to the same clamping procedure as the ischemia-reperfusion group. All rats were sacrificed 24 h after the experiment. Their brain tissue was removed, separated into right and left hemispheres, and sent for analysis. Biochemical analysis was used to determine the oxidant parameters, antioxidant parameters, and glutathione levels in brain tissue. In the histopathological analysis of the brain tissue, ischemic markers such as red neurons, spongiosis, and satellitosis were examined.

**Results:** Biochemical examination revealed that the levels of malondialdehyde and ferric reducing antioxidant power in the ischemia-reperfusion group were significantly higher than those in the control and ischemia-reperfusion + glutamine groups ( $p<0.05$ ). The histopathological findings revealed that the levels of red neurons, satellitosis, and spongiosis in the ischemia-reperfusion group were significantly higher than those in the control group ( $p<0.05$ ). The red neuron and spongiosis levels in the ischemia-reperfusion + glutamine group were significantly higher than those in the control group ( $p<0.05$ ).

**Conclusion:** Our study findings indicate that glutamine treatment has a protective effect against ischemia-reperfusion-induced brain damage in rats.

**Keywords:** Glutamine, ischemia-reperfusion injury, rats.

### ÖZ

**Amaç:** Bu çalışmada sıçanlarda glutaminin iki taraflı karotis tıkanıklığı ile serebral iskemi-reperfüzyona bağlı serebral hasara karşı koruyucu etkileri araştırıldı.

**Çalışma planı:** On sekiz Wistar albino sıçan rastgele üç eşit gruba ayrıldı: 1) kontrol grubu, 2) karotis arterlerin 20 dk. klemplendiği iskemi-reperfüzyon grubu ve 3) iskemi-reperfüzyon grubunda olduğu üzere aynı klempleme işleminden önce iki doz glutamin (1 g/kg) ile tedavi edilen iskemi-reperfüzyon + glutamin grubu. Deneyden 24 saat sonra tüm sıçanlar sakrifiye edildi. Beyin dokuları alındı ve sağ ve sol hemisferlere ayrılıp inceleme için gönderildi. Beyin dokusunda oksidan parametreleri, antioksidan parametreleri ve glutatyon düzeylerini belirlemek üzere biyokimyasal analiz yapıldı. Histopatolojik incelemede kırmızı nöron, spongioz ve sateliosis gibi beyin dokusunda iskemik hücre hasarı bulguları araştırıldı.

**Bulgular:** Biyokimyasal inceleme iskemi-reperfüzyon grubunda malondialdehit ve ferrik indirgeyici antioksidan güç düzeyleri kontrol ve iskemi-reperfüzyon + glutamin gruplarına kıyasla anlamlı derecede yüksek bulundu ( $p<0.05$ ). Histopatolojik bulgular, iskemi-reperfüzyon grubunda kırmızı nöron, sateliosis ve spongioz düzeylerinin kontrol grubuna kıyasla anlamlı derecede yüksek olduğunu gösterdi ( $p<0.05$ ). Kırmızı nöron ve spongioz düzeyleri, iskemi-reperfüzyon + glutamin grubunda kontrol grubuna kıyasla anlamlı derecede yüksekti ( $p<0.05$ ).

**Sonuç:** Çalışma bulgularımız, glutamin tedavisinin sıçanlarda iskemi-reperfüzyon kaynaklı beyin hasarına karşı koruyucu etkisi olduğunu göstermektedir.

**Anahtar sözcükler:** Glutamin, iskemi-reperfüzyon hasarı, sıçan.

Received: December 15, 2021 Accepted: April 11, 2022 Published online: October 31, 2022

**Correspondence:** Shiraslan Bakhshaliyev, MD. İstanbul Mehmet Akif Ersoy Göğüs Kalp ve Damar Cerrahisi Eğitim ve Araştırma Hastanesi, Çocuk Kalp ve Damar Cerrahisi Kliniği, 34303 Küçükçekmece, İstanbul, Türkiye.

Tel: +90 553 - 262 60 82 e-mail: sh.bakhshaliyev@gmail.com

### Cite this article as:

Bakhshaliyev S, Arslanoğlu E, Çitoğlu G, Önalın MA, Altunyuva K, Canbay Sarılar Ç, et al. Investigating the protective effect of glutamine against cerebral ischemia and bilateral carotid occlusion in rats. *Türk Göğüs Kalp Dama* 2022;30(4):528-535

©2022 All right reserved by the Turkish Society of Cardiovascular Surgery.

This is an open access article under the terms of the Creative Commons Attribution-NonCommercial License, which permits use, distribution and reproduction in any medium, provided the original work is properly cited and is not used for commercial purposes (<http://creativecommons.org/licenses/by-nc/4.0/>).

Ischemia-reperfusion (IR) injury is defined as the paradoxical exacerbation of cellular dysfunction and death following the restoration of blood flow to previously ischemic tissues.<sup>[1]</sup> This process plays an important role in the tissue damage that occurs during myocardial and cerebral ischemia. Free oxygen radicals, polymorphonuclear leukocytes, the complement system, and endothelial cells play important roles in its pathophysiology.<sup>[2]</sup>

Cerebral ischemia is a common pathology all over the world, with high rates of mortality and severe disability. About 85% of strokes are ischemic.<sup>[3]</sup> Treating cerebral ischemia with neuron-protective therapy reduces cell damage by altering the pathophysiological process of IR injury.<sup>[4]</sup>

Glutamine is a non-essential amino acid produced in the body. Experimental studies have shown that it becomes essential in catabolic conditions.<sup>[5]</sup> As an important source of energy and essential for protein synthesis and cellular protective systems, it is a precursor for the synthesis of glutathione (GSH), a major antioxidant.<sup>[6]</sup> Glutamine protects against IR injury by increasing heat shock proteins in the tissue and directly reducing nitric oxide synthase, superoxide dismutase (SOD) activity, and proinflammatory cytokines.<sup>[7]</sup>

In the present study, we aimed to investigate the effects of glutamine, particularly its role in reducing neuronal damage and protecting against IR damage, in rats subjected to cerebral IR by bilateral carotid occlusion.

## MATERIALS AND METHODS

### Experimental model

In this study, a total of 18 Wistar albino rats were randomly divided into three equal groups including six rats in each. At three months of age, the rats had a range of body weights from 200 to 400 g. The first group was the control group, the rats in the second group were subjected to IR and not treated (IR group), and the rats in the third group were subjected to IR and treated with glutamine (IR + glutamine). The rats in all three groups were anesthetized with 80 mg/kg of Ketalar® (ketamine hydrochloride; Par Pharmaceuticals, NJ, USA) and 5 mg/kg of Rompun® (Bayer Healthcare, NJ, USA) via intraperitoneal injection. The depth of anesthesia was evaluated by administering pain stimulants in the tail every 15 min. Anesthesia was readministered as necessary at one-third of the original dose through the intramuscular route.

All surgery, injections, and blood collection were performed while the rats were under anesthesia.

### Operative technique

The rats were placed on the operating table in the supine position, and the midline of the neck was shaved. A midline incision was made. The rats in the control group underwent a subcutaneous incision and were left under surgical stress. At the end of this period, the skin was closed. The rats in the IR and IR + glutamine treatment groups underwent the same surgical procedure, until the superficial microdissection was performed. Following the subcutaneous incision, the common carotid arteries were found, freed, and restored using silk sutures. Five minute after intraperitoneal administration of 100 U/kg heparin, the common carotid arteries were occluded with bulldog clamps for 20 min. Reperfusion was achieved by removing the bulldog clamps from the carotid arteries and confirmed by observing the pulsation of the translucent carotid artery. The skin was, then, closed. Three days before the procedure, the rats in the IR + glutamine group received an intraperitoneal injection of the first dose of glutamine (1 g/kg; Dipeptiven® 200 mg/mL, Fresenius Kabi, Bad Homburg, Germany); the second dose was administered 30 min before the procedure. The rats that awakened from the anesthesia were kept alive for 24 h. Then, all rats were sacrificed by an intraperitoneal injection of 135 mg/kg of sodium pentothal (Pental Sodium, İ.E.U. Turkish Pharmaceutical Co., Istanbul, Türkiye). Their brain tissue was removed, separated into right and left hemispheres, and sent for biochemical analysis and pathological examination.

### Biochemical evaluation

*Tissue samples:* The brain tissues were washed in 0.9% sodium chloride (NaCl) and homogenized in ice-cold phosphate-buffered saline (0.01 M, pH: 7.4). The tissue homogenates were centrifuged at 600 g for 10 min at 4°C to remove any remaining non-homogenized tissue fragments and nuclear fractions. Supernatant fractions were used for biochemical analysis of the brain tissues. The SOD and GSH peroxidase (GSH-Px) activities were determined in the post-mitochondrial fractions of the tissues, which were separated by sequential centrifugation. In brief, tissue homogenates were centrifuged at 600 g for 10 min at 4°C to remove crude fractions. The supernatants were, then, centrifuged at 10,000 g for 20 min to obtain the post-mitochondrial fractions. The materials were stored at -80°C, until the analysis could be performed.

**Determination of lipid peroxide levels:** Brain lipid peroxidation was evaluated by determining thiobarbituric acid reactive substance levels. This was achieved by mixing 0.5 mL tissue samples, 0.5 mL distilled water, and 2 mL Buege-Aust reagent (26 mmol/L thiobarbituric acid and 0.92 mol/L trichloroacetic acid in 0.25 mol/L HCl) and heating the mixture in a boiling water bath for 15 min. The mixture was cooled and centrifuged at 1,000 g for 10 min, and the absorbance of the supernatant was recorded at 532 nm. The breakdown product of 1,1,3,3-tetraethoxypropane was used as the standard. The results were expressed as nmoL/mg protein.<sup>[8]</sup>

**Determination of the advanced oxidation products of protein (AOPP) levels:** To determine the AOPP levels, 40 mL of diluted brain homogenates and 160 mL of 0.2 M citric acid were put into microplate wells as the sample. Reagent blank (190 mL of 0.2 M citric acid and 10 mL of 1.16 M KI) and standard (190 mL chloramine-T as 0-100 mM in 0.2 M citric acid and 10 mL of 1.16 M KI) samples were prepared in different wells. After 2 min, the absorbance levels of the samples and standards were read at 340 nm against a reagent blank. The results were standardized by the formation of triiodide ions following the oxidation of potassium iodide with chloramine-T. The results were expressed as nmoL/mg protein.<sup>[9]</sup>

**Determination of reactive oxygen species (ROS) levels:** Brain ROS generation was measured using a fluorometric assay with dichlorofluorescein (DCF). In this assay, 1 mM 2',7'-dichlorodihydrofluorescein diacetate (DCFH2-DA, Sigma-Aldrich, St. Louis, MO, USA) diffuses passively into the cells, and the DCFH2-DA acetate groups are cleaved by intracellular esterase enzymes, yielding intracellular 2',7'-DCFH2. Reactive oxygen species oxidize DCFH2 to form a fluorescent compound, 2',7'-DCF, which was measured using a microplate fluorometer (Fluoroskan Ascent FL; Thermo Fisher Scientific Inc., Waltham, MA, USA) with an excitation of 485 nm and an emission of 538 nm. The results were expressed as relative fluorescence units (RFUs).<sup>[10]</sup>

**Determination of ferric-reducing antioxidant power (FRAP):** In the FRAP assay, a ferric-tripyridyltriazine (Fe<sup>3+</sup>-TPTZ) complex was reduced to its ferrous form and monitored by measuring the change in absorbance at 593 nm. The results were expressed as nmoL/mg protein.<sup>[11]</sup>

**Determination of GSH levels:** The GSH levels in the brain homogenates were measured spectrophotometrically using

5,5'-dithiobis-(2-nitrobenzoate) at 412 nm. The results were expressed as nmoL/mg protein.<sup>[12]</sup>

**Determination of brain enzymatic antioxidants:** The SOD activity was measured as the increase in the riboflavin-sensitized photooxidation of o-dianisidine. The assay mixture, containing potassium phosphate buffer (50 mmol/L, pH 7.8), 0.39 mmol/L riboflavin, 6 mmol/L o-dianisidine dihydrochloride, and post-mitochondrial fraction, was illuminated with 20 W fluorescent lamps at 37°C for 8 min. Absorbance readings were taken before and after 8 min of illumination at 460 nm. The SOD activity was calculated as the difference in the recorded absorbance levels. The results were expressed as units per mg of protein.<sup>[13]</sup>

The GSH-Px activity was measured using the Lawrence and Burk's<sup>[14]</sup> method. In the presence of GSH reductase and nicotinamide adenine dinucleotide phosphate (NADPH), oxidized GSH was reduced by oxidizing NADPH. The change in absorbance was followed spectrophotometrically at 340 nm at 37°C. The results were expressed as nmoL/mg protein.<sup>[14]</sup>

**Determination of protein levels:** Protein levels in brain homogenates were assayed using bicinchoninic acid, with serum albumin as the standard.<sup>[15]</sup>

### **Histopathological evaluation with hematoxylin and eosin (H&E)**

The brains were kept in pre-prepared separate jars for five days for fixation in a 10% formaldehyde solution that was adjusted to 10 times the amount for each sample. Three pieces of 2-mm-thick coronal sections were taken from each of the gross brain specimens, individually labelled, and embedded in paraffin blocks. To facilitate the evaluation of each block, at least three 2-micron-thick sections were taken from each block, and the prepared tissue samples were stained with H&E. Neuronal damage was found to have occurred in the cerebral cortex and hippocampal regions after cerebral ischemia. The histomorphological appearance of red neurons, characterized by acidophilic neuronal cytoplasm, pyknosis, and karyorrhexis, was observed in the damaged neurons. The presence of satellitosis (oligodendrocytes collected around damaged neurons) and spongiosis (spongy separation in the neuropil) in the brain tissue was evaluated. While evaluating this damage, damaged neurons were counted in five different areas under the light microscope, and the number of damaged neurons per 1 higher magnification area was determined.<sup>[16]</sup>

### Statistical analysis

Statistical analysis was evaluated using the IBM SPSS version 21.0 software (IBM Corp., Armonk, NY, USA). Descriptive data were expressed in median (min-max) or number and frequency, where applicable. Data distributions and test of normality were investigated using the Kolmogorov-Smirnov test. The significance between groups for parameters without normal distribution was compared by using the Kruskal-Wallis test. In case of significant difference between the groups, two-way comparisons were completed by using Bonferroni-corrected Mann-Whitney U test. Correlations between continuous variables were analyzed using the Spearman correlation analysis. A *p* value of <0.05 was considered statistically significant.

## RESULTS

### Biochemical findings

The brain ROS, AOPP, malondialdehyde (MDA), FRAP, and GSH levels and the SOD and GSH-Px activities of the rats in the control, IR, and IR+glutamine groups are presented in Table 1.

A statistically significant increase in MDA levels, the indicator of lipid peroxidation in oxidative stress, was observed in the IR group compared to the control group (*p*<0.05). Glutamine treatment significantly decreased the MDA levels (*p*<0.05). In the rats in the IR group, FRAP levels were increased to compensate for oxidative stress. Glutamine treatment reduced this increase to the level observed in the rats in the control group (*p*<0.05). The SOD, GSH-Px, and GSH levels were analyzed to examine which parameter arose from the increase in total antioxidant capacity. The SOD and GSH-Px levels were found to be unchanged in the IR group, although their GSH levels were increased; however, this change was not statistically significant (*p*>0.05).

### Histopathological findings

Histopathological findings, such as red neurons, satellitosis, and spongiosis, in the brain tissue and the median values for each group are presented in Table 2 and illustrated in Figure 1. An assessment of the values of the histopathological findings specific to each group revealed that the levels of red neurons, satellitosis, and spongiosis in the IR group

**Table 1. The effect of IR and IR+glutamine treatment on ROS, AOPP, MDA, FRAP, and GSH levels and SOD and GSH-Px activity in the brain tissues of rats (n=6)**

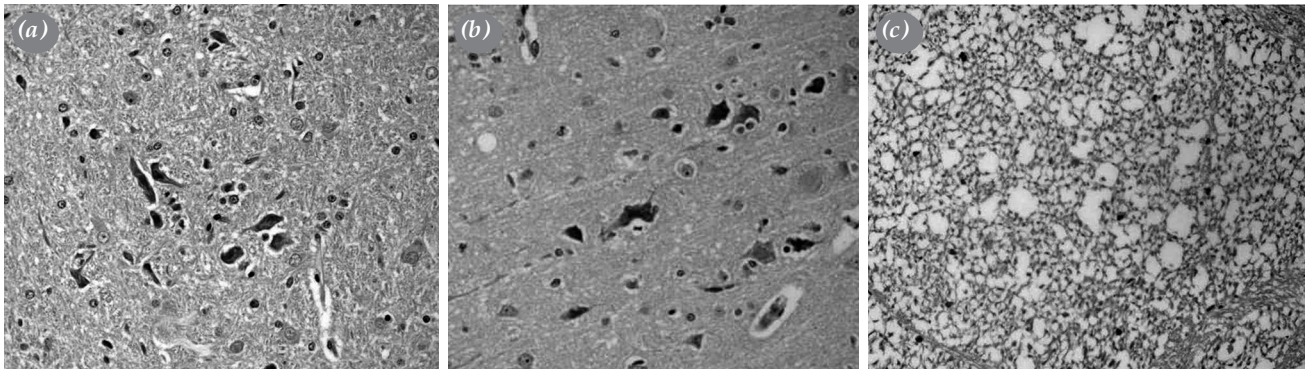
	Control		IR		IR + glutamine treatment	
	Median	Min-max	Median	Min-max	Median	Min-max
ROS (RFU)	1536	1303.0-1991.0	1584.0	1201.0-1584.0	1611.5	1267.7-2188.0
AOPP (nmol/mg protein)	34.1	25.8-44.21	45.95	27.3-63.03	27.27	11.7-72.81
MDA (nmol/mg protein)	0.68	0.56-0.82	1.14 <sup>a</sup>	0.79-1.64	0.73 <sup>b</sup>	0.47-1.10
FRAP (nmol/mg protein)	20.26	15.81-25.97	25.67 <sup>a</sup>	22.8-32.4	20.56 <sup>b</sup>	17.68-24.0
GSH (nmol/mg protein)	4.13	2.98-7.13	5.79	4.65-8.90	5.78	4.30-8.39
SOD (U/mg protein)	22.86	19.7-27.03	21.2	18.5-25.1	23.59	18.1-27.9
GSH-Px (nmol/mg protein)	109.0	100.7-130.6	111.9	136.5-144.7	115.4	106.0-124.8

IR: Ischemia-reperfusion; ROS: Reactive oxygen species; AOPP: Advanced oxidation products of protein; MDA: Malondialdehyde; FRAP: Ferric-reducing antioxidant power; GSH: Glutathione; GSH-Px: Glutathione peroxidase; SOD: Superoxide dismutase; <sup>a</sup>*p*<0.05 as compared to control; <sup>b</sup>*p*<0.05 IR and IR + glutamine treatment group.

**Table 2. Histopathological findings in brain tissues of rats treated with IR and IR+glutamine (n=6)**

	Control		IR		IR + glutamine treatment	
	Median	Min-max	Median	Min-max	Median	Min-max
Red neuron	1.0	0.0-3.0	10.50 <sup>a</sup>	6.0-12.0	5.0 <sup>a,b</sup>	4.0-7.0
Satellitosis	0.0	0.0-0.0	2.0 <sup>a</sup>	2.0-2.0	1.0	0.0-2.0
Spongiosis	5.0	0.0-1.0	3.0 <sup>a</sup>	3.0-3.0	2 <sup>a,b</sup>	1.0-2.0

IR: Ischemia-reperfusion; <sup>a</sup>*p*<0.05 as compared to control; <sup>b</sup>*p*<0.05 IR and IR + Glutamine treatment group.



**Figure 1.** (a, b) Red neurons and satellitosis phenomenon occurring after ischemia in brain tissue. (c) Post-ischemia spongiosis phenomenon in brain tissue (H&E,  $\times 400$ ).

were significantly higher than those in the control group ( $p < 0.05$ ). The red neuron and spongiosis values for the IR + glutamine treatment group were significantly higher than those of the control group ( $p = 0.001$ ,  $p = 0.003$ , and  $p = 0.001$ , respectively).

#### Correlations between biochemical and histopathological findings

The correlations between biochemical and histopathological findings are presented in Table 3. There were moderately positive correlations between the red neuron values and those of MDA and FRAP, and a very strong positive correlation between the satellitosis and spongiosis values ( $p < 0.05$ ,  $r = 0.52/0.578$ ). Strong positive correlations were found between the spongiosis value ( $p < 0.01$ ,  $r = 0.615/0.693$ ) and the MDA and FRAP values and between the spongiosis and satellitosis values ( $p < 0.01$ ,  $r = 0.885/0.902$ ) (Figure 2).

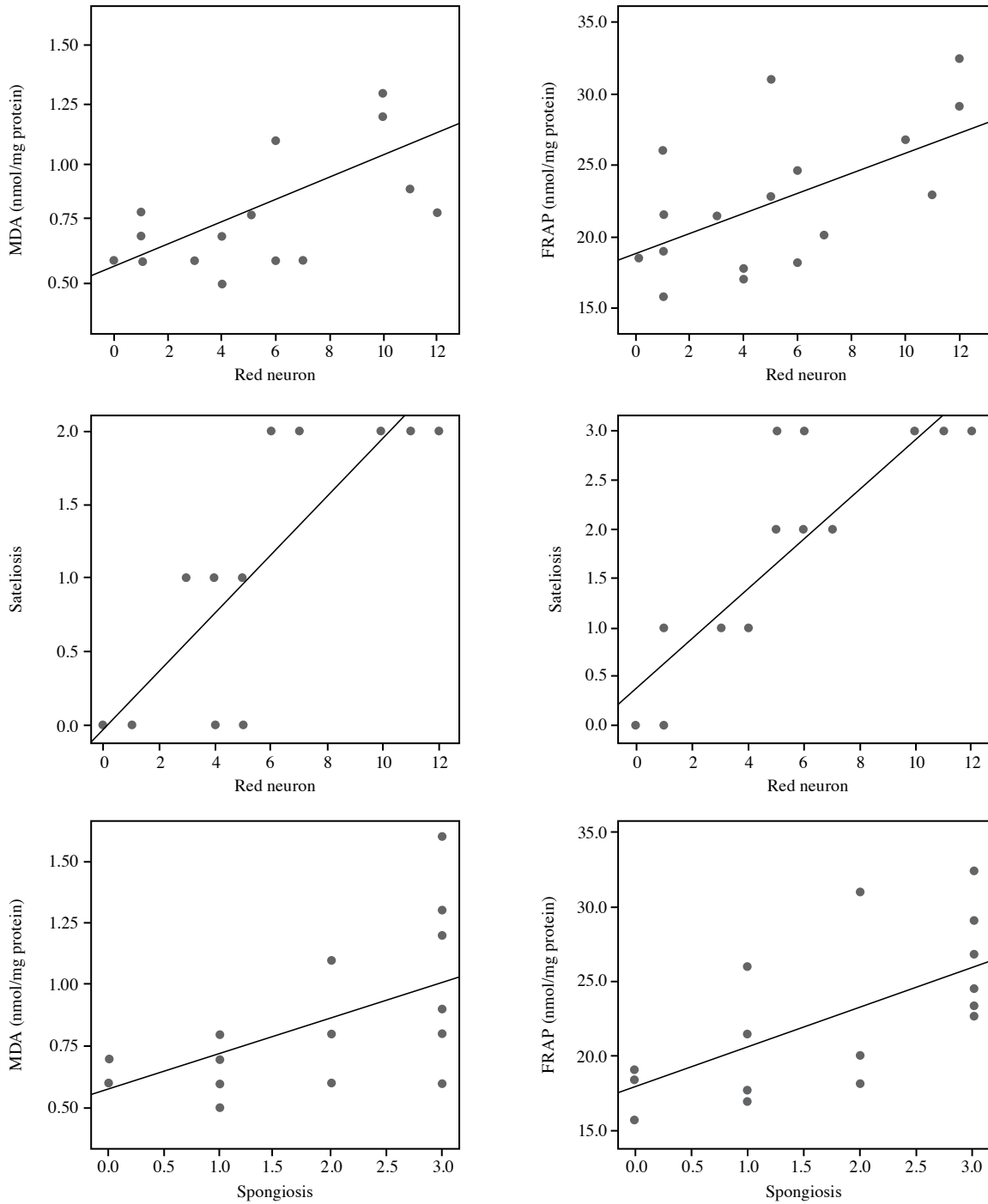
#### DISCUSSION

Brain ischemia is one of the most common causes of injury and death in adults around the world. Stroke may occur due to infarction in the brain as a result of atherosclerosis of the intracerebral arteries, as well as parenchymal hemorrhage or an embolism originating from the carotid artery or the heart. Atherosclerosis of the supra-aortic vessels is an important cause of recurrent ischemic strokes and constitutes 20% of all strokes.<sup>[17,18]</sup> Aortic arch aneurysms can be repaired with interventions involving temporary interruption of cerebral circulation; however, as the central nervous system is highly sensitive to anoxia, the neurological damage that may occur after such operations is the most feared complication. Strategies such as hypothermic arrest and selective cerebral perfusion have been developed to protect the brain from

**Table 3. Correlation coefficients between histopathological findings and biochemical results**

Spearman's Rho	Red Neuron	Satellitosis	Spongiosis
ROS	-0.362	-0.415	-0.452
AOPP	0.112	-0.053	0.386
MDA	0.582*	0.409	0.615**
FRAP	0.578*	0.459	0.693**
GSH	0.466	0.377	0.427
SOD	-0.245	-0.084	-0.366
GSH-Px	0.278	0.060	0.203
Red neuron	1.00	0.885**	0.902**
Satellitosis	0.885**	1.00	0.760*
Spongiosis	0.902**	0.760**	1.00

ROS: Reactive oxygen species; AOPP: Advanced oxidation products of protein; MDA: Malondialdehyde; FRAP: Ferric-reducing antioxidant power; GSH: Glutathione; SOD: Superoxide dismutase; GSH-Px: Glutathione peroxidase; IR: Ischemia-reperfusion; \*  $p < 0.05$ ; \*\*  $p < 0.01$ .



**Figure 2.** Correlation graphs between biochemical parameters (MDA and FRAP) and histopathological findings (red neuron and spongiosis).

MDA: Malondialdehyde; FRAP: Ferric-reducing antioxidant power.

global cerebral ischemia during such procedures, but restoring circulation can exacerbate damage.<sup>[19]</sup>

The literature includes many clinical and experimental studies on drugs and methods which

may protect the brain by reducing IR damage. Several studies have shown that glutamine reduces IR damage in many tissues and organs, but there are a limited number of studies that have shown its effects on IR injury in brain tissue.<sup>[20]</sup>

In the current study, we used Wistar albino rats as the experimental animal model, as small rodents, particularly rats, are preferred in constructing the cerebral ischemia model due to their similarity to human cerebral physiology and vascularization. The rodents' small brain masses also provide good fixation in procedures, such as paraffin embedding and frozen sectioning.<sup>[21]</sup> We found the rat model appropriate owing to its cost, easy maintenance, and intervention advantages.

Ugurlucan et al.<sup>[22]</sup> demonstrated that intraperitoneal administration of glutamine at a dose of 1 g/kg in the diabetic rats increased heat shock protein 70 levels significantly in cardiovascular tissues compared to those of the control group, proving its protective effect on cardiovascular tissues. Salman et al.<sup>[23]</sup> also showed a significant decrease in tumor necrosis factor-alpha, interleukin (IL)-6, IL-10 levels in damaged lung tissue in rats given 1 g/kg of oral glutamine, as well as a significant decrease in the total lung injury score on histopathological examination. Similarly, Xu et al.<sup>[24]</sup> found statistically significant differences in GSH, MPO, and MDA levels in liver function tests after oral administration of 5 mg/kg glutamine following liver injury in rats. In addition, significant differences were also reported in IL-1 $\beta$ , intracellular adhesion molecule levels, and histopathological evaluations. In the present study, we administered glutamine intraperitoneally in two doses of 1 g/kg. We preferred the intraperitoneal route, as it makes it easier to adjust doses and does not require additional procedures for application.<sup>[22]</sup>

Vasconcelos et al.<sup>[20]</sup> induced cerebral ischemia in rats by clamping the common carotid artery for 30 min and they, then, performed reperfusion by removing the clamp. The glutamine administered was found to have statistically significantly altered the red neuron scores and water content of the brain tissue. In our study, we chose the global ischemia model, as it causes more pronounced and widespread ischemia than cerebral ischemia models. We implemented a longer reperfusion time (24 h) to allow ischemic histopathological changes in neurons to occur.

In our study, when we conducted a histopathological examination of the hippocampus and cerebral cortex, the areas of the brain most sensitive to ischemia, by staining the brain tissue with H&E, we found that the levels of red neurons and spongiosis increased statistically significantly in the IR group compared to those of the control

group and decreased statistically significantly in the IR + glutamine group. We found that the satellitosis values of both the IR and IR + glutamine groups were higher than that of the control group. However, the comparison of the IR and IR + glutamine treatment groups was not statistically significant.

The MDA, a lipid peroxidation product, is used as a biomarker of oxidative stress.<sup>[9]</sup> In our study, MDA levels were found to be statistically significantly higher in the IR group compared to the control group. Glutamine treatment was found to statistically decrease MDA levels. We also found the levels of AOPP, an indicator of proteins damaged in oxidative stress,<sup>[9]</sup> to be higher in the IR group than in the control group, but lower in the IR + glutamine group than the IR group; however, these findings were not statistically significant.

Regarding antioxidant status in the brain tissues of our experimental model, we found a statistically significant increase in the FRAP levels in the IR group, which compensated for the increase in oxidative stress. However, glutamine treatment significantly reduced this increase.

According to the correlation between histopathological findings and biochemical parameters, we found positive correlations, particularly between FRAP and MDA levels and the numbers of ischemic neurons. This finding supports the conclusion that glutamine therapy protects against IR damage.

Nonetheless, the lack of clinical and electrophysiological examinations in animals after the experiment is the main limitation to this study.

In conclusion, our study results indicate that ischemia-reperfusion damages brain tissue and glutamine treatment protects against this damage. Based on these results, the next step should be to conduct clinical trials. Such trials are needed to ensure that glutamine is safe for clinical use, particularly in human patients who suffer from or are at risk of cerebral ischemia.

**Acknowledgements:** The study is the residency thesis of Shiralan Bakhshaliyev, MD.

**Ethics Committee Approval:** The study protocol was approved from the Istanbul University Animal Experiments Local Ethics Committee (01/2017-39785).

**Data Sharing Statement:** The data that support the findings of this study are available from the corresponding author upon reasonable request.

**Author Contributions:** Idea/concept: S.B., C.K., N.B.; Design: S.B., C.K.; Control/supervision: C.K., S.D.A.; Data collection and interpretation: S.B., E.A., G.C., M.A.O., K.A., C.C.S., T.K.; Literature review: S.B., E.A., G.C., M.A.O., K.A., C.C.S.; Writing the article: S.B., C.K.; Critical review: S.B., C.K., S.D.A.; References and fundings: S.B., E.A.

**Conflict of Interest:** The authors declared no conflicts of interest with respect to the authorship and/or publication of this article.

**Funding:** The study was supported by the Istanbul University Scientific Research Projects Coordination Unit (Project ID: 24408).

## REFERENCES

1. Li C, Jackson RM. Reactive species mechanisms of cellular hypoxia-reoxygenation injury. *Am J Physiol Cell Physiol* 2002;282:C227-41.
2. Acworth IN, Bailey B. Reactive oxygen species. In: Acworth IN, Bailey B, editors. *The handbook of oxidative metabolism*. Massachusetts: ESA Inc., 1997. p. 1-4.
3. Sveinsson OA, Kjartansson O, Valdimarsson EM. Cerebral ischemia/infarction - epidemiology, causes and symptoms. *Laeknabladid* 2014;100:271-9.
4. Yamashita T, Abe K. Recent progress in therapeutic strategies for ischemic stroke. *Cell Transplant* 2016;25:893-8.
5. Miller AL. Therapeutic considerations of L-glutamine: A review of the literature. *Altern Med Rev* 1999;4:239-48.
6. Tapiero H, Mathé G, Couvreur P, Tew KD. II. Glutamine and glutamate. *Biomed Pharmacother* 2002;56:446-57.
7. Wischmeyer PE, Kahana M, Wolfson R, Ren H, Musch MM, Chang EB. Glutamine reduces cytokine release, organ damage, and mortality in a rat model of endotoxemia. *Shock* 2001;16:398-402.
8. Buege JA, Aust SD. Microsomal lipid peroxidation. *Methods Enzymol* 1978;52:302-10.
9. Hanasand M, Omdal R, Norheim KB, Gøransson LG, Brede C, Jonsson G. Improved detection of advanced oxidation protein products in plasma. *Clin Chim Acta* 2012;413:901-6.
10. Wang H, Joseph JA. Quantifying cellular oxidative stress by dichlorofluorescein assay using microplate reader. *Free Radic Biol Med* 1999;27:612-6.
11. Benzie IF, Strain JJ. The ferric reducing ability of plasma (FRAP) as a measure of "antioxidant power": The FRAP assay. *Anal Biochem* 1996;239:70-6.
12. Beutler E, Duron O, Kelly BM. Improved method for the determination of blood glutathione. *J Lab Clin Med* 1963;61:882-8.
13. Mylroie AA, Collins H, Umbles C, Kyle J. Erythrocyte superoxide dismutase activity and other parameters of copper status in rats ingesting lead acetate. *Toxicol Appl Pharmacol* 1986;82:512-20.
14. Lawrence RA, Burk RF. Glutathione peroxidase activity in selenium-deficient rat liver. *Biochem Biophys Res Commun* 1976;71:952-8.
15. Smith PK, Krohn RI, Hermanson GT, Mallia AK, Gartner FH, Provenzano MD, et al. Measurement of protein using bicinchoninic acid. *Anal Biochem* 1985;150:76-85.
16. Mărgăritescu O, Mogoantă L, Pirici I, Pirici D, Cernea D, Mărgăritescu C. Histopathological changes in acute ischemic stroke. *Rom J Morphol Embryol* 2009;50:327-39.
17. Güler M, Ulusoy Bozbuğa N, Kırallı K, Eren E, Erdem Toker M, Keleş C, et al. Karotis arter stenozunda cerrahi tedavi ilkeleri: Koşuyolu deneyimi. *Damar Cerrahi Dergisi* 2001;10:111-9.
18. Alp BN, Bozbuğa N, Yakut C. Effect of carotid endarterectomy on chronic ocular ischemic syndrome in bilateral carotid artery disease complicated with transient ischemic attacks. *J Clin Res* 2009;12:1-7.
19. Ziya Apaydın A. Antegrade cerebral perfusion: A review of its current application. *Turk Gogus Kalp Dama* 2021;29:1-4.
20. Vasconcelos PR, Guimaraes AB, Campelo MW, Vasconcelos PR, Guimaraes SB. Preconditioning with L-alanyl-glutamine upon cerebral edema and hippocampus red neurons counting in rats subjected to brain ischemia/reperfusion injury. *Acta Cir Bras* 2015;30:199-203.
21. Prieto-Arribas R, Moreno-Gutiérrez A, Simal-Hernández P, Pascual-Garvi JM, Matías-Guiu J, Roda JM, et al. Experimental models of cerebral ischemia. *Rev Neurol* 2008;47:414-26.
22. Ugurlucan M, Erer D, Karatepe O, Ziyade S, Haholu A, Gungor Ugurlucan F, et al. Glutamine enhances the heat shock protein 70 expression as a cardioprotective mechanism in left heart tissues in the presence of diabetes mellitus. *Expert Opin Ther Targets* 2010;14:1143-56.
23. Salman AE, Yetişir F, Kılıç M, Onal O, Dostbil A, Zeybek D, et al. The impact of pretreatment with bolus dose of enteral glutamine on acute lung injury induced by oleic acid in rats. *J Anesth* 2014;28:354-62.
24. Xu F, Dai CL, Peng SL, Zhao Y, Jia CJ, Xu YQ. Preconditioning with glutamine protects against ischemia/reperfusion-induced hepatic injury in rats with obstructive jaundice. *Pharmacology* 2014;93:155-65.