

## Off-pump surgical thrombectomy for subacute right atrial thrombus: A case report

*Subakut sağ atriyal pıhtının off-pump cerrahi trombektomisi: Olgu sunumu*

Michael Shang<sup>1</sup>, Ulas Kumbasar<sup>2</sup>, Rajesh B. Sekar<sup>1</sup>, Pramod Bonde<sup>1</sup>

*Institution where the research was done:*  
Yale University School of Medicine, New Haven, USA

*Author Affiliations:*

<sup>1</sup>Department of Cardiothoracic Surgery, Yale University School of Medicine, New Haven, USA

<sup>2</sup>Department of Thoracic Surgery, Hacettepe University Faculty of Medicine, Ankara, Türkiye

### ABSTRACT

Right heart thrombi can be seen in a minority of patients with acute pulmonary embolism and are associated with an increased mortality risk. The optimal treatment option comprises thrombolysis or surgical thrombectomy either with catheter-based interventions or with open surgery. Open right atrial thrombectomy is usually performed under cardiopulmonary bypass due to the need for concomitant pulmonary embolectomy. Nevertheless, cardiopulmonary bypass has major drawbacks such as the risk of stroke, coagulopathy, and myocardial and respiratory dysfunction, particularly in high-risk patients. Herein, we report a case of successful off-pump surgical thrombectomy performed for the right atrial clot-in-transit following failure of the catheter-based intervention.

**Keywords:** Surgery, thrombectomy, thrombus.

Right heart thrombi (RHT) are only reported in <4% of patients with acute pulmonary embolism (PE), but are associated with an increased mortality risk compared to PE without RHT.<sup>[1,2]</sup> Anticoagulation alone is indicated for PE without hemodynamic instability, while previous studies have suggested a mortality benefit with thrombolysis or surgical thrombectomy in patients with RHT, particularly when right ventricular (RV) dysfunction is present.<sup>[2]</sup> Moreover, catheter-based interventions with devices such as the AngioVac™ system (AngioDynamics Inc., Latham, NY, USA) have recently gained interest in evacuating fresh, mobile

### ÖZ

Sağ kalp trombüsleri akut pulmoner emboli hastalarının çok az bir kısmında görülebilir ve yüksek mortalite riski ile ilişkilidir. Optimal tedavi seçeneği, tromboliz veya kateter bazlı girişimler veya açık cerrahi ile trombektomi içerir. Açık sağ atriyal trombektomi, eşlik eden pulmoner embolectomi ihtiyacı nedeniyle genellikle kardiyopulmoner baypas altında yapılır. Bununla birlikte, kardiyopulmoner baypasın, özellikle yüksek riskli hastalarda, inme riski, koagülopati ve miyokardiyal ve solunum fonksiyon bozukluğu gibi önemli dezavantajları vardır. Bu yazıda, kateter bazlı girişimin başarısız olmasını takiben geçiş halindeki sağ atriyal pıhtı için gerçekleştirilen başarılı bir off-pump cerrahi trombektomi olgusu sunuldu.

**Anahtar sözcükler:** Cerrahi, trombektomi, trombüs.

central venous thrombi. As such, consensus statements from the PERT Consortium™ suggest surgical or mechanical thrombectomy for PE with a large right heart clot burden or when medical thrombolysis is contraindicated.<sup>[3]</sup>

Open right atrial (RA) thrombectomy is typically performed under cardiopulmonary bypass (CPB) due to the need for concomitant pulmonary embolectomy. However, CPB is associated with the risk of stroke, coagulopathy, and myocardial and respiratory dysfunction. In this article, we report a case of off-pump surgical thrombectomy performed for RA

**Corresponding author:** Ulas Kumbasar.

E-mail: ulaskumbasar@gmail.com

Doi: 10.5606/tgkdc.dergisi.2023.24477

**Received:** December 01, 2022

**Accepted:** March 12, 2022

**Published online:** April 28, 2023

**Cite this article as:** Shang M, Kumbasar U, Sekar RB, Bonde P. Off-pump surgical thrombectomy for subacute right atrial thrombus: A case report. Turk Gogus Kalp Dama 2023;31(2):282-285. doi: 10.5606/tgkdc.dergisi.2023.24477.

©2023 All right reserved by the Turkish Society of Cardiovascular Surgery.



This is an open access article under the terms of the Creative Commons Attribution-NonCommercial License, which permits use, distribution and reproduction in any medium, provided the original work is properly cited and is not used for commercial purposes (<http://creativecommons.org/licenses/by-nc/4.0/>).

clot-in-transit after the failure of the catheter-based intervention.

## CASE REPORT

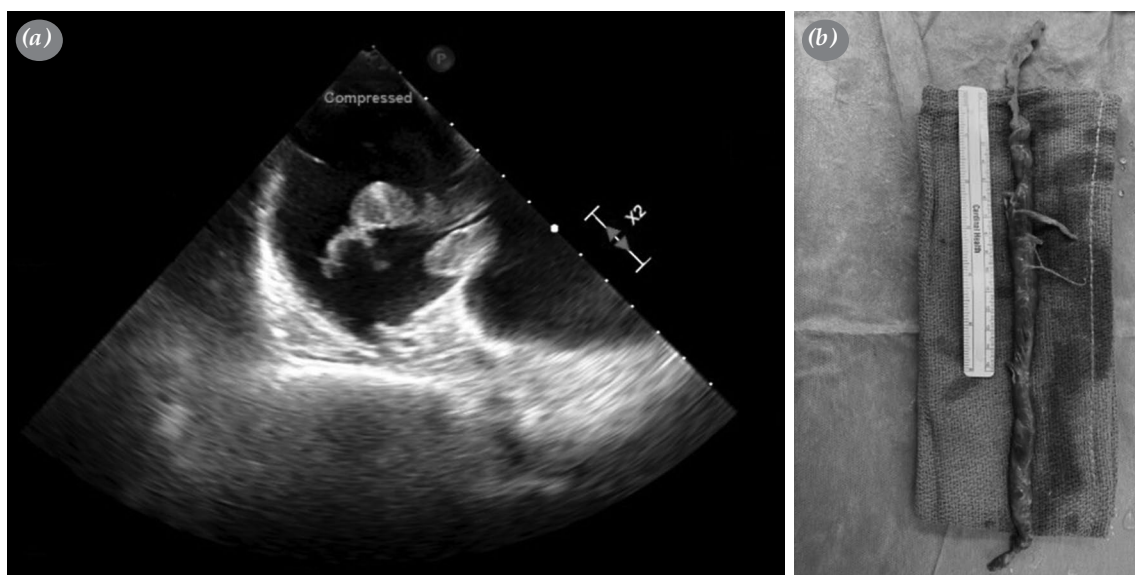
A previously healthy 71-year-old woman presented to the emergency department from an external center with symptoms of dyspnea on exertion. Thoracic computed tomography pulmonary angiogram (CTPA) revealed bilateral PE with right-sided intracardiac thrombus and evidence of RV strain. Concomitant CT brain was negative for acute intracranial process. Transesophageal echocardiogram (TEE) confirmed a well-organized, large mobile thrombus in the RA with prolapse into the RV during systole, suggestive of subacute thrombus for more than one week. There was moderate tricuspid regurgitation (TR) and a moderately dilated RV with mild RV dysfunction. Bilateral lower extremity venous Doppler was significant for extensive occlusive thrombus extending from the left external iliac vein to the left tibioperoneal trunk. Electrocardiogram showed no abnormality. Therapeutic anticoagulation with intravenous unfractionated heparin was initiated. Due to cor pulmonale and atrial clot-in-transit, thrombolytic therapy was deferred and the patient was emergently transferred to our facility for surgical versus mechanical thrombectomy of the clot in RA.

The patient arrived at our cardiothoracic intensive care unit (CTICU) with a heart rate of 102 bpm, a blood pressure of 115/75 mmHg, and a peripheral oxygen saturation of 99% on 3 L oxygen via nasal cannula. Bedside TEE demonstrated RV dysfunction

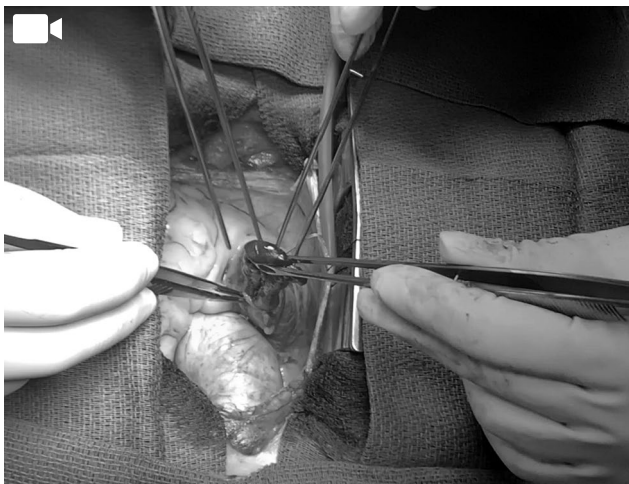
and the patient was urgently taken to the operating room.

The patient was placed under general anesthesia with endotracheal intubation. Catheter-based thrombectomy was first attempted using a modified AngioVac™ system. Following systemic heparinization, bilateral venous groin access was obtained and a venovenous bypass circuit was established using a 29-Fr cannula in the right femoral vein and a 16-Fr Fem-Flex® (Edwards, Irvine, CA, USA) cannula in the left femoral vein. The AngioVac™ catheter was introduced via the right groin sheath and advanced into the inferior vena cava (IVC) under TEE guidance. Multiple attempts were made to aspirate the clot without success.

Subsequently, the decision was made to attempt open thrombectomy via full sternotomy. The pericardium was opened and an atriotomy was made through a purse-string placed around the RA appendage. The atriotomy was entered using signet ring forceps (sponge forceps) under TEE guidance, and a 30-cm linear solid thrombus was retrieved (Video 1 and Figure 1). The atriotomy was closed with careful de-airing and intraoperative TEE confirmed the absence of residual clot. The chest was closed and the patient was extubated and transferred to the CTICU in stable condition without inotrope or vasopressor requirements. The patient remained hemodynamically stable throughout the procedure without the use of CPB or blood products.



**Figure 1.** 30-cm right atrial thrombus. (a) Thrombus on intraoperative transesophageal echocardiography showing prolapsing across the tricuspid valve. (b) *Ex-vivo* thrombectomy specimen.



**Video 1.** Extraction of right atrial thrombus via atriotomy in the right atrial appendage.

The postoperative course was significant for RV dysfunction with hemodynamic instability requiring inotropic support and inhaled nitric oxide, as well as atrial fibrillation with a rapid ventricular response, treated with amiodarone. Echocardiogram obtained on postoperative Day 2 revealed stable RV dysfunction with severely increased RV cavity size and moderate TR. The left ventricular ejection fraction was measured as 65% with a flattened septum in systole/diastole, consistent with RV volume overload. In addition, a non-contrast thoracic CT revealed an evolving pulmonary infarct in the left upper lobe. On postoperative Day 7, the patient underwent left lower extremity venous mechanical thrombectomy with IVC filter placement by interventional radiology, following which therapeutic anticoagulation was discontinued. The remainder of the hospitalization was uneventful and the patient has discharged on postoperative Day 12 in stable condition.

## DISCUSSION

Management of RHT in the setting of PE is currently debated as multiple pooled analyses have failed to demonstrate superior efficacy with thrombolytic therapy versus mechanical/surgical thrombectomy.<sup>[4]</sup> Appropriate treatment selection requires careful consideration of patient factors to weigh the risks of hemorrhagic stroke and bleeding with thrombolysis against stroke, cardiopulmonary failure, and recurrent thrombus associated with open thrombectomy. However, the morbidity associated with open surgery may be further reduced if CPB can be avoided. Off-pump RA thrombectomy has previously

been described in the context of renal cell carcinoma resection with tumor thrombi extending into the IVC/RA.<sup>[5]</sup> One technique by Schneider et al.<sup>[6]</sup> involves the insertion of a finger through an atriotomy (via median sternotomy) to manually displace the thrombus apex into the subdiaphragmatic IVC, facilitating *en bloc* removal with the renal tumor through an abdominal incision.<sup>[6]</sup> Rather than direct removal through the atriotomy, this technique reduces the presumed risk of clot fragmentation causing PE.

In our case, clot characteristics on preoperative imaging as well as difficulty with suction embolectomy suggested a single, well-formed thrombus amenable to direct atrial extraction. Furthermore, the location of the embolus within the pulmonary vasculature precluded open pulmonary embolectomy. Therefore, we pursued isolated right-atrial embolectomy via median sternotomy without CPB, avoiding potential worsening of pre-existing RV dysfunction. Risks of this approach include large-volume blood loss, air embolus, clot fragmentation, and damage to surrounding structures with mechanical manipulation of an adherent clot. As such, we only recommend this simple approach for carefully selected cases of subacute, solid, mobile thrombi after catheter-based techniques have failed. In addition, CellSaver® (Medtronic Inc., Minneapolis, MN, USA) should be utilized to minimize blood loss, and CPB available if necessary.

In conclusion, off-pump right atrial thrombectomy may offer an effective alternative to thrombolytic therapy and percutaneous thrombectomy in select patients. Larger series are needed to confirm the safety of this approach, potentially with less invasive access through thoracotomy.

**Patient Consent for Publication:** A written informed consent was obtained from the patient.

**Data Sharing Statement:** The data that support the findings of this study are available from the corresponding author upon reasonable request.

**Author Contributions:** All authors contributed equally to the article.

**Conflict of Interest:** The authors declared no conflicts of interest with respect to the authorship and/or publication of this article.

**Funding:** The authors received no financial support for the research and/or authorship of this article.

## REFERENCES

1. Barrios D, Rosa-Salazar V, Morillo R, Nieto R, Fernández S, Zamorano JL, et al. Prognostic significance of right heart thrombi in patients with acute symptomatic

- pulmonary embolism: Systematic review and meta-analysis. *Chest* 2017;151:409-16. doi: 10.1016/j.chest.2016.09.038.
2. Koć M, Kostrubiec M, Elikowski W, Meneveau N, Lankeit M, Grifoni S, et al. Outcome of patients with right heart thrombi: The right heart thrombi European registry. *Eur Respir J* 2016;47:869-75. doi: 10.1183/13993003.00819-2015.
  3. Rivera-Lebron B, McDaniel M, Ahrar K, Alrifai A, Dudzinski DM, Fanola C, et al. Diagnosis, treatment and follow up of acute pulmonary embolism: Consensus practice from the PERT consortium. *Clin Appl Thromb Hemost* 2019;25:1076029619853037. doi: 10.1177/1076029619853037.
  4. Burgos LM, Costabel JP, Galizia Brito V, Sigal A, Maymo D, Iribarren A, et al. Floating right heart thrombi: A pooled analysis of cases reported over the past 10years. *Am J Emerg Med* 2018;36:911-5. doi: 10.1016/j.ajem.2017.10.045.
  5. Shchukin DV, Lesovoy VN, Khareba GG, Harahaty AI, Maltsev AV, Polyakov MM, et al. Removal of the tumor thrombus from the right atrium without extracorporeal circulation: Emphasis on the displacement of the tumor apex. *Adv Urol* 2020;2020:6063018. doi: 10.1155/2020/6063018.
  6. Schneider M, Hadaschik B, Hallscheidt P, Jakobi H, Fritz M, Motsch J, et al. Manual repositioning of intra-atrial kidney cancer tumor thrombus: A technique reducing the need for cardiopulmonary bypass. *Urology* 201381:909-14. doi: 10.1016/j.urology.2012.10.064.