

# Carotid artery cut-down technique for ductus arteriosus stenting

## Duktus arteriyozus stentleme için karotis arter cut-down tekniği

Serdar Basgoze<sup>1</sup>, Ender Odemis<sup>2</sup>, Akif Onalan<sup>1</sup>, Bahar Temur<sup>1</sup>, Selim Aydın<sup>1</sup>,  
Fusun Guzelmeric<sup>4</sup>, Ayhan Cevik<sup>3</sup>, Ersin Ereğ<sup>1</sup>

*Institution where the research was done:*

Acibadem Mehmet Ali Aydınlar University Atakent Hospital, İstanbul, Türkiye

*Author Affiliations:*

<sup>1</sup>Department of Pediatric Cardiovascular Surgery, Acibadem Mehmet Ali Aydınlar University Atakent Hospital, İstanbul, Türkiye

<sup>2</sup>Department of Pediatric Cardiology, Koç University Faculty of Medicine, İstanbul, Türkiye

<sup>3</sup>Department of Cardiovascular Surgery, Acibadem Mehmet Ali Aydınlar University Atakent Hospital, İstanbul, Türkiye

<sup>4</sup>Department of Anesthesiology and Reanimation, Acibadem Mehmet Ali Aydınlar University Atakent Hospital, İstanbul, Türkiye

<sup>5</sup>Department of Pediatric Cardiology, Acibadem Mehmet Ali Aydınlar University Atakent Hospital, İstanbul, Türkiye

### ABSTRACT

**Background:** This study aims to evaluate early and mid-term outcomes of ductal stenting via carotid artery surgical cut-down technique in neonates.

**Methods:** Between January 2015 and January 2022, a total of 17 neonates (12 males, 5 females; median age: 14 days, range, 5 to 34 days) who underwent carotid artery surgical cut-down technique for ductal stenting were retrospectively analyzed. Diagnoses of the patients, demographics, procedural success/failure, access-related complications, and neuroimaging findings were recorded.

**Results:** The primary indication for ductal stenting was pulmonary atresia in all patients. All patients who underwent carotid cut-down had vertical anatomy, with or without tortuous ductal anatomy, and they were not suitable for the femoral approach. The median body weight was 3 (range, 2 to 3.4) kg. Fifteen of the 17 interventions (88.2%) were successful. Two patients whose stenting failed underwent a systemic-to-pulmonary shunt operation. The early in-hospital mortality rate was 17.6% (n=3). No neurological or access-related complications were observed in any of the patients.

**Conclusion:** Stenting the ductus arteriosus with challenging anatomy is feasible and safe with carotid artery cut-down, particularly in small neonates. Based on our study findings, this technique may offer an effective and less invasive alternative to the systemic-to-pulmonary shunt operation.

**Keywords:** Common carotid artery, congenital heart disease, patent ductus arteriosus, pulmonary atresia.

### ÖZ

**Amaç:** Bu çalışmada, yenidoğanlarda karotis arter cerrahi cut-down tekniği ile duktal stentlemenin erken ve orta dönem sonuçları değerlendirildi.

**Çalışma planı:** Ocak 2015 ve Ocak 2022 tarihleri arasında duktal stentleme için karotis arter cerrahi cut-down tekniği uygulanan toplam 17 yenidoğan (12 erkek, 5 kız; medyan yaş: 14 gün, dağılım, 5-34 gün) retrospektif olarak incelendi. Hastaların tanıları, demografik özellikleri, işlem başarısı/başarısızlığı, girişime bağlı komplikasyonlar ve nörogörüntüleme bulguları kaydedildi.

**Bulgular:** Tüm hastalarda duktal stentlemenin birincil endikasyonu pulmoner atrezi idi. Karotis cut-down uygulanan hastaların tümü, tortüöz duktal anatomi olsun veya olmasın vertikal anatomiye sahip olup, femoral yaklaşım için uygun değillerdi. Medyan vücut ağırlığı 3 (dağılım, 2-3.4) kg idi. On yedi girişimin 15'i (%88.2) başarılı oldu. Stentlemenin başarısız olduğu iki hastaya sistemik-pulmoner şant ameliyatı uygulandı. Erken hastane mortalite oranı %17.6 (n=3) idi. Hastaların hiçbirinde nörolojik veya girişime bağlı bir komplikasyon gözlenmedi.

**Sonuç:** Zorlayıcı anatomiye sahip duktus arteriyozusun stentlenmesi, özellikle küçük yenidoğanlarda karotis cut-down ile uygulanabilir ve güvenlidir. Çalışma sonuçlarımıza göre, bu teknik sistemik-pulmoner şant ameliyatına etkili ve daha az invaziv bir alternatif sunabilir.

**Anahtar sözcükler:** Ana karotis arter, doğumsal kalp hastalığı, patent duktus arteriyozus, pulmoner atrezi.

**Corresponding author:** Serdar Basgoze.

E-mail: basgozeserdar@gmail.com

Doi: 10.5606/tgkdc.dergisi.2023.24598

**Received:** January 03, 2023

**Accepted:** May 03, 2023

**Published online:** July 27, 2023

**Cite this article as:** Basgoze S, Odemis E, Onalan A, Temur B, Aydın S, Guzelmeric F, et al. Carotid artery cut-down technique for ductus arteriosus stenting. Turk Gogus Kalp Dama 2023;31(3):317-324. doi: 10.5606/tgkdc.dergisi.2023.24598.

©2023 All right reserved by the Turkish Society of Cardiovascular Surgery.



This is an open access article under the terms of the Creative Commons Attribution-NonCommercial License, which permits use, distribution and reproduction in any medium, provided the original work is properly cited and is not used for commercial purposes (<http://creativecommons.org/licenses/by-nc/4.0/>).

Ductal stenting, which was first described in 1991 by Coe and Olley<sup>[1]</sup> in an animal study and was first published in 1992 by Gibbs et al.<sup>[2]</sup> in a clinical study, has offered a good alternative to systemic-to-pulmonary artery shunts (SPSs) in neonates with pulmonary atresia. Currently, ductal stenting is the first treatment of choice for initial palliation in many centers.<sup>[3-5]</sup> Femoral access is the standard approach for ductal stenting. Yet, it may be challenging in some cases, particularly those with vertical and tortuous ductal anatomy.

Access to the vertical ductus and advancement of the stent via the retrograde route may be difficult due to the acute angle of the ductus originating from the aortic arch. Longer procedure time and smaller vessel diameter due to the low body weight also increase the risk of vascular complications. In such patients, the only alternative to the SPS operation may be to use an alternative access for ductal stenting, such as the axillary or carotid artery, which provides a more direct route. Therefore, the popularity of alternative routes has been increasing.<sup>[6-11]</sup> However, there is no consensus on the preferred route (axillary or carotid) or access technique (percutaneous or surgical cut-down). Some authors prefer the percutaneous technique, which requires some compression to be applied after removing the catheter to control bleeding. The risk of cerebral or arm ischemia is the drawback of this approach due to the high risk of thrombosis, hematoma, or pseudoaneurysm formation.<sup>[10-12]</sup> Our technique of choice is carotid artery cut-down. Carotid arteries are easy to manipulate even in neonates due to the larger diameter than the femoral artery. Moreover, access is quick and easy, with a small neck incision, given the superficial location. Then, repairing the vessel hole with a simple fine stitch after catheter removal, to avoid the risk of compression-related complications, is safe and feasible.

In the present study, we aimed to evaluate early and mid-term outcomes of ductal stenting via carotid artery cut-down technique.

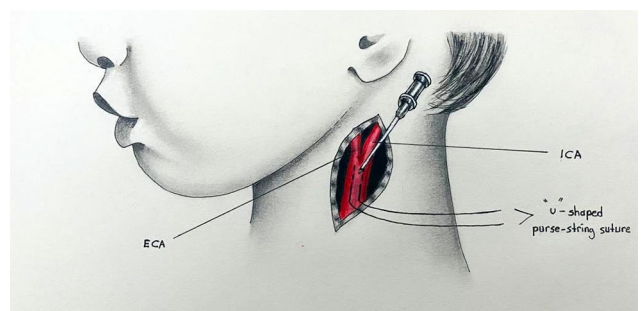
## PATIENTS AND METHODS

This single-center, retrospective study was conducted at Acibadem Mehmet Ali Aydınlar University Atakent Hospital, Department of Pediatric Cardiovascular Surgery between January 2015 and January 2022. Medical records of patients who underwent ductal stenting were recorded. A total of 119 neonates underwent ductal stenting for ductus-dependent pulmonary circulation. Of them, 17 (14.2%) (12 males, 5 females; median age: 14 days,

range, 5 to 34 days) who underwent carotid artery surgical cut-down technique for ductal stenting were included. Indications for the carotid approach were challenging ductal anatomy, comprising a vertical ductus position and/or tortuous anatomy, and potential failure to secure access via the femoral approach. If the ductus had more than one tortuosity, we directly decided to use the carotid approach. Alternatively, we normally attempted to engage the stent-to-ductus by taking the femoral approach (venous or arterial); in case of an unsuccessful attempt with this method, we, then, turned to the carotid approach. Diagnoses of the patients, demographics, procedural success/failure, access-related complications, and neuroimaging findings were recorded.

## Procedure

To provide a better placement of a ductal stent, prostaglandin E1 infusion was stopped 24 h before catheter intervention with close clinical follow-up. However, in patients who did not tolerate discontinuation of prostaglandin E1, prostaglandin E1 infusion was resumed, until the wire traversed into the ductus. All procedures were performed under general anesthesia and orotracheal intubation. Procedures were carried out with full cardiac monitorization. Preoperative transthoracic echocardiography (TTE) was used to determine the ductal anatomy and select which carotid artery would be used. Patients received intravenous 100 U/kg of heparin immediately before sheath placement, and we kept the activated clotting time (ACT) over 200 sec. The side arm of the sheath was connected to a transducer with saline with 1 U heparin per mL. The carotid artery was prepared with a small oblique neck incision. The needle puncture side in the anterior wall of the common carotid artery was secured with a “U” stitch with a 7-0 prolene suture. Carotid artery cannulation was performed



**Figure 1.** The schematic drawing shows a “U”-shaped suture placement just the width of the Seldinger needle. This surgical-assisted vascular access is called the semi-Seldinger technique.

ECA: External carotid artery; ICA: Internal carotid artery.

**Table 1. Diagnoses of patients**

	n	%
Pulmonary atresia/heterotaxy	5	29.4
Pulmonary atresia/VSD	5	29.4
Pulmonary atresia/tricuspid atresia	3	17.6
Pulmonary atresia/IVS	2	11.8
Pulmonary atresia/DORV	2	11.8

VSD: Ventricular septal defect; IVS: Intact ventricular septum; DORV: Double-outlet right ventricle.

using the semi-Seldinger technique with the 4F sheath in all cases (Figure 1). After completing the procedure, the purse suture was tied to close the puncture site. Vascular clamping was not used in any part of the procedure, including sheath withdrawal and primary repair. Cefazolin prophylaxis was received for 24 h.

The ductus was screened with the left lateral view and right or left anterior oblique angle. All ductus arteriosus (DA) had a vertical and/or tortuous morphology, and we measured the ductal length after the wire traversing to gain a more accurate measurement. All patient's DA narrowest part at the pulmonary side was smaller than 3 mm. Therefore, we selected a stent larger than 3 mm and decided on the size according to the children's body weight. In patients weighing less than 3 kg, we decided on a 3.5-mm-diameter stent; in patients weighing 3 to 4 kg, we chose a 4-mm-diameter stent. The stent length was

extended 1 to 2 mm more than the ductal length. All patients received a 5 mg/kg dose of acetylsalicylic acid starting 4 h from successful stenting, and heparin infusion was stopped 24 h after the procedure.

The patients were followed in the pediatric cardiac intensive care unit (ICU). Stent patency and cardiac evaluation were carried out by clinical examination, oxygen saturation (SpO<sub>2</sub>) level, chest X-ray, and echocardiography immediately after the procedure, on the first day after the procedure, before discharge and, if re-evaluation was needed. Seven days after discharge, all patients were scheduled for re-examination with a chest X-ray and echocardiography. All patients were followed monthly after the first control, until reintervention or surgery. The need for reintervention or surgery was determined based on the patient's growth, SpO<sub>2</sub> level, and cardiac pathology. Cardiac catheterization or computed tomography (CT) scan was used for screening before surgery. Early mortality was defined as death before discharge or death within one month from surgery.

## RESULTS

Diagnoses of the patients are shown in Table 1. All 17 neonate patients had vertical and/or tortuous ductal anatomy, which was challenging to access with the femoral approach. Four patients were under 2.5 kg, and three were between 2.5 and 3 kg. The median body weight was 3 (range, 2 to 3.4) kg. Ductal stenting via carotid cut-down was performed

**Table 2. Demographic and clinical characteristics of patients**

Variables	n	%	Median	Range
Number of patients	17			
Number of interventions	17			
Sex				
Female	5	29.4		
Weight (kg)			3	2-3.4
Age at intervention (days)			14	5-34
Vertical DA	17	100		
Successful intervention	15	82.3		
CNS complication	0	0		
Vascular and wound complications	0	0		
ICU stay (days)			2	1-31
Hospital stay (days)			6	1-33
Hospital mortality	3	17.6		
Follow-up time (months)			47.5	1-84

DA: Ductus arteriosus; CNS: Central nervous system; ICU: Intensive care unit.

in three patients following an unsuccessful femoral attempt. Two patients underwent ductal stenting via carotid cut-down due to ductal stent narrowing after initial stenting (on Day 20 and at one month). Two patients underwent the procedure for the left DA after successful right DA stenting. Finally, 15 of the 17

interventions (88.2%) were successful. The median length of ICU stay was 2 (range, 1 to 31) days, and the median length of hospital stay was 6 (range, 1 to 33) days.

Stent migration occurred in one patient and unsuccessful stent deployment in another. Both patients

**Table 3. Details of the interventions and outcomes**

No.	Age at first intervention (days)	Weight (kg)	Diagnosis	Stenting-related complication	Reintervention/ time interval	Last procedure	Hospital mortality	Late mortality
1	14	2.7	RAI-CAVSD-PA	-	-	Ductal stenting	Yes	-
2	6	3	VSD-PA	Stent migration to pulmonary artery	SPS surgery/day of catheterization	Rastelli	-	-
3	5	3	RAI-CAVSD-PA-VA discordance	-	SPS surgery/3.5 months	SPS surgery	-	Yes
4	10	3	RAI-CAVSD-PA	-	-	Ductal stenting	-	Yes
5	34	2.7	VSD-PA	-	-	Glenn shunt	-	-
6	7	3.4	IVS-PA	-	SPS surgery/2 months	Fontan completion	-	-
7	20	3	VSD-PA	-	-	Rastelli + PAP	-	-
8	27	3	TA-PA	-	-	Fontan completion	-	-
9	8	3	TA-PA	Pulmonary overflow	PDA ligation + SPS surgery/2 days	PDA ligation + SPS surgery	Yes	-
10	15	2.6	VSD-PA	-	-	Rastelli	-	-
11	9	2.4	VSD-PA	-	mBT shunt/9 months	Rastelli	-	-
12	14	3	IVS-PA	Stent narrowing on the pulmonary side	SPS surgery/2 days	SPS surgery	-	Yes
13	29	2.4	RAI-CAVSD-PA-VA discordance	-	-	Ductal stenting	-	Yes
14	20	3	TA-PA	-	SPS surgery + PAP/5 months	SPS surgery + PAP	-	Yes
15	10	2	RAI-CAVSD-PA	Stenting failure	SPS surgery/day of catheterization	SPS surgery	Yes	-
16	22	3.2	DORV - PA	-	SPS surgery/2 weeks	Glenn shunt	-	-
17	12	2.5	TOF-type DORV	-	-	Unifocalization + RV-PA conduit replacement + conduit banding/5 months	-	-

RAI: Right atrial isomerism; CAVSD: Complete atrioventricular septal defect; PA: Pulmonary atresia; VA: Ventriculoarterial; SPS: Systemic-to-pulmonary shunt; IVS: Intact ventricular septum; VSD: Ventricular septal defect; TA: Tricuspid atresia; PDA: Patent ductus arteriosus; PAP: Pulmonary artery plasty; TOF: Tetralogy of Fallot; DORV: Double-outlet right ventricle; RV-PA: Right ventricle-to-pulmonary artery.

whose ductal stenting failed underwent SPS surgery, and one died during hospital stay (Table 2).

### Early mortality

Early mortality occurred in three patients (17.6%). One patient who was diagnosed with right atrial isomerism and pulmonary atresia died the day after SPS surgery due to unsuccessful ductal stenting. Another patient was diagnosed with right atrial isomerism and pulmonary atresia and underwent two successful ductal interventions. The first was performed via the femoral vein to the right DA, and the second was completed two days after initial stenting to the left DA via the carotid approach. This

patient died two months after the procedure due to septic complications. The remaining patient diagnosed with tricuspid atresia with pulmonary atresia had pulmonary overflow and died despite ductal closure and an SPS operation one week later. All other patients had an uneventful post-procedural recovery with early extubation, indicating that they had a shorter ICU and hospital stay.

### Follow-up

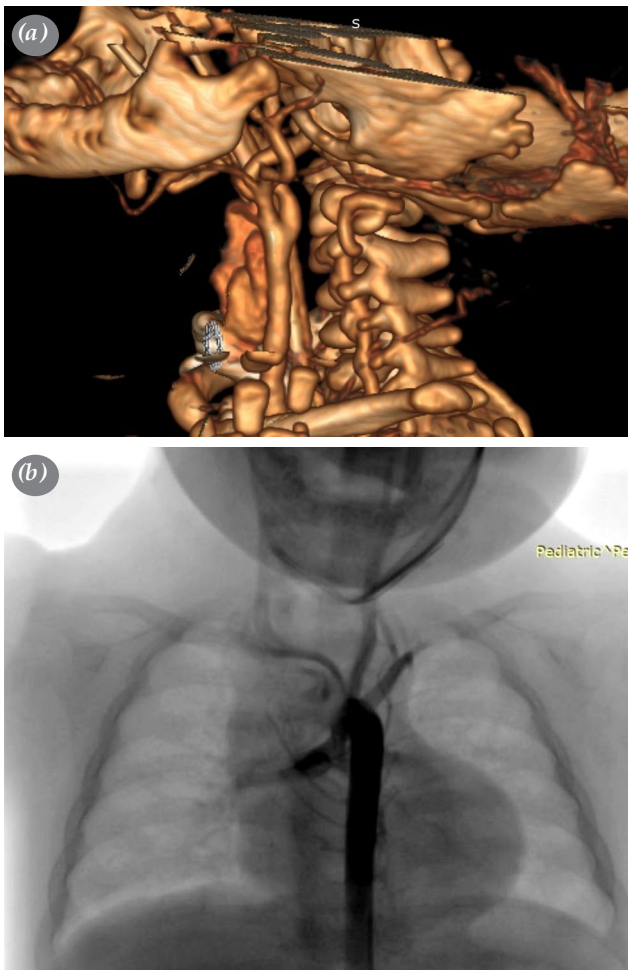
Five patients died during follow-up. Two of them who were diagnosed with right atrial isomerism and pulmonary atresia died at home after discharge (after one and 29 months). The patient who died 29 months after stenting was lost to follow-up; the date of death was found in the national death database. Other three patients died after second-stage surgery.

The Rastelli operation was successfully performed in four patients and the Glenn procedure in four patients. Of the latter two patients, both had successful Fontan completion after the Glenn procedure, and one underwent unifocalization and right ventricle-to-pulmonary artery conduit implantation.

No neurological complications were observed in any of the patients due to ductal stenting. Transfontanellar ultrasound (US) examinations were performed on a regular basis in all patients. Carotid Doppler US showed the patency of all carotid arteries. In five patients, the carotid arteries were screened with CT angiography, additional with pulmonary artery imaging, and all carotid arteries were normal. In seven patients, the carotid arteries were screened during preoperative invasive angiography before total correction and for a second- and/or third-stage procedure, and all patients had normal carotid arteries. Details of the interventions and outcomes are given in Table 3. Figure 2a illustrates a three-dimensional CT screening, and Figure 2b illustrates a conventional angiography screening before a second-stage operation.

### DISCUSSION

Ductal stenting has offered an alternative to surgery in suitable patients with ductal-dependent pulmonary circulation in recent years.<sup>[3-8]</sup> However, patients' low body weight and vertical or tortuous anatomy of the ductus present challenges while attempting ductal stenting via the femoral approach. Surgical carotid cut-down-assisted cardiac catheterization was first described as an alternative route by Azzolina *et al.*<sup>[13]</sup> in 1973. Since then, interventional cardiologists have gained experience in cardiac catheterization-based



**Figure 2.** (a) A three-dimensional neck computed tomography image showing no stenosis in the left common carotid artery, which was performed during pulmonary artery screening in a patient before Glenn shunt surgery. (b) A conventional angiography image showing the patent left common carotid artery which was performed during a pulmonary angiogram in a patient before total correction surgery.

interventions and become familiar with using US guidance. Percutaneous access to the carotid and the axillary artery has become widespread in the United States and European countries with an acceptable success rate.<sup>[6-11,14]</sup> However, decannulation of the sheath and bleeding control remain common problems resulting in hematoma, thrombosis, and pseudoaneurysm.<sup>[8,10-12]</sup> These complications may be seen less while using the carotid approach than the femoral approach, but still, complications such as thrombus and pseudoaneurysm can lead to severe cerebral injury and even death. These complications may not be related to the success of the vessel access. The main reason for these morbidities is the management of sheath removal and the long duration of the procedure, which is a result of challenging ductal anatomy. In this study, we retrospectively analyzed the outcomes of 17 ductal stenting procedures via the surgical cut-down-assisted carotid approach. There was no bleeding, hematoma, pseudoaneurysm, cerebral events, or access-related reintervention. All carotid arteries were screened with both carotid Doppler US and CT or conventional angiography, and there was no narrowing or thrombus formation. Considering that most patients have a single ventricle physiology, three in-hospital mortalities (n=2 heterotaxy syndrome and n=1 tricuspid and pulmonary atresia) may be reasonable.

In the present study, we primarily investigated access-related complications and the feasibility and safety of ductal stenting via carotid artery cut-down for neonates. Currently, the percutaneous approach has become widespread to reduce surgeon dependency and vascular injury.<sup>[9]</sup> Yet, the carotid approach offers advantages as an alternative to SPS surgery or in case of an unsuccessful attempt, particularly in small neonates and patients with challenging ductal anatomy such as vertical and tortuous DA. In contrast to recent studies of the percutaneous approach, in our literature review of the percutaneous approach,<sup>[15-17]</sup> we found no vascular access-related complications such as hematoma, surgical re-exploration, or pseudoaneurysm. The authors usually reported mild or no stenosis in a small proportion of their patients. Similar to these reports, we observed no such complications. However, Breatnach et al.<sup>[8]</sup> reported access-related complications in three of 20 (15%) (n=2 partial dissections and n=1 pseudoaneurysm) using the percutaneous axillary artery approach. Choudhry et al.<sup>[12]</sup> reported pseudoaneurysms in 2 of 18 (11.1%) patients using the percutaneous carotid approach. Furthermore, Polat<sup>[9]</sup> reported complications in seven of 30 patients who underwent cardiac catheterization via

the percutaneous carotid approach. Five complications (n=2 non-occlusive thrombi, n=1 mild luminal carotid narrowing, and n=2 hematomas) did not require surgical intervention, but two (n=1 pseudoaneurysm and n=1 hematoma that jeopardized the upper airway tract) were treated surgically. Satisfactory results may be gained with an experienced surgical team back-up. We never clamped or snared the carotid arteries in ductal stenting. All procedures were performed using a 4-Fr sheath, and “U”-shaped purse-string sutures were placed just a needle width apart. This is the so-called semi-Seldinger technique, which has been used particularly in extracorporeal membrane oxygenation (ECMO) applications and peripheral cannulation requiring cardiac surgery for many years.<sup>[18,19]</sup> The main idea of this technique is to use the Seldinger method after surgical exploration of the vessel. The decision on whether to use classic “U”-shaped sutures or double-pledged horizontal “U” sutures<sup>[19]</sup> is at the surgeon's discretion based on their experience.

Controversy surrounds the percutaneous approach in adult cardiovascular diseases. For many years, surgical femoral exposure has been used to access the femoral artery in the non-surgical treatment of aortic aneurysms and transaortic valve implantation. Currently, adult cardiac teams mostly use Perclose ProGlide™ and ProStar™ XL (Abbott Vascular, CA, USA) to reduce percutaneous access-related complications. Still, many articles report the superiority of surgical exposure.<sup>[20,21]</sup> Furthermore, some authors have proposed that surgical femoral exposure is cost-effective and safer than percutaneous access with closure devices.<sup>[20]</sup> In this regard, ductal stenting may be more hazardous than adult percutaneous procedures, since vascular-related complications are more difficult to handle in neonates and infants than in adults. In addition, the market does not provide suitable-sized closure devices for pediatrics. Despite all of this, manual compression after sheath decannulation in percutaneous carotid procedures does not seem to be safe. While inadequate compression may lead to bleeding, hematoma, and pseudoaneurysm, too much compression of the carotid artery may lead to carotid artery thrombosis and reduced cerebral flow. Our carotid artery approach with minimal surgical exploration and no vessel clamping, similar to that of Cakici et al.,<sup>[22]</sup> seems to be safer than percutaneous intervention.

The other alternative approach, instead of using the femoral artery for cardiac intervention, is to use the axillary artery. The main reason to prefer

the axillary over the carotid approach is to avoid cerebral injury. Meanwhile, studies have reported that carotid artery access does not reduce cerebral perfusion significantly. Lahiri *et al.*<sup>[23]</sup> reported that cerebral perfusion does not change significantly during cardiac catheterization via the carotid artery or after sheath removal. Additionally, they reported that no patient had a documented neurologic deficit following the procedure. Buesing *et al.*<sup>[24]</sup> examined that carotid artery ligation did not increase cerebral injury or neurodevelopmental impairment in ECMO survival patients who underwent the procedure via a carotid artery. Since neonates and infants have excellent collateralization, performing procedures via a carotid artery, even in larger ECMO cannula and carotid artery ligation, does not alter the neurological outcomes significantly. Similar to these reports, cerebral injury has not been documented for any of our participants in roughly four years of follow-up. Also, the axillary artery approach with blind arterial access may cause vascular complications such as hematoma, pseudoaneurysm, and dissection.<sup>[24]</sup>

The main limitation to this study is its single-center, retrospective design. Although this study has a large patient group, further multi-center, large-scale, prospective studies are needed to draw more reliable conclusions on this subject.

In conclusion, in small neonates with challenging ductal anatomy, ductal stenting with carotid access should be kept in mind. Surgical-assisted carotid artery approach may offer a safe and feasible alternative to percutaneous approaches. The risks of access-related complications are low. Further comparative studies are needed to decide the most optimal approach for these challenging patients.

**Acknowledgments:** Special thanks to cardiovascular intensive care nurse Ebru Arlı for the drawing.

**Ethics Committee Approval:** The study protocol was approved by the Acibadem University Ethics Committee (date: 25.02.2022, no: 2022-04/11). The study was conducted in accordance with the principles of the Declaration of Helsinki.

**Patient Consent for Publication:** A written informed consent was obtained from the parents and/or legal guardians of the patients.

**Data Sharing Statement:** The data that support the findings of this study are available from the corresponding author upon reasonable request.

**Author Contributions:** Idea/concept, design: S.B., S.A., E.E.; Control/supervision: E.O., E.E.; Data collection and/or processing: S.B., A.O., B.T.; Analysis and/or interpretation: S.B., F.G.; Literature review: S.B., B.T., A.C.; Writing the article: S.B., E.O., E.E.; Critical review: E.O., E.E.; References and fundings: A.O., B.T.; Materials: S.B., E.E.

**Conflict of Interest:** The authors declared no conflicts of interest with respect to the authorship and/or publication of this article.

**Funding:** The authors received no financial support for the research and/or authorship of this article.

## REFERENCES

1. Coe JY, Olley PM. A novel method to maintain ductus arteriosus patency. *J Am Coll Cardiol* 1991;18:837-41. doi: 10.1016/0735-1097(91)90810-v.
2. Gibbs JL, Rothman MT, Rees MR, Parsons JM, Blackburn ME, Ruiz CE. Stenting of the arterial duct: A new approach to palliation for pulmonary atresia. *Br Heart J* 1992;67:240-5. doi: 10.1136/hrt.67.3.240.
3. Onalan MA, Odemis E, Saygi M, Temur B, Aydin S, Demir IH, *et al.* Early and midterm results of ductal stent implantation in neonates with ductal-dependent pulmonary circulation: A single-centre experience. *Cardiol Young* 2020;30:1772-82. doi: 10.1017/S104795112000267X.
4. Ratnayaka K, Nageotte SJ, Moore JW, Guyon PW, Bhandari K, Weber RL, *et al.* Patent ductus arteriosus stenting for all ductal-dependent cyanotic infants: Waning use of Blalock-Taussig shunts. *Circ Cardiovasc Interv* 2021;14:e009520. doi: 10.1161/CIRCINTERVENTIONS.120.009520.
5. Glatz AC, Petit CJ, Goldstein BH, Kelleman MS, McCracken CE, McDonnell A, *et al.* Comparison between patent ductus arteriosus stent and modified Blalock-Taussig shunt as palliation for infants with ductal-dependent pulmonary blood flow: Insights from the congenital catheterization research collaborative. *Circulation* 2018;137:589-601. doi: 10.1161/CIRCULATIONAHA.117.029987.
6. Ligon RA, Kim DW, Vincent RN, Bauser-Heaton HD, Ooi YK, Petit CJ. Angiographic follow-up of infants and children undergoing percutaneous carotid artery interventions. *Catheter Cardiovasc Interv* 2018;91:1301-6. doi: 10.1002/ccd.27481.
7. Justino H, Petit CJ. Percutaneous common carotid artery access for pediatric interventional cardiac catheterization. *Circ Cardiovasc Interv* 2016;9:e003003. doi: 10.1161/CIRCINTERVENTIONS.115.003003.
8. Breatnach CR, Aggarwal V, Al-Alawi K, McMahon CJ, Franklin O, Prendiville T, *et al.* Percutaneous axillary artery approach for ductal stenting in critical right ventricular outflow tract lesions in the neonatal period. *Catheter Cardiovasc Interv* 2019;93:1329-35. doi: 10.1002/ccd.28302.
9. Polat TB. Stenting the vertical ductus arteriosus via axillary artery access using "wire-target" technique. *Congenit Heart Dis* 2017;12:800-7. doi: 10.1111/ehd.12512.
10. Bauser-Heaton H, Qureshi AM, Goldstein BH, Glatz AC, Nicholson GT, Meadows JJ, *et al.* Use of carotid and axillary artery approach for stenting the patent ductus arteriosus in infants with ductal-dependent pulmonary blood flow: A multicenter study from the congenital catheterization research collaborative. *Catheter Cardiovasc Interv* 2020;95:726-33. doi: 10.1002/ccd.28631.

11. Polat TB. Use of percutaneous carotid artery access for performing pediatric cardiac interventions: Single-center study. *Ann Pediatr Cardiol* 2020;13:16-24. doi: 10.4103/apc.APC\_26\_19.
12. Choudhry S, Balzer D, Murphy J, Nicolas R, Shahanavaz S. Percutaneous carotid artery access in infants <3 months of age. *Catheter Cardiovasc Interv* 2016;87:757-61. doi: 10.1002/ccd.26310.
13. Azzolina G, Eufrate SA, Allella A. New approach to catheterization of the heart in infants and children. *Br Heart J* 1973;35:643-6. doi: 10.1136/hrt.35.6.643.
14. Davenport JJ, Lam L, Whalen-Glass R, Nykanen DG, Burke RP, Hannan R, et al. The successful use of alternative routes of vascular access for performing pediatric interventional cardiac catheterization. *Catheter Cardiovasc Interv* 2008;72:392-8. doi: 10.1002/ccd.21621.
15. Weber HS, Mart CR, Kupferschmid J, Myers JL, Cyran SE. Transcarotid balloon valvuloplasty with continuous transesophageal echocardiographic guidance for neonatal critical aortic valve stenosis: An alternative to surgical palliation. *Pediatr Cardiol* 1998;19:212-7. doi: 10.1007/s002469900287.
16. Borghi A, Agnoletti G, Poggiani C. Surgical cutdown of the right carotid artery for aortic balloon valvuloplasty in infancy: Midterm follow-up. *Pediatr Cardiol* 2001;22:194-7. doi: 10.1007/s002460010202.
17. Robinson BV, Brzezinska-Rajszyz G, Weber HS, Ksiazek J, Fricker FJ, Fischer DR, et al. Balloon aortic valvotomy through a carotid cutdown in infants with severe aortic stenosis: Results of the multi-centric registry. *Cardiol Young* 2000;10:225-32. doi: 10.1017/s104795110000915x.
18. Peek GJ, Firmin RK, Moore HM, Sosnowski AW. Cannulation of neonates for venovenous extracorporeal life support. *Ann Thorac Surg* 1996;61:1851-2. doi: 10.1016/0003-4975(96)00173-7.
19. Sen O, Aydin U, Kadirogullari E, Bayram M, Karacalilar M, Kutluk E, et al. Mid-term results of peripheral cannulation after robotic cardiac surgery. *Braz J Cardiovasc Surg* 2018;33:443-7. doi: 10.21470/1678-9741-2018-0061.
20. Marone EM, Brioschi C, Pallini M, Marazzi G, Chierico S, Rinaldi LF. Mini-surgical access prevents local complications and reduces costs in endovascular aortic repair. *Ann Vasc Surg* 2022;86:111-6. doi: 10.1016/j.avsg.2022.05.014.
21. Nelson PR, Kracjer Z, Kansal N, Rao V, Bianchi C, Hashemi H, et al. A multicenter, randomized, controlled trial of totally percutaneous access versus open femoral exposure for endovascular aortic aneurysm repair (the PEVAR trial). *J Vasc Surg* 2014;59:1181-93. doi: 10.1016/j.jvs.2013.10.101.
22. Cakici M, Yazicioglu L, Baran C, Ozcinar E, Ozgur A, Soykan C, et al. A retrospective analysis of surgical femoral artery closure techniques: Conventional versus purse suture technique. *Ann Vasc Surg* 2017;44:103-12. doi: 10.1016/j.avsg.2017.04.032.
23. Lahiri S, Qureshi AM, Justino H, Mossad EB. Percutaneous common carotid artery access for cardiac interventions in infants does not acutely change cerebral perfusion. *Pediatr Cardiol* 2022;43:104-9. doi: 10.1007/s00246-021-02697-9.
24. Buesing KA, Kilian AK, Schaible T, Loff S, Sumargo S, Neff KW. Extracorporeal membrane oxygenation in infants with congenital diaphragmatic hernia: Follow-up MRI evaluating carotid artery reocclusion and neurologic outcome. *AJR Am J Roentgenol* 2007;188:1636-42. doi: 10.2214/AJR.06.1319.
25. Schranz D, Michel-Behnke I. Axillary artery access for cardiac interventions in newborns. *Ann Pediatr Cardiol* 2008;1:126-30. doi: 10.4103/0974-2069.43878.