

Physician Abstract » Aortic (Thoracic) Pathologies and Surgery/Endovascular Interventions**[MEP-12]****Rare and Catastrophic Complication After Bentall Operation: Right Coronary Artery Button Pseudoaneurysm Repaired with Modified Cabrol Technique**Nur Gizem Elipek, İlknur Günaydın, Seyhan Babaroğlu, Şeref Alp Küçükler, Ayşen Aksöyek*Department of Cardiovascular Surgery, Ankara Bilkent City Hospital, Ankara, Türkiye***Türk Gogus Kalp Dama** 2024;32(Suppl 2):MEP-12

Doi: 10.5606/tgkdc.dergisi.2024.mep-12

E-mail: gizelipek@gmail.com

Received: September 11, 2024 - Accepted: September 29, 2024

Coronary artery pseudoaneurysm is a rare but fatal complication that can be seen following the Bentall operation. Modified techniques have reduced these complications but they have not completely eliminated them. In this case report, we presented a 65-year-old female patient who underwent a Bentall procedure in 2012 and endovascular coil repair of a right coronary artery button pseudoaneurysm in 2016. Right femoral artery and vein cannulation was performed, and systemic cooling was started. Cardiopulmonary bypass was instituted, and the patient was cooled to 18°C. Deep hypothermic circulatory arrest was started, and re sternotomy was performed (deep hypothermic circulatory arrest duration was 7 min). The aneurysm sac was opened. Of the coronary buttons the left main coronary artery orifice was not suitable for direct reimplantation to the new ascending graft, reimplantation was performed with the modified Cabrol technique using an 8-mm Dacron graft. The right coronary artery orifice was primarily closed, and bypass was performed on the Cabrol graft with a saphenous vein graft. The patient was rewarmed and weaned off cardiopulmonary bypass without complication. Intraoperative control fiberoptic bronchoscopy and transesophageal echocardiography showed that the trachea and pulmonary artery compression were completely eliminated. The patient was extubated on time during the intensive care course and made an uneventful recovery. Coronary button pseudoaneurysm complication after modified Bentall surgery requires urgent surgical repair. The modified Cabrol technique can be a lifesaver in such complications and redo cases. Although there are authors who recommend interventional methods first in this complication, we believe that early surgical intervention is more appropriate as it will become more complicated over time.

Keywords: Bentall procedure, coronary artery pseudoaneurysm, coronary button pseudoaneurysm, modified Cabrol technique.

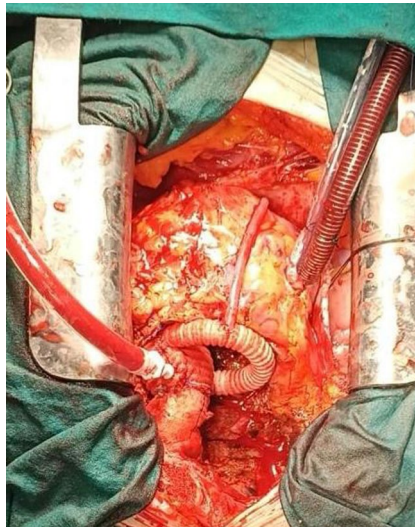


Figure 1. Intraoperative image of the modified Cabrol technique.

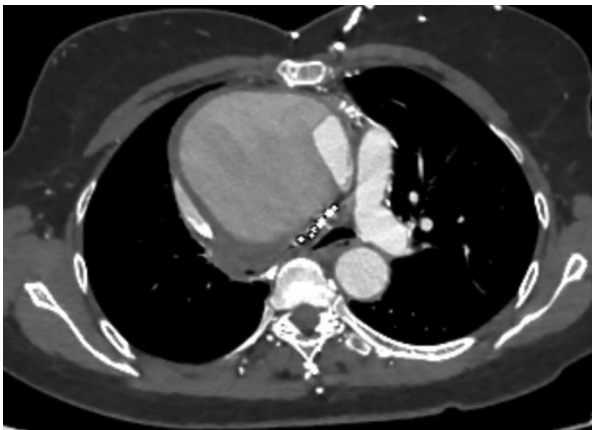

Figure 2. Pseudoaneurysm compressing the right pulmonary artery and trachea.

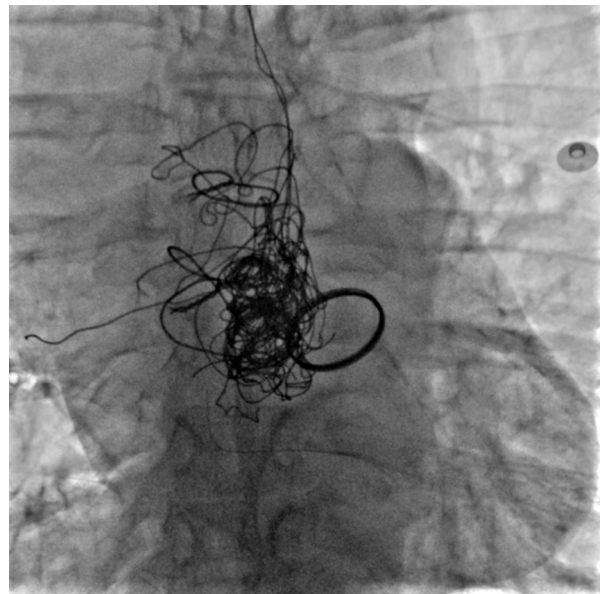


Figure 3. Endovascular coil seen on fluoroscopy.

References

1. Bentall H, De Bono A. A technique for complete replacement of the ascending aorta. *Thorax* 1968;23:338-9. doi: 10.1136/thx.23.4.338.
2. Varela Barca L, Calderón Romero P, Sánchez-Aquino R, Donado Miñambres A, Hernández-Estefanía R, Sanz Mayordomo P, et al. Coronary pseudoaneurysm after Bentall-Bono intervention: A novel treatment to a rare surgery complication. *J Cardiol Cases* 2022;26:157-60. doi: 10.1016/j.jccase.2022.04.005.
3. Kouchoykos NT, Marshall WG Jr, Wedige-Stecher TA. Eleven-year experience with composite graft replacement of the ascending aorta and aortic valve. *J Thorac Cardiovasc Surg* 1986;92:691-705.
4. Milano AD, Pratali S, Mecozzi G, Boraschi P, Braccini G, Magagnini E, et al. Fate of coronary ostial anastomoses after the modified Bentall procedure. *Ann Thorac Surg* 2003;75:1797-801. doi: 10.1016/s0003-4975(03)00015-8.
5. Celiento M, Ravenni G, Margaryan R, Ferrari G, Blasi S, Pratali S, et al. The modified Bentall procedure: A single-institution experience in 249 patients with a maximum follow up of 21.5 years. *J Heart Valve Dis* 2016;25:448-55.
6. Kourliouros A, Soni M, Rasoli S, Grapsa J, Nihoyannopoulos P, O'Regan D, et al. Evolution and current applications of the Cabrol procedure and its modifications. *Ann Thorac Surg* 2011;91:1636-41. doi: 10.1016/j.athoracsurg.2011.01.061.