

# Koroner Arter Cerrahisinde İnternal Torasik Arter Grefti Hazırlanması Sırasında Rastlanan Lenfoma Olgusu

## INCIDENTAL FINDING OF LYMPHOMA DURING INTERNAL THORACIC ARTERY HARVESTING FOR CORONARY ARTERY BYPASS SURGERY

Hakan Gerçekoğlu, Tufan Şener, Bige Aydın, İlknur Kıyıl

Dr Siyami Ersek Cardiovascular and Thoracic Surgery Center, Haydarpaşa, Istanbul, Turkey

### Özet

İnternal torasik arter (İTA) grefti koroner arter cerrahisinde iyi bilinen uzun dönem sonuçları sebebiyle sıkça kullanılan bir bypass konduitidir. İTA grefti genellikle venöz ve lenfatik damar yapıları ve yakın dokusuyla beraber hazırlanır. İTA grefti hazırlanması sırasında İTA komşuluğundaki lenfadenopatilerin incelenmesiyle ortaya çıkarılan bir lenfoma olgusu sunulmaktadır.. Lenfomalar immün sistemin malign tümörleridirler. Lenfoid doku hücrelerinin proliferasyonu ile karakterizedirler. Ayırıcı tanıda enfeksiyonlar ve özellikle metastatik tümörler düşünülmelidir. İTA greftleri lenfadenopatileri olsa bile İTA'nın vasküler yapısını ve akımını bozmuyorsa kullanılabilirler.

**Anahtar kelimeler:** koroner arter bypass cerrahisi, internal torasik arter, lenfadenopati, lenfoma

*Türk Göğüs Kalp Damar Cer Derg 2002;10:48-49*

### Summary

Internal thoracic artery (ITA) graft is used widely as a bypass conduit for its well known long term patency in coronary artery surgery. ITA is commonly harvested with its associated tissue, with the vena comitantes, lymphatic channels and lymph nodes. We present a case of lymphoma which came to medical attention by incidental finding of lymphadenopathies during internal thoracic artery harvesting. Lymphomas are malignant neoplasms of the immune system characterized by proliferation of lymphoid tissue cells which present mostly with persistent painless peripheral lymphadenopathy. Lymphadenopathies on internal thoracic artery pedicle deserve further examination. The differential diagnosis includes infections and other neoplasms especially metastatic tumors. We suggest that use of the ITA as a bypass graft is still possible in spite of lymphadenopathies on its pedicle unless these impair its vascular integrity and flow.

**Keywords:** coronary artery by-pass surgery, internal thoracic artery, lymphadenopathy, lymphoma

*Turkish J Thorac Cardiovasc Surg 2002;10:48-49*

### Introduction

Internal thoracic artery (ITA) graft is used widely as bypass conduit for its well known long term patency in coronary artery surgery. ITA is commonly harvested with its associated tissue, with the vena comitantes, lymphatic channels and lymph nodes. We present a case of lymphoma which came to medical attention by incidental finding of lymphadenopathies during internal thoracic artery harvesting.

### Case Report

A 59 year-old male who had chest pain typical for angina (NYHA Class IV) which was refractory to medical therapy for the last two months was admitted to our hospital. On coronary angiography, the left main coronary artery, the circumflex artery and the right coronary artery were found to be normal. The left coronary artery (LAD) was diffusely involved having

a 90% stenosis at the proximal portion and showing TIMI I distal flow. Left ventricular function was normal with an ejection fraction of 55 %.

Preoperative history provided no systemic complains other than angina pectoris. Physical examination was completely normal with no palpable lymph nodes. Preoperative blood count revealed  $9.300 \times 10^9 / \mu\text{L}$  leukocytes with a formula of 56.8% neutrophils, 32.8 % lymphocytes, 8.8 % monocytes, 1.4 % eosinophiles, and 0.2% basophiles. Erythrocyte sedimentation rate was 28 mm/hour. All other routine laboratory results were within normal range. The frontal and lateral chest films were normal with a normal heart size, shape and lung fields.

### Surgical Technique

An off-pump coronary artery bypass surgery was planned. Median sternotomy was performed. During left ITA harvesting, three masses loosely attached to the pedicle of the ITA were



**Figure 1.** Macroscopic appearance of the lymphadenopathy on the ITA pedicle.

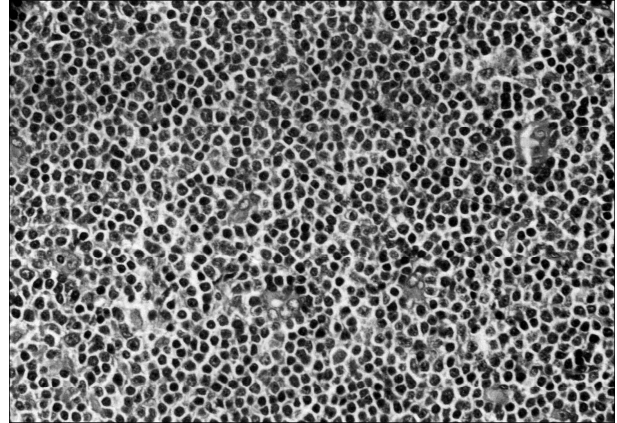
noted, which were almost round in shape, 20-25 mm in diameter and rubbery in consistency (Figure I). These masses were easily removed with sharp dissections and sent to the pathology laboratory. On macroscopic examination the vascular integrity was not impaired. Blood flow in the ITA was measured after dissection of the pedicle which was 144 ml/min while the cardiac index was 3.1 mL/min/m<sup>2</sup>. Using Octopus Tissue Stabilizer III (Medtronic, Inc., Minneapolis, MN) on beating heart the left ITA was anastomosed to the midportion of LAD. Finally, the operation was ended by standart closing of the chest. Following an uneventful recovery he was discharged from the hospital at the sixth postoperative day.

## Results

Microscopic findings of the masses revealed a low grade small cell malignant lymphoma with diffuse monomorphic tumor cell infiltration of the lymph nodes. Atypical lymphoid cells, appearing to be 1-1.5 times the normal size of mature lymphocytes were observed which showed fine chromatin pattern, a narrow cytoplasm and a round nucleus. (Figure II).

## Discussion

About 30 000 new cases of non-Hodgkin's lymphoma occur each year in the United States and this number appears to be rising (1). With the increasing incidence of aquired immunodeficiency syndrome, the number of cases of non-Hodgkin's lymphoma has begun to increase sharply (1). Approximately 20 percent of patients with non-Hodgkin's lymphoma have mediastinal lymphadenopathy (1). These patients most frequently present with persistent cough, chest discomfort, or without symptoms but having an abnormal chest x-ray. At the time of presentation, differential diagnosis includes infections caused by bacteria, viruses (e.g., infectious mononucleosis, cytomegalovirus and human immunodeficiency virus) and parasites (toxoplasmosis) (1). In younger patients, Hodgkin's lymphoma must be excluded (1). In older patients, other neoplasms and metastatic tumors must be considered (1).



**Figure 2.** Microscopic appearance of the pathologic specimen that was taken from the lmyphadenopathy on the ITA pedicle.

A review of the literature showed that the only case report of incidental finding of a malignancy during ITA harvesting was reported by Lin-Rui Guo and his colleagues (2).

Non invasive imaging of the ITA lymph nodes with computed tomography or lymphoscintigraphy or parasternal sonography is preferred to the surgical sampling of these lymph nodes. Especially ultrasonographic and doppler imaging of the ITA and the lymph nodes can provide valuable information about the pathological process affecting the mediastinum (3).

The aim of reporting this rare case is to emphasize that incidental finding of lymphadenopathies on ITA pedicle deserve further examination. We suggest that use of the ITA as a bypass graft is still possible in spite of lymphadenopathies on its pedicle unless these impair its flow and vascular integrity or interfere with the construction of an anastomosis.

## References

1. Lee MN. The Malignant Lymphomas. In: Wilson JD, Braunwald E, Isselbacher KJ, et al eds. Harrison's Principles of Internal Medicine, 12th edition. New York: McGraw-Hill, Inc., 1991:1599-612.
2. Guo LR, Myers ML and Kirk ME. Incidental malignancy in internal thoracic artery lymph nodes. *Ann Thorac Surg* 2001;72:625-7.
3. Scatarige JC, Hamper UM, Sheth S, Allen III HA. Parasternal sonography of the internal mammary vessels: Technique, normal anatomy, and lymphadenopathy. *Radiology* 1989;172:453-7.