

Çocuklarda Yabancı Cisim Aspirasyonu: 75 Olguluk Deneyimimiz

FOREIGN BODY ASPIRATIONS IN CHILDREN: A REVIEW OF OUR EXPERIENCE IN 75 CASES

Nehir Sucu, Barlas Aytacıođlu, Ali Özdülger, Ođuz Köksel, Ali Gül, Murat Dikmengil

Mersin Üniversitesi Tıp Fakültesi, Göğüs Kalp ve Damar Cerrahisi Ana Bilim Dalı, Mersin

Özet

Amaç: Çocuklarda yabancı cisim aspirasyonları genellikle akut solunum sıkıntısı ile görülürken bazen sessiz kalabilir. Başlangıçta sessiz kalan olgular daha sonra karınza dirençli akciğer enfeksiyonu, bronkiektazi veya akciğer absesi gibi bir klinik tabloyla çkabilir. Bu çalışmadaki amaçımız aspirasyon şüphesi uyandıran klinik tabloların tan ve tedavisinde ve kesin tanı almış hastaların tedavisinde bronkoskopinin önemini vurgulamaktır.

Materyal ve Metod: Yabancı cisim aspirasyon şüphesi ile yetmiş beş hasta kliniğimize kabul edilmiş ve bronkoskopi yapılmıştır.

Bulgular: Elli dört çocuk (%72) yabancı cisim aspirasyonu tanısı ile tedavi için bronkoskopiye alınırken, yirmi bir çocuk (%28) öncelikle tanı amaçlı bronkoskopiye alınmıştır. Üç çocukta (%4) ölümcül olmayan komplikasyon gelişmiştir.

Sonuç: Çocuklarda yabancı cisim aspirasyonu hayatı tehdit eden büyük bir problemdir. Yabancı cisim aspirasyonu şüphesi uyandıran klinik tablolarda tanı ve tedavide bronkoskopi kaçınılmazdır.

Anahtar kelimeler: Yabancı cisim aspirasyonu, hava yolu tıkanıklığı, bronkoskopi

Türk Göğüs Kalp Damar Cer Derg 2002;10:155-159

Summary

Background: Foreign body aspirations in children usually presents with acute respiratory distress but sometimes it may remain silent. Sometimes persistent lung infection, bronchiectasis or lung abscess may be the only presenting clinical picture. In this study we aimed to express the importance of some predictive clinical pictures arousing for aspirated suspicion of foreign bodies and the importance of bronchoscopy in the diagnosis and treatment of such clinical presentations and in identified foreign body aspirations.

Methods: Rigid bronchoscopy was performed in seventy-five patients with suspicion of foreign body aspiration who admitted to our clinic.

Results: Fifty-four children (72%) with the definitive diagnosis of aspirated foreign body underwent bronchoscopy for treatment and twenty-one children (28%) were taken to bronchoscopic examination for the establishment of diagnosis. Nonfatal complications occurred in 3 children (4%).

Conclusions: Foreign body aspiration is a major problem and is a threat for life in children. There may be some predictive clinical evidence in the presentation of the foreign body aspirations which should be suspected and bronchoscopy should not be abstained from for both diagnosis and treatment.

Keywords: Foreign body aspiration, airway obstruction, bronchoscopy

Turkish J Thorac Cardiovasc Surg 2002;10:155-159

Introduction

Foreign body aspiration is a life threatening and common medical emergency in childhood, with serious and potentially lethal consequences [1-5]. Although foreign body aspirations frequently present with acute respiratory symptoms the severity of the clinical picture may vary. It may also present with insidious and vague symptoms or may be introduced by a picture of persistent respiratory tract infection, bronchiectasis or lung abscess [2-5]. History, physical examination and

radiological findings are helpful to perform an early diagnosis. Despite all the developments in radiology, definite diagnosis can be made with bronchoscopy. The foreign body must be removed as soon as it is diagnosed. Bronchoscopy is the gold standard method in the treatment as it is in diagnosis. Parallel to the developments in anesthesia and bronchoscopy, bronchoscopic removal of foreign bodies are managed with low morbidity and mortality in experienced hands [1-6].

In this article we reviewed our series of 75 children in whom we suspected aspirated foreign bodies and we have evaluated

Table 1. Patient features.

Age	n	Male	Female	%
0-1	12	7	5	16
2-3	26	16	10	34.6
4-5	11	6	5	14.6
6-7	9	6	3	12
8-10	5	3	2	6.66
11-14	12	3	9	16
Total	75	41	34	100

Table 2. Time of admittance.

Admittance time (hours)	n	%
0-1	21	28
1-12	14	18.6
12-24	15	20
24-72	13	17.3
> 72	12	16

Table 3. Radiologic findings.

Radiographic Findings	n	%
Normal radiographic findings	11 (2)*	16.9
Pathologic radiographic findings		
Air trapping	21 (1)**	32.3
Unilateral paranchimal infiltration	14 (1)**	21.5
Radiopaque material	13	20
Atelectasis	4 (1)**	6.2
Mediastinal shift	2	3.1
Total	65	100

* No. of patients in whom foreign bodies were found.
** No of patients in whom foreign bodies were not found.

the predictive value of history, clinical signs, symptoms and radiology in the diagnosis of foreign bodies. We also put forward the advantages and pitfalls of bronchoscopy in diagnosis and treatment of foreign body aspirations.

Materials and Methods

From 1996 to 1999, 75 children admitted to our emergency service and outpatient ward with suspicion of foreign body aspiration. Fortyone patient (54.6%) were males and 34 were females (45.4%). Our patients were between 9 months and 14 years of age (Table 1). The median age for the males was 36 months and for the females it was 48 months. Children with sputum plug, blood clot and gastrointestinal contents in their tracheobronchial system were excluded from the study. Hospital admittance had occurred between 30 minutes and 6

Table 4. Foreign bodies removed from the patients.

Foreign Body	n	%
Food Materials		
Sunflower seed	16	25.3
Watermelon seed	7	11.1
Beans	3	4.7
Peanut	4	6.3
Hazel-nut	2	3.1
Corn	2	3.1
Peanut	1	1.5
Carrot peace	1	1.5
Orange seed	1	1.5
Apple peace	1	1.5
Bone particle	1	1.5
Plastic materials		
Unidentified plastic materials	5	7.9
Bead	6	9.5
Metal Materials		
Needle	4	6.3
Turban needle	9	14.2
Total	63	100

months after aspirations. Fifty children admitted at the first 24 hours, 13 of them between 24–72 hours and 12 children at 72 hours to 6 months period (Table 2). Fifty-four children (72%) were taken to bronchoscopy with the diagnosis and 21 children (28%) were intervened with clinical suspicion. The latter group represents children with persistent respiratory tract infections or poor radiological findings (Table 3).

In all cases bronchoscopy was performed under general anesthesia with controlled ventilation using a pediatric bronchoscope with distal light illumination (D78532 Karl-Storz). Especially in children who aspirated food particles optical forceps (Karl-Storz Optical Forceps GMB and Co, Tuttlingen, West Germany) was used routinely. In the beginning of every bronchoscopy larynx was explored routinely. First normal, then suspicious regions for aspirated foreign bodies were evaluated. Bronchoscopies were repeated whenever there had been any suspicion especially after the removal of any organic material in order to find out if residual pieces still existed in tracheobronchial tree, evaluate the intrabronchial changes and take cultures if necessary. The procedure was unsuccessful in three children. In two of these patients foreign bodies were removed in a second attempt but we had to take the remaining single child who had aspirated a pen cap to thoracotomy and bronchotomy. The children were observed in the hospital for the next 18 hours and were put on aerosol bronchodilator therapy, antibiotics and chest physiotherapy. Steroids were not used routinely.

Results

Foreign bodies were identified in 63 (84%) of all 75 children who were taken to bronchoscopic evaluation. While there was a history of foreign body aspiration in 54 patients (72%) who underwent bronchoscopy foreign bodies were found only in 51

(68%), but the history was positive only in 4 (5.3%) of the suspected 21 (28%) cases and aspirated foreign bodies in this group was found in 12 (57.1%) of them. Aspirated foreign bodies were found in 10 patients (13.3%) who were taken emergently to bronchoscopy with history and physical examination only. Thirtyeight (50.6%) of these 75 children were in 0-3 age group. In this age group suspicion of foreign body aspiration was more common in males (23 males / 15 females). Sudden onset of choking and irritant cough were the major symptoms in more than half of the children. Twelve children (16%) who presented with acute respiratory symptoms and in whom we suspected aspirated foreign bodies turned out to have chronic respiratory tract infection without any aspirated foreign bodies.

PA and lateral chest roentgenograms were taken in 65 children (except 10 who were taken to operation room as soon as they reached the hospital). Most common finding on chest roentgenograms was air trapping (Table 3). Roentgenograms were normal in 11 children. There were no foreign bodies in three children among 54 who had pathological roentgenograms. Foreign bodies were removed in 2 children among 11 with totally normal roentgenograms. Positive radiological findings were rare in children who admitted to hospital in 12 hours.

Foreign bodies removed by bronchoscope are given on Table 4. Food particles represent the main group of foreign body aspirations in 0-3 year age band. Plastic materials were common in 3-10 years and metallic materials in 10-14 years age band (Figure 1).

Right-sided and left-sided bronchial foreign body aspirations were recorded in 25 and 21 patients whereas tracheal foreign bodies were found in 17 children (Figure 2). The size of the foreign body and the time of admittance were the other factors influencing the degree of inflammation and secretions.

Non fatal complications occurred in 3 children (4%). These were reversible cardiac arrest (in 1 child), pneumothorax (in 1 child), and persistent bronchospasm (in 1 child). Cardiac arrest was recuscitated, pneumothorax was treated with closed drainage and the child who had persistent bronchospasm was taken to volume respirator and put on steroid therapy. All three children were discharged in one week's period.

Discussion

Figure 1. Foreign bodies according to age groups.

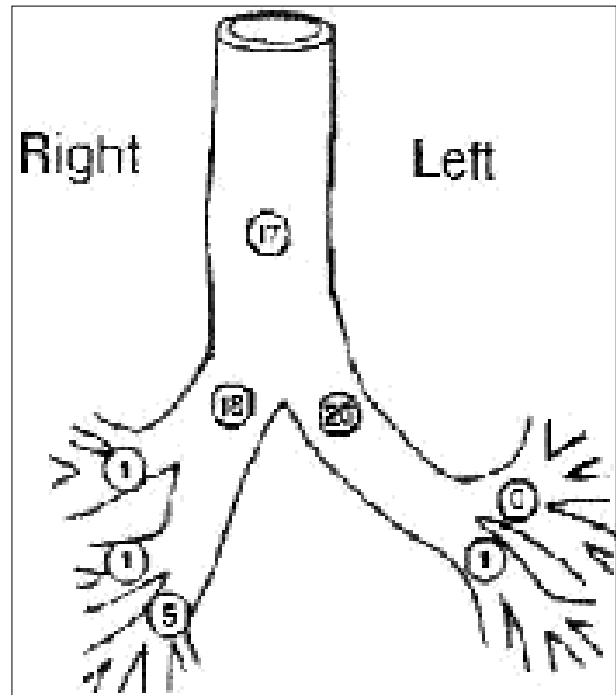
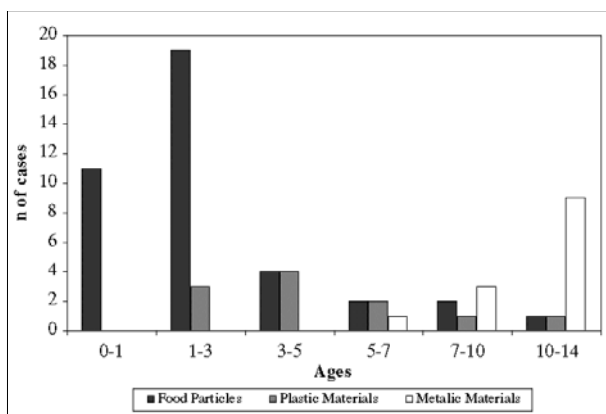


Figure 2. Distribution of aspirated foreign bodies in the tracheobronchial tree.

Foreign body aspiration is a life threatening and common medical emergency in childhood. Most authors show foreign body aspirations as one of the major causes of mortality among children [3,4,6]. Foreign body aspiration is the cause of death for more than 300 children each year in USA [4]. Foreign body aspirations have a bad prognosis among children because of their narrow tracheobronchial system and poorly developed protection mechanism [1,2,5]. Sudden onset of choking, irritant cough and wheezing are the major symptoms [1-5]. Clinicians should keep foreign body aspirations in mind in children with persistent and intractable respiratory tract infections. In 21 patients with suspicion of foreign body aspiration 17 had chronic pulmonary infection. Of these 21 patients 12 (57.1%) had foreign bodies. Roentgenograms are useful but a suspicion for foreign body aspiration should direct the clinicians to bronchoscopy [3,5,6]. In 10 patients (7.5%) who were emergently taken to direct bronchoscopy only with the positive history and physical findings we found aspirated foreign bodies in all confirming our diagnosis which indicates a powerful positive history and typical physical findings are imperial in diagnosis and time sparing in intervention. Clinically, the decision to perform bronchoscopy becomes more important when the history and physical findings are uncertain. In such cases, considering the irreversible complications of a retained foreign body, the bronchoscopic examination must not be delayed even in the presence of least suspicion [4,6,7]. That we found foreign bodies in 51 of 54 cases (94.4%) with suspected foreign body aspiration is an evidence supporting this approach. Diagnosis is easy if the foreign body is radiopaque but small particles arrested in laryngotracheal area or main bronchus may give no or poor radiological findings [5,6].

Fluoroscopy may be helpful in this situation [4,7]. In our series, children were evaluated with PA and lateral chest roentgenograms. Air trapping and infiltration were the most frequent radiological findings. This shows a similarity with previous reports [2-7].

The size, shape and the kind of the foreign body directly effect the clinic and radiological findings [7]. Coexistent tissue reactions like inflammation and secretion caused by organic foreign bodies were much severe than that of the metal objects. Foreign body aspirations occur more often in the first 3 years of life [3,4,7]. Children at this year band are more active and curious in discovering their surroundings. Their chewing functions are not well developed. This weaning period to the solid food is the most dangerous time for food particle aspirations [2]. A suspicion of foreign body aspiration should direct the clinician to diagnostic and operative bronchoscopy. The foreign body may migrate and obstruct an airway, which may lead to fatal results [5,8]. Food such as beans, peanuts may swell and cause mechanical obstruction by time [2,3]. Socio-cultural characteristics are important in the kind of foreign bodies. Peanuts are the most common organic foreign body in USA and Europe where as sunflower and watermelon seeds are much more encountered in our country [5]. Also pin and turban pin (headscarf needles) aspirations are common in 10-14 year age girls in our country. This situation can be explained with the usage of turban [2,9].

Foreign bodies have a tendency to arrest in right bronchial system. The angle of right main bronchus, trachea's deviation and children's habit of lying on one side may explain this situation [1,5]. Foreign bodies arrest centrally in children whereas they tend to arrest peripherally in adults [3,4,7]. In our series the majority of the foreign bodies were found to be arrested in the tracheal region and this was thought to be related with the patients' ages to be concentrated in the 0-5 years (54.6%) group.

Bronchoscopy is the only effective method in the diagnosis and treatment of foreign body aspirations. We prefer rigid bronchoscope because of its advantages such as short operative time, opportunity of using many different forceps, and effective interference to hemorrhages [1-4]. Some authors prefer flexible bronchoscope in peripherally arrested foreign bodies because of its better vision and easy manipulation in reaching the foreign bodies. Some clinics use flexible bronchoscope routinely in adults [10-12].

Reugemer and associate [8] reported a case of 8 years old child in which flexible and rigid bronchoscopes were used together for the removal of the foreign body successfully. When a peripherally located foreign body, which is fairly difficult to reach with a rigid bronchoscope is concerned, combined use with a flexible bronchoscope gives rise to an excellent visualization and maneuverability ultimately avoiding surgical removal [13]. However it should be kept in mind that flexible bronchoscopy is not routinely used for foreign body extraction due to poor airway control [14]. We use rigid bronchoscope in our clinic. In our series, all foreign bodies, except 3 children, were removed at the first attempt. In 2 of these 3 children a second bronchoscopy was needed and foreign bodies were removed at the second intervention. One single child was taken to thoracotomy and bronchotomy due to a pen cup aspiration. When we compare our experience in these 75 cases with the

literature we can deduce that bronchoscopy is the gold standard in both diagnosis and treatment of cases whose either definite diagnosis have been made to have aspirated foreign bodies or who has predictive clinical pictures like chronic pulmonary infection, bronchiectasis therefore bearing in mind the suspicion of aspiration.

- Obtaining an attentive history and a through physical examination,
- Through preparation and being alert for the complications,
- Good coordination with the anesthesia team,
- Repeating the bronchoscopy after the removal of the foreign body especially when the aspirated foreign body is organic in nature (evaluating the changes in the respiratory tract and controlling the airways for residual pieces),
- Reducing the operative time will increase the rate of success and decrease the complication rate.

Rigid bronchoscopy and removal of foreign bodies with forceps under general anesthesia is an efficient and safe method and we recommend its wider use even in the presence of predictive clinical pictures.

References

1. Baharloo F, Veyckemens F, Francis C, Biettlot MP, Rodenstein DO. Tracheobronchial foreign bodies. Presentation and management in children and adults. *Chest* 1999;5:1357-62.
2. Kaptanođlu M, Kunt T, Kunt N, Dođan K, Markođ ½. Yabancı cisim inhalasyonu (119 Olgunun Gözden Geçirilmesi) *Türk Göğüs Kalp Damar Cer Derg* 1995;3:78-81.
3. Pađaođlu <, Dođan R, Demircin M, et al. Bronchoscopic removal of foreign bodies in children: Retrospective analysis of 822 cases. *Thorac Cardiovasc Surg* 1991;39:95-8.
4. Black R, Johnson D, Matlak M. Bronchoscopic removal of aspirated foreign bodies in children. *J Pediatr Surg* 1994;29:682-4.
5. Steen KH, Zimmermann T. Tracheobronchial aspiration of foreign bodies in children: A study of 94 cases. *Laryngoscope* 1990;100:525-9.
6. Zerella JT, Dimler M, McGill LC, et al. Foreign body aspiration in children: Value of radiography and complications of bronchoscopy. *J Pediatr Surg* 1998;11:1651-4.
7. Mu L, Sun D, He P. Radiological diagnosis of aspirated foreign bodies in children: Review of 343 cases. *J Laryngol Otol* 1990;104:778-2.
8. Reugemer JL, Perkins JA. Combined rigid and flexible endoscopic removal of a BB foreign body from a peripheral bronchus. *Int J Pediatr Otorhinolaryngol* 1999;47:77-80.
9. Dayođlu E, Rahimi M, Tokar A. ve ark. Bronđ içi yabancı cisimler: Türban iđnesi komplikasyonlar. *Türk Göğüs Kalp Damar Cer Derg* 1995;3:82-5.
10. Limper AH, Prakash UBS. Tracheobronchial foreign bodies in adults. *Ann Intern Med* 1990;112:604-9.
11. Chen C, Lai C, Tsai T, et al. Foreign body aspiration into the

- lower airway in Chinese adults. Chest 1997;112:129-33.
12. Debeljak A, Šorli J, Mušič E, et al. Bronchoscopic removal of foreign bodies in adults: Experience with 62 patients from 1974-1998. Eur Respir J 1999;14:792-5.
13. Wood RE, Gauderer MWL. Flexible fiberoptic bronchoscopy in the management of tracheobronchial foreign bodies in children: The value of a combined approach with open tube bronchoscopy. J Pediatr Surg 1984;19:693-8.
14. Monden Y, Morimoto T, Uyama T, Kimura S. Flexible bronchoscopy for the foreign body in the airway. J Exp Med 1989;36:35-9.