

Koroner Bypass Ameliyatı Sonrasında Gelişen Reküran Aortik Psödoanevrizma

RECURRENT MYCOTIC PSEUDOANEURYSM OF THE AORTA AFTER CORONARY ARTERY BYPASS

Yusuf Kenan Yalçınbaş, Ersin Ereğ, Ece Salihoğlu, *Cemal Şenyuva, **Servet Alan, Tayyar Sarıoğlu

İstanbul Memorial Hastanesi, Kalp Damar Cerrahisi Kliniği, İstanbul

**İstanbul Memorial Hastanesi, Plastik ve Rekonstrüktif Cerrahi Kliniği, İstanbul*

***İstanbul Memorial Hastanesi, Enfeksiyon Hastalıkları Kliniği, İstanbul*

Özet

Koroner bypass cerrahisinde sadece sol mammaryan interna grefti kullanılan hastalarda, diyabet ve ileri yaş söz konusu olmasa bile mediastinit riski mevcuttur. Bu vakada koroner bypass cerrahisi sonrasında mediastinit ve aortada psödoanevrizma gelişen bir hastada perikardiyal yama tamiri ve serbest miyokutanöz latissimus dorsi flebi ile mediastinal rekonstrüksiyon sonrasında gelişen nüks aortik psödoanevrizma tarif edilmiştir.

Anahtar kelimeler: Psödoanevrizma, aort, koroner bypass

Türk Göğüs Kalp Damar Cer Derg 2004;12:52-54

Summary

Even in young non-diabetic patients with single internal mammary artery, the risk for mediastinitis still exists. Free latissimus dorsi myocutaneous flap was chosen to repair the mediastinal defect and to protect the aortic patch repair for this case with pseudoaneurysm of the aorta after coronary artery bypass. Although the early result was successful, pseudoaneurysm recurred. Lifelong antibiotic therapy could be useful in order to prevent the recurrence of this fatal complication.

Keywords: Pseudoaneurysm, aorta, coronary bypass

Turkish J Thorac Cardiovasc Surg 2004;12:52-54

Introduction

Coronary artery bypass graft surgery (CABG) has become a routine in cardiac surgery since 1970. The most important contribution to the longevity of the grafts was the use of internal mammary artery (IMA). Graft patency rates for IMA were over 90% after 10 years in most of the series where patency rates of the vein grafts were almost 50% in 10 years. On the other hand routine use of internal mammary arteries increased the risk of mediastinitis in patients with certain risk factors. The risk for mediastinitis is increased significantly if bilateral IMA are used in diabetic and elderly patients, however 1% risk exists even in young non-diabetic patients with single IMA [1,2]. When post-CABG mediastinitis occurs (fever, leukocytosis, persistent purulent drainage, pain, sternal instability) it should be treated aggressively with surgical debridement and tissue flaps if needed. Longterm intravenous antibiotic therapy (6 weeks) is mandatory. If these measures are not taken properly deep sternal infection continues and secondary complications arise such as aortic pseudoaneurysm. Once it occurs it is very difficult to cure this complication. Here we present the surgical management of a patient with recurrent mediastinitis after repair of mycotic pseudoaneurysm of the ascending aorta.

Case

The patient was a 57 years old male patient who underwent CABG 10 years ago (left IMA to left anterior descending artery). He developed staphylococcus aureus mediastinitis early after the operation and multiple surgical procedures and long course of parenteral antibiotics were used to eradicate the infectious process. However, he was left with sternal osteomyelitis and chronic cutaneous fistula from which he occasionally drained significant amount of fresh blood. He presented himself to us seeking a definitive cure for this long lasting and debilitating problem which put the patient and his family into a severe depression of the chronic disease. We started workup with a computer tomography of the chest and revealed a pseudoaneurysm of ascending aorta (6x5 cm) that eroded the upper right part of the sternum. Preoperative angiography delineated the pseudoaneurysm of the ascending aorta, significant proximal right coronary artery stenosis, patent LIMA graft and good left ventricle function (Figure 1). Echocardiography confirmed good left ventricular and valvar functions without any fistulous connection with the pseudoaneurysm cavity. Operation was done under deep hypothermia and circulatory arrest through the trap door opening of the sternum with femoral cannulation. Pseudoaneurysmal cavity was resected and the opening on the ascending aorta was closed with autologous pericardial patch. Innominate to right coronary artery saphenous bypass was

Adres: Dr. Yusuf Kenan Yalçınbaş, İstanbul Memorial Hastanesi, Kalp Damar Cerrahisi Kliniği, İstanbul
e-mail: ykyalcinbas@hotmail.com

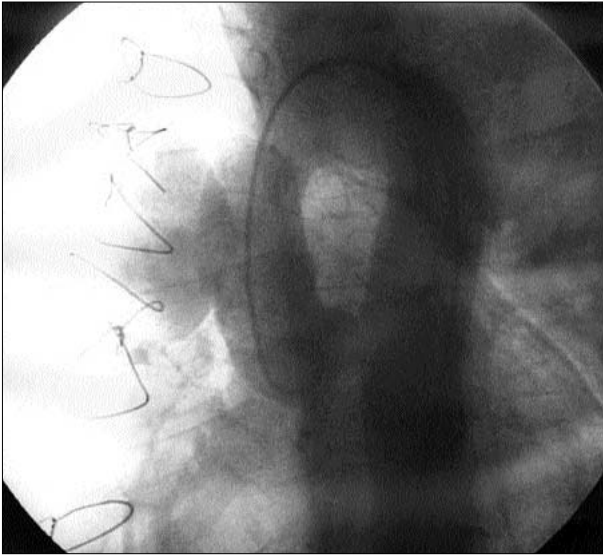


Figure 1. Preoperative aortography delineating pseudoaneurysmal pouch at the ascending aorta.

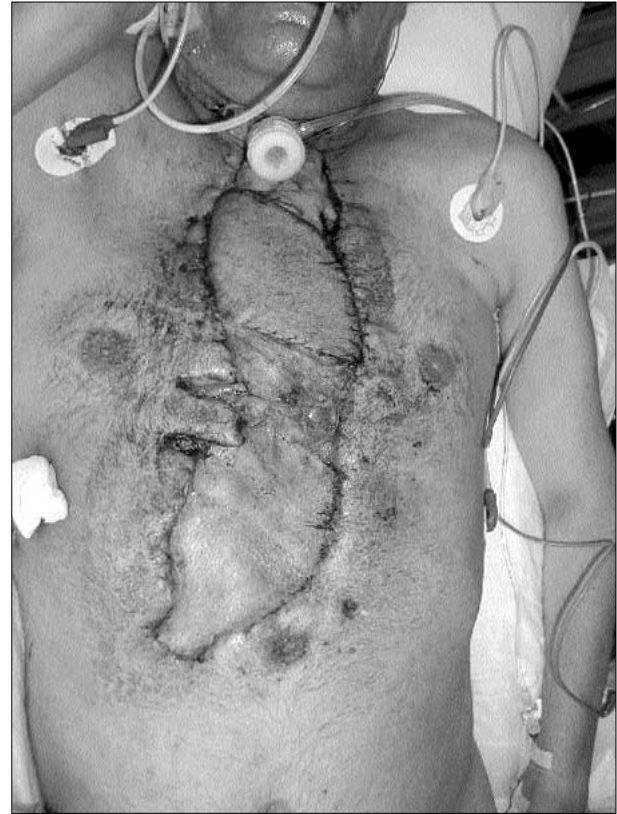

Figure 2. Sternal and mediastinal area after extensive reconstruction with free latissimus dorsi graft and skin grafts.

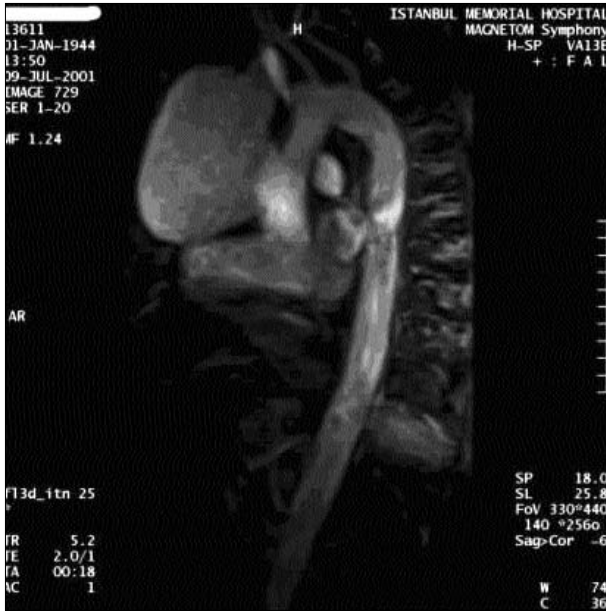

Figure 3. Postoperative magnetic resonance image depicting the recurrence of the aortic pseudoaneurysm three months after extensive reconstruction.

performed and sternum was closed after sternal, subcutaneous and cutaneous debridement. Early postoperative days were uneventful. He was extubated on the first postoperative day and transferred to the ward on the second postoperative day. On the 4th postoperative day serous discharge from sternal incision appeared, and on 6th postoperative day the patient was taken to the operating room with sternal dehiscence, bilateral emphysema. Extensive debridement and partial sternectomy with repair was done and intravenous vancomycin, gentamycin, closed drainage with diluted povidone iodine solution continued. Due

to persistent infection and sepsis the sternum was left open and debridements were continued. There was a huge mediastinal defect. Cultures were positive for *staf. aureus*. After long-term open debridement, the patient was prepared for reconstructive surgery. For reconstructive surgery the left latissimus muscle was prepared as a free myocutaneous flap and anastomosed to superior tiroideal artery and external jugular vein. Remaining skin defects were closed using skin grafts taken from the left thigh (Figure 2). The patient was discharged after three months in good condition. Unfortunately one month after discharge patient came back with recurrent aortic pseudoaneurysm about 7x7 cm size (Figure 3). Patient denied reintervention and died of sepsis and mediastinal compression.

Discussion

After open heart surgery and coronary artery bypass became routine in 1970s, mediastinitis has been observed more frequently because median sternotomy has been the standard approach and mammary artery has been used increasingly in diabetic and elderly. Still today mediastinitis after heart surgery is a rare but life threatening condition which occurs in 0.5-5% of cases. Previous sternotomy, diabetes mellitus-especially insulin dependent type, long preoperative hospital stay, complex surgery, single or bilateral IMA use, old age, long operative time, back for bleeding, long intensive care unit stay, cardiopulmonary resuscitation, obesity, obstructive lung

disease have all been shown to be responsible factors. Acute complications of mediastinitis are related to massive tissue destruction of the vital organs as heart and lung, and multi-organ failure with sepsis and death. Chronic complications of mediastinitis include sternal non-union, chronic osteomyelitis with cutaneous fistula, aortic pseudoaneurysm, graft pseudoaneurysm, pulmonary artery fistula, compression to cardiac chambers and major arteries and veins [3,4]. Infectious agent is staf. aureus and staf. epidermidis which are colonized in patients skin most of the time whereas gram negative agents are occasionally seen from different sources. Whatever the causative agent is, the underlying problem is tissue trauma, hypoperfusion and metabolic derangements which is the basis for low resistance area for immune defense systems. Current therapy is early reintervention with extensive debridement, closed drainage with diluted vancomycin or povidone iodine irrigation, sternal re-fixation with Robicsek technique and longterm antibiotics (4-6 weeks). Persistent mediastinitis is a life threatening condition which occurs despite medical and surgical therapy. In difficult and resistant cases reconstructive techniques as omentum, rectus, latissimus dorsi flaps with radical debridement including costochondral arches, manubrium and sternoclavicular joints is mandatory. In this case free latissimus dorsi myocutaneous flap was chosen because of a huge tissue defect and to protect the aortic patch repair [5]. Pectoral, rectus muscles and omentum were not suitable alternatives due to patients' particular problems

(atrophy, ileus, lack of IMA supply bilaterally). Although the early result was successful, pseudoaneurysm recurred and lifelong antibiotic therapy could be useful in order to prevent the recurrence of this fatal complication.

References

1. Milano CA, Kesler K, Archibald N, Sexton Dj, Jonas RH. Mediastinitis after coronary bypass graft surgery. Risk factors and long-term survival. *Circulation* 1995;92:2245-51.
2. Eckstein FS, Albes JM, Jurmann MJ. Surgical management of persistent mediastinitis after coronary bypass grafting. *Ann Thorac Surg* 1997;64:854-6.
3. Sabri MN, Henry D, Wechsler AS, Di Sciascio G, Vetovec GW. Late complications involving the ascending aorta after cardiac surgery: Recognition and management. *Am Heart J* 1991;121:1779-83.
4. Sullivan KL, Steiner RM, Smullens SN, Griska L, Meister SG. Pseudoaneurysm of the ascending aorta after cardiac surgery. *Chest* 1988;93:138-43.
5. Banic A, Ris HB, Erni D. Free latissimus dorsi flap for chest wall repair after complete resection of infected sternum. *Ann Thorac Surg* 1995;60:1028-32.