

Subklavyan Arterin Beyin ve Kalpten Çalması: Olgu Sunumu

SUBCLAVIAN ARTERY STEAL FROM BOTH OF HEART AND BRAIN: CASE REPORT

Cenk Tataroğlu, *Ramazan Akdemir, **Hüseyin Gündüz, **Cihangir Uyan

Abant İzzet Baysal Üniversitesi Düzce Tıp Fakültesi, Kalp Damar Cerrahisi Ana Bilim Dalı, Düzce

*Abant İzzet Baysal Üniversitesi Düzce Tıp Fakültesi, Kardiyoloji Ana Bilim Dalı, Düzce

**Abant İzzet Baysal Üniversitesi Bolu Tıp Fakültesi, Kardiyoloji Ana Bilim Dalı, Bolu

Özet

Altmışsekiz yaşında erkek hasta koroner ve serebrovasküler yetmezlik bulguları ile müracaat etti. Sol kolun motor aktivitesi semptomların ortaya çıkmasına neden oluyordu. Hasta on sene önce koroner bypass ameliyatı geçirmişti ve bu yeni bulgular iki sene önce başlamıştı. Anjiyografik incelemede subklavyan arterin başlangıçta tam tıkalı olduğu ve sol internal mammaryan arter ile sol ön inerkoroner arterden, sol vertebral arterle de santral sinir sisteminden subklavyan distaline kaçak gözlemlendi. Koroner ve subklavyan çalma sendromunun her ikisinin de semptomlarının görülmesi klinikte nadir olarak rastlanılan bir durumdur.

Anahtar kelimeler: Subklavyan çalma sendromu, koroner, serebral

Türk Göğüs Kalp Damar Cer Derg 2004;12:280-282

Summary

We report a 68-year-old patient who presented with symptoms of both coronary and cerebrovascular insufficiency. Physical activity of the left arm aggravated the occurrence of symptoms. He received a coronary bypass operation ten years ago and symptoms of double insufficiency started two years ago. Angiographic examination demonstrated total occlusion of the subclavian artery and stealing of subclavian artery from the left anterior descending artery via the left intrnal mammary artery and from brain via the left vertebral artery. Symptomatic coronary steal syndrome together with subclavian steal syndrome is a recognised but uncommon cause of coronary and cerebral ischemia.

Keywords: Subclavian, steal syndrome, coronary, cerebral

Türk Göğüs Kalp Damar Cer Derg 2004;12:280-282

Introduction

Symptomatic occlusive disease of the upper great vessels occurs infrequently. This case report is about a previously operated coronary artery bypass patient who developed symptoms of coronary ischemia and vertebrobasilar insufficiency concomitantly.

Severe stenosis or total occlusion of the left subclavian artery may lead to myocardial ischemia and angina. The pathophysiology parallels that of subclavian steal syndrome. In the presence of severe subclavian artery stenosis flow of internal mammary artery (IMA) may be reversed leading to cardiac ischemia. This rare phenomenon is called coronary-subclavian steal syndrome (CSSS). The problem is often neglected in the differential diagnosis of recurrent angina. Same steal phenomenon may work for an other branch of subclavian artery for example vertebral artery and leads to vertebrobasilar insufficiency.

Case Report

A-68- year old man with previously documented coronary artery disease presented with symptoms of the left upper

extremity paresthesia and paresis, intermittent chest pain especially with physical activity of the left arm. He also declared to have experienced vertigo and blurred vision many times with physical activity. He had undergone two vessel coronary bypass operation ten years ago and had been symptom free till two years ago. During the following two years, vertigo and angina pectoris increased in intensity and frequency. Sublingual nitroglycerine would relieve the symptoms of angina but not the cerebral symptoms. At the current admission pulses of the left arm could not be palpated neither the blood pressure could be measured. However the skin temperature was not different and the perfusion of nailbeds was normal. The electrocardiogram revealed a chronic inferior wall myocardial infarction. There was slight cardiomegaly on chest graphy.

Coronary angiography demonstrated an occlusive disease of the left anterior descending artery (LAD) and the right coronary artery, but circumflex artery was free of a stenotic lesion. The left IMA was patent and filled by LAD in retrograde fashion. The arch aortography and selective left subclavian arteriography demonstrated a proximally total occlusion of the subclavian artery. Selective arteriography to the right common carotid artery revealed 90% obstruction at very proximal of the right internal carotid artery and spontaneous visualization of

Adres: Dr. Cenk Tataroğlu, Abant İzzet Baysal Üniversitesi Düzce Tıp Fakültesi, Kalp Damar Cerrahisi Ana Bilim Dalı, Düzce

e-mail: ctataroglu@yahoo.com

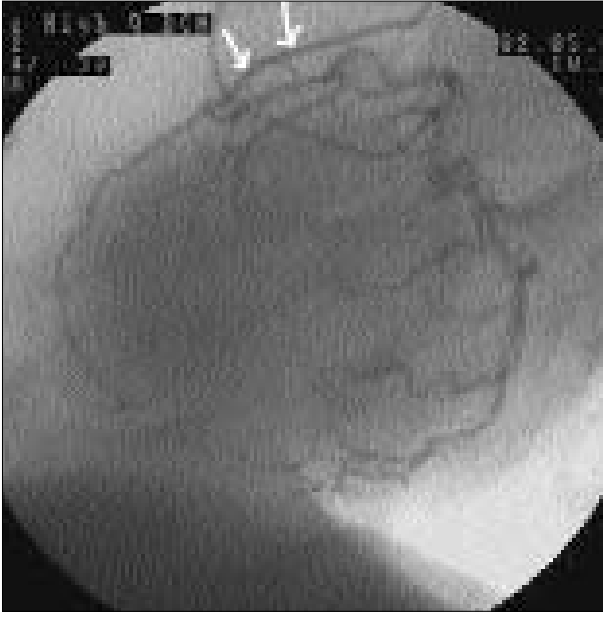


Figure 1. (a) Coronary angiography demonstrated retrograde filling of the left IMA from LAD.

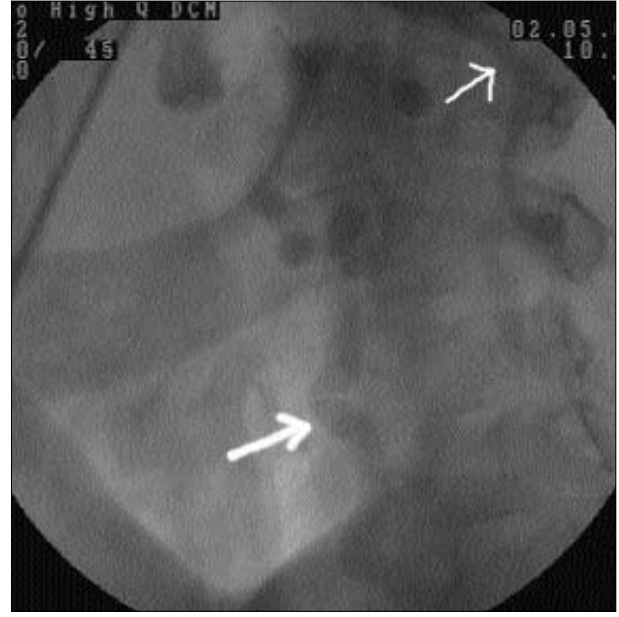


Figure 1. (c) Early visualization of the left vertebral artery after radiopaque injection to the right innominate artery.

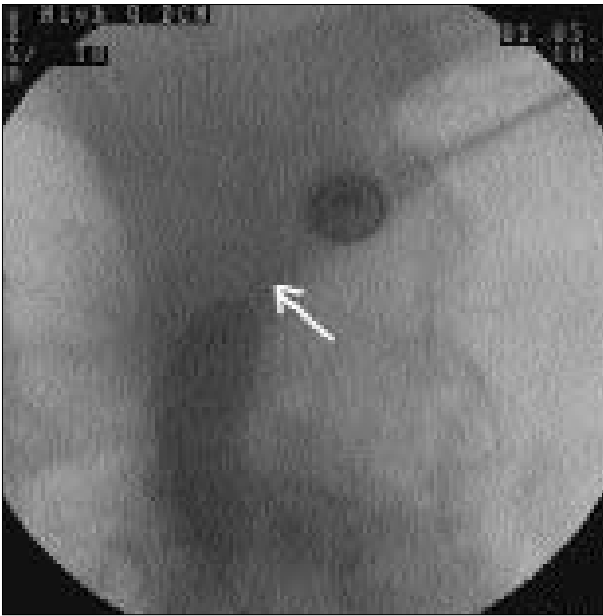


Figure 1. (b) Selective left subclavian arteriography revealed total obstruction.

the left vertebral artery short after radiopaque was injected into the innominate artery (Figure 1).

Discussion

During the last decade, the demographic characteristics of patients who presented for elective coronary revascularization

were changed. More elderly and high risk patients, including those with generalized atherosclerosis, have been undergoing operation. This group includes patients with concomitant occlusive disease of the coronary arteries and great vessels. Severe stenosis or total occlusion of the left subclavian artery may lead to myocardial ischemia and angina due to reduced or reversed blood flow through a previously placed IMA bypass graft to the coronary artery. The frequency of CSSS is reported to be between 0.4 and 1.1 percent in coronary artery bypass patients [1,2]. Most often the diagnosis of CSSS is brought to attention by recognition of reversed blood flow in IMA during routine post operative angiography. Most authors regard this as a diagnostic finding.

Total cerebral blood flow significantly decreases in patients with subclavian steal syndrome in which the neurologic symptoms come out. Subclavian steal phenomenon can be more likely to cause significant neurologic symptoms in patients with disease in other arteries supplying the brain. This patient's neurologic findings can be attributed to internal carotid stenosis and contralateral subclavian obstruction presenting together and enhancing their effects to steal blood of the brain.

Subclavian stenosis or occlusion can be diagnosed by ultrasonography or more recently by magnetic resonans imaging [3]. It is utmost important to diagnose subclavian stenosis before bypass surgery. Bilateral upper extremity blood pressure measurements are an excellent screening tool for detecting the presence of subclavian artery stenosis. A blood pressure difference of more than 20 mmHg is highly suggestive of subclavian artery stenosis [4]. However the absence of difference in extremity blood pressure does not exclude the presence of subclavian artery stenosis because the frequent occurrence of innominate, bilateral subclavian, and diffuse atherosclerotic occlusive disease in these patients [5]. When

screening for subclavian artery stenosis it is advocated ultrasonographic duplex scanning with hemodynamic measurements before and after exercise to be more reliable than the assessment for discrepancy in upper extremity blood pressure. This method is also effective for documenting patency after an interventional procedure [6].

After the presence of CSSS is ascertained there are various treatment modalities. Treatment of CSSS is directed towards treating the subclavian artery stenosis. Successful correction with relief of symptoms has been accomplished by carotid subclavian bypass [7], angioplasty [8], or atherectomy [9] of the subclavian artery. Before deciding the type of interventional procedure it is exceedingly important to visualize the arch vessels in order not to omit an other stenotic lesion in this multicircular system. This will help us to fully comprehend the pathophysiology and determine the right strategy.

References

1. Gutierrez GR, Mahrer P, Aharonian N, Mansukhani P, Bruss J. Prevalence of subclavian artery stenosis in patients with peripheral vascular disease. *Angiology* 2001;52:1899-4.
2. Olsen CO, Dunton RF, Maggs PR, Lahey SJ. Review of coronary-subclavian steal following internal mammary artery-coronary artery bypass surgery. *Ann Thorac Surg* 1998;46:667-78.
3. Tuseth V, Hegland ³, Fjetland L, Nilsen DWT. Reversed flow in internal mammary artery conduit and vertebral artery with left subclavian artery occlusion causing angina and vertigo the coronary-subclavian steal syndrome. *Int J Card* 2001;79:311-4.
4. Marshall WG Jr, Miller EC, Kouchoukos NT. The coronary-subclavian steal syndrome: report of a case and recommendations for prevention and management. *Ann Thorac Surg* 1998;46:93-6.
5. Takach TJ, Reul GJ, Cooley DA. Concomitant occlusive disease of the coronary arteries and great vessels. *Ann Thorac Surg* 1998;65:79-84.
6. Takach TJ, Reul GJ, Gregoric I. Concomitant subclavian and coronary artery disease. *Ann Thorac Surg* 2001;71:187-9.
7. Fitzgibbon GM, Keon WJ. Coronary-subclavian steal : a recurrent case with notes on detecting the threat potential. *Ann Thorac Surg* 1995;60:1810-2.
8. Shapira S, Braun SD, Puram B. Percutaneous transluminal angioplasty of proximal subclavian artery stenosis after left internal mammary to left anterior descending artery bypass surgery. *J Am Coll Cardiol* 1991;18:1120-3.
9. Breall JA, Grossmann W, Stillmann IE. Atherectomy of the subclavian artery for patients with symptomatic coronary subclavian steal syndrome. *J Am Coll Cardiol* 1993;21:1564-7.