

Delici Kesici Alet Yaralanmasına Bağlı Bir Femoral Arteriyovenöz Fistül Olgusu: Stent Greft ile Başarısızlık ve Cerrahi Onarım

A CASE OF FEMORAL ARTERIOVENOUS FISTULA DUE TO STAB WOUND: CONSECUTIVE FAILURE TO CLOSE WITH STENT GRAFT AND THE FINAL SURGERY

Bayer Çınar, Onur Göksel, *Sinan Şahin, Veysel Şahin, Hakkı Aydoğan, Uğur Filizcan, Şebnem Çetemen, Ergin Eren

Siyami Ersek Göğüs Kalp Damar Cerrahisi Eğitim ve Araştırma Hastanesi, Kalp Damar Cerrahisi Kliniği, İstanbul
*Siyami Ersek Göğüs Kalp Damar Cerrahisi Eğitim ve Araştırma Hastanesi, Radyoloji Kliniği, İstanbul

Özet

Asemptomatik olabildiği gibi, ağrı, ödem, variköz venler ve kalp yetersizliği ile kendini gösterebilen travmatik arteriyovenöz fistüllerin tanı ve tedavisinde genel kanının aksine büyük zorluklar kendini gösterebilir. Tedavide gecikme amputasyon ile sonuçlanabilir. Bu olgu sunumunda Ekim 2002'de sağ uyluk lateralinden delici-kesici aletle yaralanma öyküsü olan 23 yaşında erkek hastayı bildirmek istedik. Mart 2003'de hastanemize başvurana kadar 2 kez perkütan stent uygulaması denenen; ancak sağ bacakta ödem, safen venlerde ileri derecede genişleme gibi şikayetleri devam eden bu hastayı sunmaktayız. Girişimsel radyologların ve kardiyovasküler cerrahların güçlü bir iletişim içinde bulunması gereken bu konuda, literatüre de baktığımızda daha fazla deneyimin gerektiği ortaya çıkmaktadır.

Anahtar kelimeler: Arteriyovenöz fistül, vasküler travma, stent greft

Türk Göğüs Kalp Damar Cer Derg 2005;13:174-176

Summary

Clinicians may experience greater difficulties in diagnosis and management of traumatic arteriovenous fistulae than usually anticipated. Such lesions may manifest as leg oedema, pain, varicose veins and even congestive heart failure, if not asymptomatic. Delay in diagnosis or management may end up with dramatic results such as amputation. In this case presentation, we would like to present a 23-year-old man with a history of stab wound from right lateral thigh. He had persistent symptoms in spite of two consecutive stenting until March, 2003. In the light of present medical literature and our experience, we believe that stent-closure of femoral arteriovenous fistulae requires further experience and strong cooperation between vascular surgeons and radiologists.

Keywords: Arteriovenous fistula, vascular trauma, stent-graft

Turkish J Thorac Cardiovasc Surg 2005;13:174-176

Geliş Tarihi: Şubat 2004

Revizyon: Mayıs 2004

Kabul Tarihi: 3 Haziran 2004

Introduction

An arteriovenous fistula (AVF) may be an incidental finding in an asymptomatic patient or it may manifest with pain, edema, varicosities and even heart failure [1]. The difficulties detecting post-traumatic vascular injuries are greater than appreciated. Delay in diagnosis will compromise management and potentially may lead to amputation [2]. Traumatic AVF's produce several profound pathophysiologic and structural changes such as arterial dilatation and aneurysm formation in the circulatory dynamics of the vessels associated with the fistula [3,4]. Our short report presents a patient with a traumatic femoral AVF which was attempted to be closed with stent-graft

ending up in persisting symptoms and signs.

Case

A 23 year-old man was admitted to our clinic with chronic progressive swelling of the right leg with visible engorgement of calf veins in March, 2003. He had a penetrating trauma on the lateral side of his mid-thigh in October, 2002. His symptoms appeared one month after initial treatment in a medical center where he later was diagnosed as having a pseudoaneurysm associated with an AVF between superficial femoral artery (SFA) and superficial femoral vein (FV) and had percutaneous attempt for closure of the fistula with overlapping

Adres: Dr. Onur Göksel, Siyami Ersek Göğüs Kalp Damar Cerrahisi Eğitim ve Araştırma Hastanesi, Kalp Damar Cerrahisi Kliniği, İstanbul
e-mail: onurgoksel@hotmail.com

two stent-grafts. When he was admitted to our hospital, both greater and lesser saphenous veins of his edematous right leg were significantly distended with palpable thrill. Typical murmur was audible at the level of the stab wound. His digital subtraction angiography (DSA) showed distended popliteal and crural veins and no contrast passage to the distal arterial system below the stent-graft (Figure 1). In collaboration with interventional radiology, surgery was anticipated to restore normal anatomy. In the operation suite under epidural anesthesia and mild sedation, right SFA and SFV were surgically prepared and an occlusive balloon catheter was introduced through left common femoral artery to the proximal part of the right SFA, just proximal part of the graft-stents, to avoid excessive hemorrhage due to extensive network of calf veins. After the conformation of the stent-grafts level by intraoperative DSA, the balloon relocated at the proximal of the lesion and a second incision was made at the level of the fistula. Reconstruction of the vessels walls with PTFE patches was attained by cutting the rigid stent-grafts and restoration of the arterial flow to distal femoral artery. Near to the end of procedure, arterial balloon was withdrawn. After reconstruction, a control DSA was achieved and the restoration of normal circulation was visualized (Figure 2). 125 mg/day of salicylic acid and low-dose coumadin were started postoperatively. He was discharged from the hospital on postoperative second day without any problems. On his 7th day control, edema on his leg was significantly diminished and had no signs of peripheral ischemia. At the end of the 1st month color Doppler study and DSA control at the end of 6th month revealed normal anatomy and circulation.

Discussion

Percutaneous management of AVF's or pseudoaneurysms is becoming more popular today being minimally invasive and enabling interventionists to discharge the patient on the next day of the operation. Major contraindication to stenting in femoral region is anatomic proximity of the lesion to femoral artery bifurcation and thus occlude the orifice of a major branch. As Matic A et al stated in their case report on a traumatic femoral AVF, detection and management of vascular injuries may be cumbersome [2]. This case report presents a contradictory case where insistent approaches may be harmful to the patient considering the potential complications of a percutaneous intervention despite being promising and less invasive. It may carry the risks of complications related to puncture site, stent implantation and even stent infection in the long term. Marin ML et al pioneered to describe stent-closure of a traumatic femoral AVF. They also added that additional clinical work must be done to establish the utility of this procedure [5]. There are many reports on successful stent-closure of AVF's at various anatomic localizations. However, as Onat L et al suggested [6], some colleagues are skeptical about the use of stenting in younger patients as in our case. An insistant approach in inexperienced centers may not be beneficial for the individual patient from the scope of surgery.

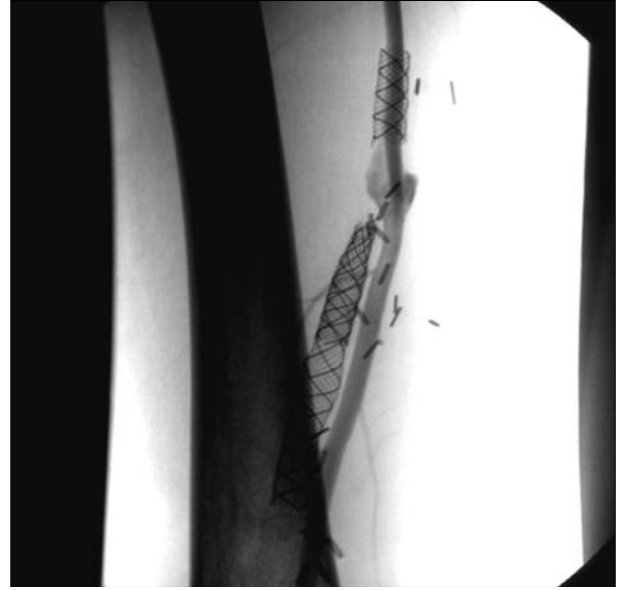


Figure 1. Rigid stents extending from superficial femoral artery to femoral vein.

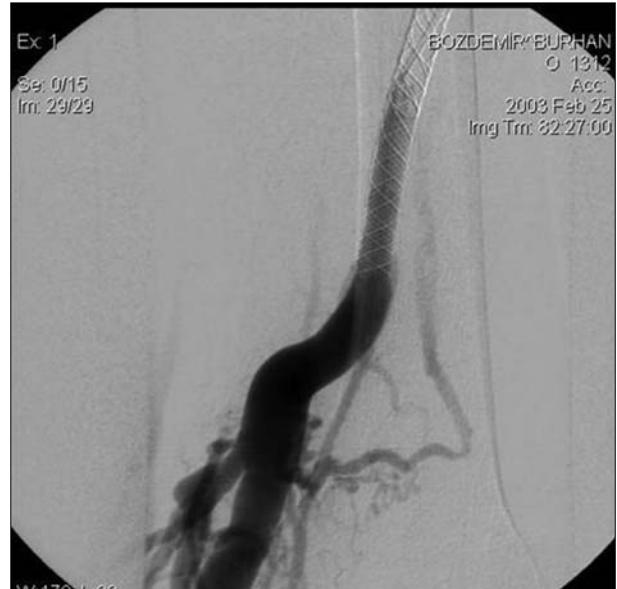

Figure 2. Control DSA angiogram after surgical repair of the AV fistule. Note that the parts of the rigid stents once placed inside another remain in the femoral vein.

References

1. Seaton DL. Traumatic arteriovenous fistula of the leg. An easily missed diagnosis. *J Fam Pract* 1998;46:2476-50.
2. Matic A, Rubin O, Matic D. Traumatic arteriovenous fistula. Case report and overview. *Rozhl Chir* 1996;75:489-91.

3. Stigall KE, Dorsey JS. Late complications of traumatic arteriovenous fistula. Case report and overview. *Am Surg* 1989;55:180-3.
4. Melliè D, Saada F, Becquemin JP. The risk of aneurysm. Another reason to treat traumatic arteriovenous fistulas surgically. *J Mal Vasc* 1987;12:277-9.
5. Marin ML, Veith FJ, Panetta TF et al. Percutaneous transfemoral insertion of a stented graft to repair a traumatic arteriovenous fistula. *J Vasc Surg* 1993;18:299-302.
6. Onat L, Karaman K, Şirvancı M, Aydın Ö, Olga R. Femoral Arteriyovenöz Fistülün Endovasküler Stent Greft ile Perkütan Tedavisi: Olgu Sunumu. *Türk Göğüs Kalp Dam Cer Derg* 2003;11:57-9.