

Aneurysm formation secondary to the use of a bovine vascular graft

Sığır vasküler grefti kullanımına bağlı anevrizma oluşumu

Murat Uğurlucan, Murat Başaran, Ufuk Alpagut, Enver Dayıoğlu, Ertan Onursal

Department of Cardiovascular Surgery, Medicine Faculty of İstanbul University, İstanbul

Biological vascular grafts have been used for the treatment of peripheral arterial diseases for more than 30 years. These materials carry various risks such as thrombosis, infection, and aneurysm formation. A 53-year-old male patient underwent femoropopliteal bypass operation with the use of a bovine mesenteric vein graft for left superficial femoral artery occlusion. He developed a pulsatile mass in the left inner thigh region a month after surgery, which was found to be a primary aneurysm of the xenograft. The aneurysmatic biologic material was replaced with a polytetrafluoroethylene graft. The patient was discharged on the sixth postoperative day without any complications.

Key words: Aneurysm; arterial occlusive diseases/surgery; bioprostheses; femoral artery/surgery; groin/blood supply; popliteal artery/surgery; postoperative complications; transplantation, heterologous.

The treatment of peripheral arterial diseases can be made by allografts, polytetrafluoroethylene (ePTFE) grafts, and biological heterografts.

Herein, we present a case treated with a bovine mesenteric vein graft for superficial femoral artery (SFA) occlusion. He developed graft aneurysm one month after the operation and the xenograft was replaced with an ePTFE graft.

CASE REPORT

A 53-year-old male patient was admitted to our institution with claudication of the left leg. His symptoms were of three-year duration, with a gradual increase in severity over time. He had a history of smoking for 35 years and there were deaths at young age in his family due to ischemic heart disease. On physical examination, the left femoral artery was palpable, but distal arteries were not. The ankle-brachial index was calculated to be 0.4. Aortoperipheral digital subtraction angiography demonstrated occlusion of the left SFA. An above-knee femoropopliteal bypass operation was performed and a bovine mesenteric vein graft, 6 mm x 40 cm in size, was

used. He was discharged on the postoperative fourth day without any complications.

After one month, he presented with a pulsatile mass in the left inner thigh region. Doppler ultrasonography showed enlargement of the graft. Computed tomography angiography showed primary aneurysm of the xenograft (Fig. 1a). Replacement of the aneurysmatic biologic material with an ePTFE graft was decided. During the operation, proximal and distal diameters of the xenograft measured 2.9 cm (Fig. 1b) and 3 cm, respectively. The differential diagnosis from false aneurysms was made with the intact suture lines. The bioprosthetic vascular graft was excised and a below-knee femoropopliteal bypass operation was performed with a ringed ePTFE graft 6 mm x 70 mm in size. The postoperative course was uneventful and the patient was discharged on the sixth postoperative day.

Anahtar sözcükler: Anevrizma; arteriyel tıkalıcı hastalık/cerrahi; biyoprotez; femoral arter/cerrahi; kasık/kan desteği; popliteal arter/cerrahi; ameliyat sonrası komplikasyon; transplantasyon, heterolog.

used. He was discharged on the postoperative fourth day without any complications.

Pathologic examination of the xenograft showed aneurysmatic dilatation of the xenograft together with accumulation of inflammatory granulation tissue including giant cells.

Received: September 13, 2004 Accepted: December 15, 2004

Correspondence: Dr. Murat Uğurlucan, İstanbul Üniversitesi İstanbul Tıp Fakültesi Kalp ve Damar Cerrahisi Anabilim Dalı, 34270 Çapa, İstanbul.
Tel: 0212 - 414 20 00 / 31267 e-mail: mugurlucan@yahoo.com

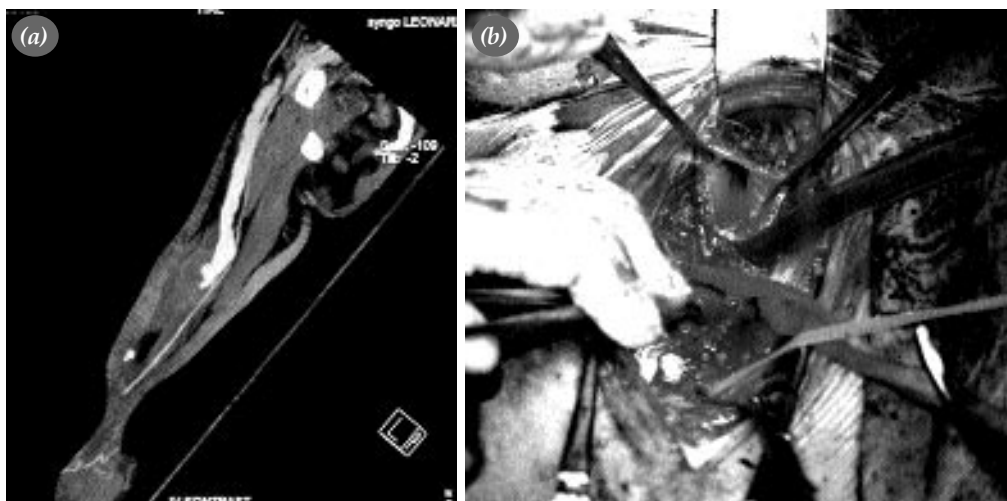


Fig. 1. (a) Computed tomography angiography revealed primary aneurysm of the xenograft. (b) Intraoperatively, the proximal end of the aneurysmatic xenograft measured 2.9 cm.

DISCUSSION

Vascular bioprostheses have been used for the treatment of peripheral arterial lesions since the early 1970s. They resemble human vessels in terms of elasticity.^[1] They are mainly preferred in the absence of autologous saphenous vein grafts.^[2-4] These bioprostheses are mainly used for hemodialysis access in chronic renal failure patients.^[5] However, they can also be used for various bypass procedures, including femoropopliteal bypass.

Xenografts may be associated with complications, one of which is thrombosis.^[6] When thrombosis occurs, replacement of the heterograft is recommended.^[6,7] Another complication is infection.^[6] Once the graft is infected, ligation and replacement of the graft are necessary. New anastomoses must be away from the previous anastomotic sites.^[6,7]

True or false aneurysm formation is another major complication. Aneurysm formation has been reported to be as high as 50%,^[2,6] with false aneurysms being more common.^[6] It is suggested that proteolytic digestion of foreign biomaterials mediates aneurysm formation. Collagenase exposure may also contribute to aneurysm formation in organic materials.^[8]

Aneurysms more commonly occur in proximally placed grafts^[6] and the risk increases by time.^[1,9] In case of an aneurysm, there is always a risk for rupture. Thus, excision and replacement of the graft are indicated. A new bypass can be performed using an ePTFE graft or a native saphenous vein. Many studies advocate that repeated use of biovascular prostheses should not be preferred.

Some studies have documented various disadvantages of vascular bioprostheses, especially low primary

patency rates when they are used for infrainguinal arterial reconstructions.^[3,4] Autologous saphenous veins are still the best choice for the treatment of peripheral arterial lesions. In case of absence of saphenous vein or when it is reserved for any other major surgical procedure, ePTFE grafts seem to be safer options when compared with biologic heterografts. We believe that xenografts warrant further research and experience.

REFERENCES

- Schroder A, Imig H, Peiper U, Neidel J, Peterleit A. Results of a bovine collagen vascular graft (Solcograft-P) in infrainguinal positions. *Eur J Vasc Surg* 1988;2:315-21.
- Rossi G, Munteanu FD, Padula G, Carillo FJ, Lord JW. Nonanastomotic aneurysms in venous homologous grafts and bovine heterografts in femoropopliteal bypasses. *Am J Surg* 1976;132:358-62.
- Kovalic AJ, Beattie DK, Davies AH. Outcome of ProCol, a bovine mesenteric vein graft, in infrainguinal reconstruction. *Eur J Vasc Endovasc Surg* 2002;24:533-4.
- Schmidli J, Savolainen H, Heller G, Widmer MK, Then-Schlagau U, Baumgartner I, et al. Bovine mesenteric vein graft (ProCol) in critical limb ischaemia with tissue loss and infection. *Eur J Vasc Endovasc Surg* 2004;27:251-3.
- Senkaya I, Aytac II, Eercan AK, Aliosman A, Percin B. The graft selection for haemodialysis. *Vasa* 2003;32:209-13.
- Garvin PJ, Castaneda MA, Codd JE. Etiology and management of bovine graft aneurysms. *Arch Surg* 1982;117:281-4.
- Hertzer NR, Beven EG. Venous access using the bovine carotid heterograft: techniques, results, and complications in 75 patients. *Arch Surg* 1978;113:696-700.
- Hamilton G, Megerman J, L'Italien GJ, Warnock DF, Schmitz-Rixen T, Brewster DC, et al. Prediction of aneurysm formation in vascular grafts of biologic origin. *J Vasc Surg* 1988;7:400-8.
- Schmitz-Rixen T, Megerman J, Anderson JM, Warnock DF, L'Italien GJ, Erasmii H, et al. Longterm study of a compliant biological vascular graft. *Eur J Vasc Surg* 1991;5:149-58.