

Incidentally detected syringe needles after 33 years of inhalation: a case report

İnhalasyondan 33 yıl sonra tesadüfen bulunan şırınga iğneleri: Olgu sunumu

Levent Dertsiz,¹ Gökhan Arslan,² Abid Demircan¹

Departments of ¹Thoracic Surgery and ²Radiology, Medicine Faculty of Akdeniz University, Antalya

Aspiration of foreign bodies is more common in pediatric patients than in adults. Sometimes patients with inhaled foreign bodies remain asymptomatic for a long period and the exact moment of aspiration cannot be elicited. Herein, we presented a 36-year-old male patient who aspirated syringe needles when he was a child. Three needles were incidentally detected on a routine X-ray film, two were located in the lung and one was in the thoracic wall. The patient had been asymptomatic for approximately 33 years. To our knowledge, this is the first case of aspirated syringe needles that remained asymptomatic for such a long time.

Key words: Bronchoscopy; foreign bodies/etiology/diagnosis; inhalation needles.

Aspiration of foreign bodies is a worldwide health problem and is more commonly seen in pediatric patients than in adults. Sometimes the exact time of aspiration cannot be determined. Depending on their composition and location in the tracheobronchial tree, foreign bodies may remain undiscovered for a long period of time because of the absence of specific symptoms.

We describe a patient who aspirated three syringe needles in his childhood, which were detected incidentally during a routine posteroanterior X-ray examination. Two of them were located in the lung, and the other in the thoracic wall.

CASE REPORT

A 36-year-old male underwent a chest X-ray study because of mild chest pain after a traffic accident that happened a month before. On posteroanterior and left lateral chest X-rays, three metallic densities were noted: one in the left lower lobe, one in the right middle lobe, and one in the subcutaneous region, anterior to the sternal body (Fig. 1). After a chest CT scan was

Yabancı cisim aspirasyonu çocuklarda yetişkinlere göre daha sık görülür. Bazen hasta yabancı cismi inhale ettikten sonra uzun süre asemptomatik kalabilir ve tam olarak ne zaman aspire edildiği bilinmeyebilir. Bu yazıda, çocukluğunda şırınga iğneleri aspire eden 36 yaşında bir erkek hasta sunuldu. İğneler, rutin göğüs filmi değerlendirmesinde ikisi akciğer dokusunda, üçüncüsü ise göğüs duvarında tesadüfen bulundu. Hastanın, aspirasyondan sonra yaklaşık 33 yıl asemptomatik kaldığı öğrenildi. Literatürde, aspire edilen yabancı cismin bu kadar uzun bir süre kaldığı başka bir olguya rastlanmadı.

Anahtar sözcükler: Bronkoskopi; yabancı cisim/etyoloji/tanı; inhalasyon; iğne.

obtained, the patient was referred to our hospital. The CT examination confirmed the presence of two needles in the lung parenchyma, and one in the subcutaneous fat anterior to the pectoral muscle (Fig. 2). The patient had no history of hemoptysis and his physical examination was normal. The needles were removed by a mini-thoracotomy (first the right one, and one month later the left one). All the needles exhibited marked corrosion and none had a bulbous metallic end (Fig. 3). After the removal of the needles, the patient was questioned whether he remembered any event regarding aspiration. He gave no clear history of aspiration. He only recalled, when he was three years old, spending six months with his father who had been a health technician, performing injections in his house. Because of a divorce, he had to leave his father and had never seen him since then.

DISCUSSION

Foreign body inhalation in adults may occur in certain clinical conditions such as cerebrovascular accidents, cerebral palsy, mental retardation, seizures, trauma with

Received: February 5, 2005 Accepted: June 13, 2005

Correspondence: Dr. Levent Dertsiz, Akdeniz Üniversitesi Tıp Fakültesi Göğüs Cerrahisi Anabilim Dalı, 07070 Antalya.
Tel: 0242 - 227 43 43 e-mail: leventdertsiz@hotmail.com

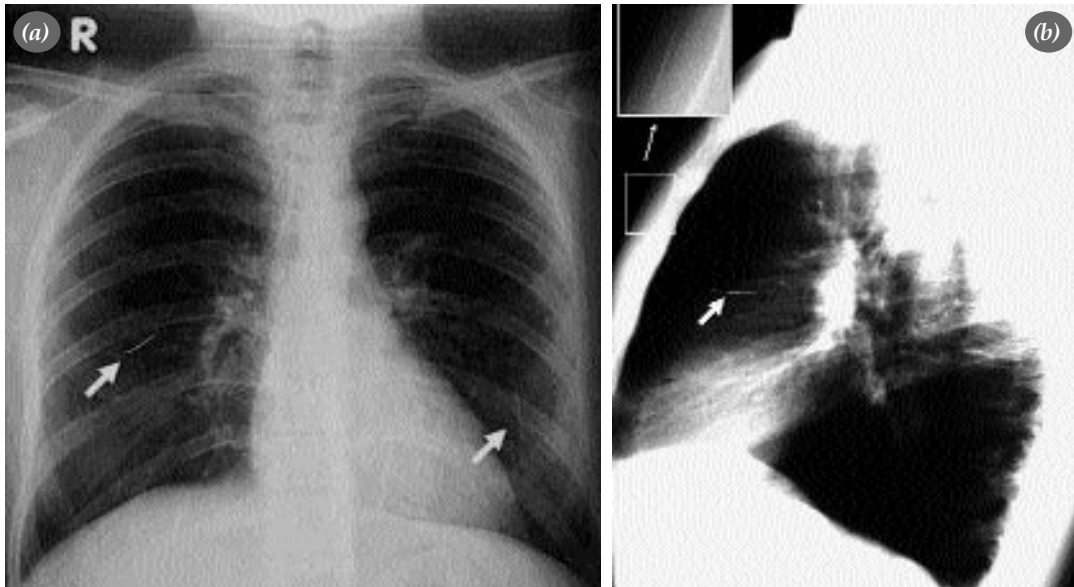


Fig. 1. (a) A posteroanterior chest radiograph showing three needles, one in the right middle zone, and two in the left paracardiac region. (b) On a lateral radiograph, a needle is seen in the subcutaneous and retrosternal region.

loss of consciousness, general anesthesia, alcoholism, brain tumors, and Parkinson's disease.^[1-4] But if there is no predisposing factor, childhood period must be questioned for aspiration history. Aspiration of various substances into the airways and lungs may cause a variety of pulmonary complications ranging from recurrent hemoptysis to irreversible damage of obstructed airways or parenchyma.^[2,4]

When a foreign body is inhaled into the distal bronchial system without causing an acute obstruction, it may remain silent for a while depending on its nature. Patients with inhaled small inorganic materials usually remain asymptomatic for a longer period of time unless

total obstruction of a distal airway happens. Foreign body aspiration in adults may remain undetected for years, with a delay in diagnosis of up to 16 and even 25 years.^[2,5] Delay in diagnosis is attributed to failure to obtain a detailed remote history for foreign body inhalation, absence of symptoms during aspiration, and absence of any predisposing conditions for inhalation.^[6]

Foreign body aspiration is unusual in adults and is often overlooked as a cause of airway obstruction. Although the condition is often clinically silent, life-threatening hemoptysis may develop. Diagnosis may be difficult because patients may forget previous episodes of aspiration. Radiologic manifestations are nonspecific and include chronic volume loss in the affected lobe, recurrent pneumonias, and bronchiectasis. Rarely, development of a chronic inflammatory reaction around the inhaled material may lead to intrabronchial mass formation. In such cases, a foreign body can be visualized on conventional chest radiographs or CT scans as a centrally located mass with lobar or segmental collapse that must be differentiated from bronchogenic carcinoma.^[1]

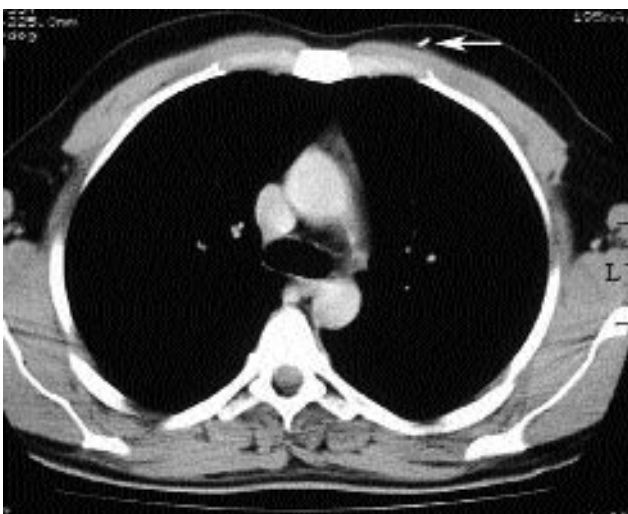


Fig. 2. A chest CT scan showing subcutaneous location of the needle.

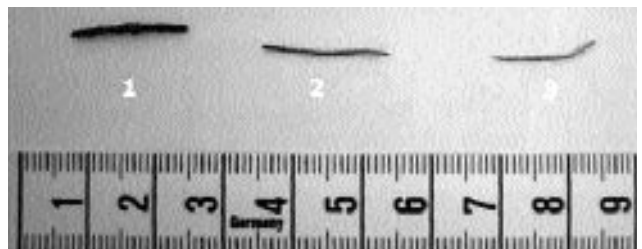


Fig. 3. The needles removed from the right lung (1), from the left lung (2), and from subcutaneous tissue (3).

In adults, the right bronchial system is more likely to be affected by the aspirated foreign bodies. However, this may not be the case in children because the left mainstem bronchus is closer in size to the right one, and it does not branch at the same acute angle as seen in adults.^[4]

In our patient, the needles showed marked corrosion which is an evidence for a long duration of intrapulmonary location. There was no bulbous metallic end on the needles; they might have been broken to prevent reusing.

Aspiration of a needle-like inorganic material was previously reported.^[7] However, we could find only a few reports of aspiration of a syringe needle,^[8] but none remained at an intrapulmonary location for such a long duration. In our opinion, this is the first case of aspirated syringe needles that remained asymptomatic for such a long time until it was incidentally detected.

Acknowledgments. This study was supported in part by the Scientific Research Unit of Akdeniz University.

REFERENCES

1. Franquet T, Gimenez A, Roson N, Torrubia S, Sabate JM, Perez C. Aspiration diseases: findings, pitfalls, and differential diagnosis. *Radiographics* 2000;20:673-85.
2. Limper AH, Prakash UB. Tracheobronchial foreign bodies in adults. *Ann Intern Med* 1990;112:604-9.
3. Chen CH, Lai CL, Tsai TT, Lee YC, Perng RP. Foreign body aspiration into the lower airway in Chinese adults. *Chest* 1997; 112:129-33.
4. Dikensoy O, Usalan C, Filiz A. Foreign body aspiration: clinical utility of flexible bronchoscopy. *Postgrad Med J* 2002; 78:399-403.
5. Henselmans JM, Schramel FM, Sutedja G, Postmus PE. Acute necrotizing pneumonia 16 years after aspiration of a conifer branch. *Respir Med* 1995;89:139-41.
6. al-Majed SA, Ashour M, al-Mobeireek AF, al-Hajjaj MS, Alzeer AH, al-Kattan K. Overlooked inhaled foreign bodies: late sequelae and the likelihood of recovery. *Respir Med* 1997; 91:293-6.
7. Ucan ES, Tahaoglu K, Mogolkoc N, Dereli S, Basozdemir N, Basok O, et al. Turban pin aspiration syndrome: a new form of foreign body aspiration. *Respir Med* 1996;90:427-8.
8. Lacagnina S, Vomero E, Jacobson MJ, Gold AR. Hypodermic needle aspiration in a freebase cocaine abuser. *Chest* 1990; 97:1275-6.