

Surgical correction of reoccurred aortic stump blow-out: a case report

Tekrarlayan aortik güdük kanamasında cerrahi tedavi: Olgu sunumu

Mehmet Adnan Celkan,¹ Bahadır Dağlar,¹ Hakkı Kazaz,¹ Hasan Koçoğlu,² İlyas Başkonuş³

Departments of ¹Cardiovascular Surgery, ²Anesthesiology and Reanimation, ³General Surgery, Medicine Faculty of Gaziantep University, Gaziantep

Aortic stump blow-out occurring secondary to aortoenteric fistula (AEF) is a serious, but fortunately rare situation. We report a successful correction of reoccurred stump blow-out following AEF seen after removal of infected abdominal aortic vascular graft in a patient who had been operated previously for the same complication.

Key words: Aortic graft infection; aortic stump blowout.

Aortic graft infections and complications still remain a serious problem for vascular surgery. Among these complications, aortic stump blowout with secondary to aortoenteric fistula (AEF) is a serious, but fortunately rare situation.^[1-3] This fatal complication is seen most commonly as a delayed complication following aortic reconstruction. Surgery is the major treatment, but despite adequate surgery it has a high mortality rate as 25-90%.^[2,3] In this paper we report a successful correction of reoccurred stump blowout followed by aortic secondary AEF after removal of infected abdominal aortic vascular graft in a patient who had been operated previously because of the same complication.

CASE REPORT

A 45-year-old man was admitted to the emergency room with a 24 h history of abdominal pain and melena. The patient had undergone two operations for aortoiliac occlusive disease in another institution previously. The first operation was aorto-biiliac bypass operation performed eight years ago. Five years later, a re-establishment operation was performed using an aorto-bifemoral Dacron graft. The patient had a laparotomy operation two months ago after a period of high fever and melena, infected bifurcated graft had been removed and an axillo-bifemoral bypass had been established in that operation. The patient suffered from abdominal pain, high fever and melena 7 days after this graft-

Aortoenteric fistüle (AEF) sekonder gelişen aortik güdük kanaması nadir fakat ciddi bir durumdur. Aynı komplikasyon nedeniyle daha önce ameliyat edilen, AEF'ye sekonder abdominal aortik greft enfeksiyonu gelişen hastanın, aortik güdük kanamasının cerrahi olarak düzeltilmesini ve sonucunu sunmayı amaçladık.

Anahtar sözcükler: Aortik greft enfeksiyonu; aortik güdük patlaması.

removal operation. He had been thought to have stump blowout, and was taken to the emergency operation for the correction of stump blowout. In this operation the infected tissue was removed and stump was corrected and tissue was reinforced with a Dacron graft. This was his first blowout correction operation (Fig. 1).

The patient was comatose in admission to our emergency room, his systolic and diastolic arterial blood pressure was 60 and 30 mm Hg respectively. His heart rate and hct level were 125 bpm and 21% respectively. The patient was suspected to have secondary AEF as he has a history of abdominal aortic bypass graft operations and signs of gastrointestinal haemorrhage. After a complete physical examination, esophagogastroduodenoscopy (EGD) was applied to the patient that revealed protruding graft material in the duodenum. After this procedure a contrast-enhanced computed tomography (CT) was performed to assess the duodenum, the perigraft space, and duodenum-graft relationship. Pseudoaneurysm formation, perigraft air and edema were seen in the CT scan together with a patent axillo-bifemoral graft.

After the hemodynamic resuscitation and diagnostic procedures, the patient was operated urgently. A long midline abdominal incision was performed, but unfortunately proximal aortic exploration could not be obtained due to the severe adhesions of the gastrointestinal structures. Left lateral thoraco-abdominal incision was per-

Received: September 30, 2004 *Accepted:* February 5, 2005

Correspondence: Dr. Mehmet Adnan Celkan. Gaziantep Üniversitesi Tıp Fakültesi Kalp ve Damar Cerrahisi Anabilim Dalı, 27310 Gaziantep. Tel: 0342 - 360 25 13 e-mail: celkan@superonline.com

formed later on. Thoracic aorta was explored and clamped. After establishing adequate abdominal aortic exposure, all infected and devitalised tissues were debrided in retro peritoneum and periaortic stump. Infected suture and graft material in the aortic wall was removed completely (Fig. 2). Aorta was closed without tension using a double row of nonabsorbable monofilament sutures. Additionally, aortic stump was reinforced with autolog pericardium. Adherent segment of gastrointestinal tract was dissected carefully. But Aorto-duodenal fistula tract could not be seen. A tube drain was placed and incision was closed according to the anatomical continuation. The daily abdominal bile drainage of about 2500 ml was continued until the postoperative 7th day. On postoperative 7th day, patient's abdominal incision was everted and the intestine was fistulised to the skin in the lower abdominal region. The patient was reoperated for the correction of the fistula. Unfortunately the intestinal fistular tract could not be visualised. After the replacement of the drainage tube the abdomen was closed with Bogato's bag because of the abdominal distension. Two weeks later the patient was operated again because of the excessive intra-abdominal bleeding. This time intestino-cutaneous fistula was visualised and sutured. Unfortunately the correction was incomplete, and four months later fistula was tried to be corrected again in another operation which was unsuccessful again. Three months after this operation the patient was operated once more, and this time the

enteric fistula was corrected successfully, and the abdominal incision was remained to the secondary healing. Six months later the patient was totally healthy, the abdominal incision was healed, axillo-femoral graft was intact, and all peripheral pulses were palpable. By the way, the patient has been operated for seven times within this one year period of time (Fig. 1).

DISCUSSION

Despite the improving results of initial surgical treatment, prosthetic aortic graft infection is frequently associated with reinfection, suture line rupture or anastomotic aneurysm, leading to multiple reoperations, distal amputations and prolonged, even life-long antibiotic treatment.^[4,5] Aortic stump blowout and secondary AEF is one of the rare complications of aortic reconstructive surgery. A high rate of perioperative death and late mortality from the treatment of AEF are two important complications of the aortic stump.^[2,3,6]

Stump blowout occurs between from 10% to 30%, usually occurs within the first few weeks of treatment and often is fatal.^[2,3,6] Adequate debridement of the aortic stump is critically important for a secure and durable closure.

There are various methods of aortic stump reinforcement, including jejunal serosal patch, anterior spinal ligament patch or an omental pedicle.^[7] These techniques may be helpful but have not yet proven ben-

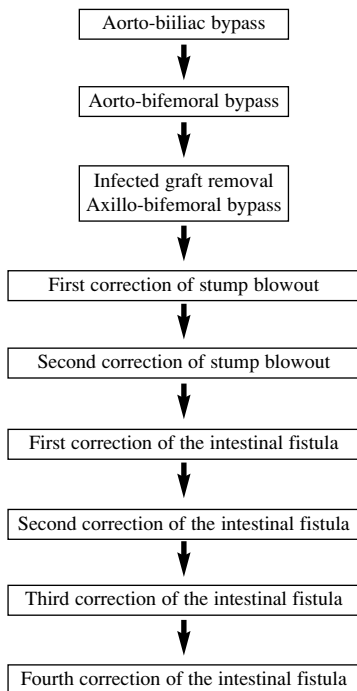


Fig. 1. List of operations that performed to the patient.

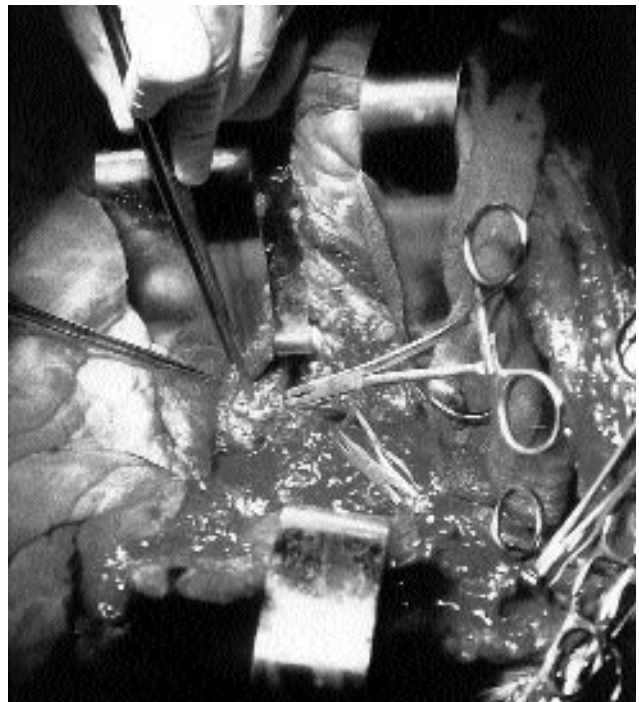


Fig. 2. Infected suture and graft material in the aortic wall.

eficial in reducing the incidence of stump disruption.^[8] Since it may increase, as in our case, the chance of infection and blow-out, the use of prosthetic materials in re-operations is not suitable.

Postoperative care in this type of patients is also very important together with the suitable operations. Correct antibiotherapy, replacement of the lost fluid and electrolytes, total parenteral nutrition, and wound-care are very crucial factors that may have important roles in saving the lives of these patients.

In conclusion, since the rate of the morbidity and mortality of secondary AEF and related complications such as aortic stump blowout is very high, the prevention of these complications should be the main goal. Maximum care should be taken about the sterility in surgical interventions related to the abdominal aorta, and the direct contact of the prosthetic graft with the intestine should be prevented if possible. If secondary AEF occur surgical removal of all infected tissue and graft material is advocated together with a re-establishment of the peripheral circulation.

REFERENCES

1. Montgomery RS, Wilson SE. The surgical management of aortoenteric fistulas. *Surg Clin North [Am]* 1996;76:1147-57.
2. Kuestner LM, Reilly LM, Jicha DL, Ehrenfeld WK, Goldstone J, Stoney RJ. Secondary aortoenteric fistula: contemporary outcome with use of extraanatomic bypass and infected graft excision. *J Vasc Surg* 1995;21:184-95.
3. Menawat SS, Gloviczki P, Serry RD, Cherry KJ Jr, Bower TC, Hallett JW Jr. Management of aortic graft-enteric fistulae. *Eur J Vasc Endovasc Surg* 1997;14 Suppl A:74-81.
4. Ricotta JJ, Faggioli GL, Stella A, Curl GR, Peer R, Upson J, et al. Total excision and extra-anatomic bypass for aortic graft infection. *Am J Surg* 1991;162:145-9.
5. Yeager RA, Moneta GL, Taylor LM Jr, Harris EJ Jr, McConnell DB, Porter JM. Improving survival and limb salvage in patients with aortic graft infection. *Am J Surg* 1990;159:466-9.
6. Busuttill SJ, Goldstone J. Diagnosis and management of aortoenteric fistulas. *Semin Vasc Surg* 2001;14:302-11.
7. Santilli S, Goldstone J. Aortoenteric fistula. In: Yao JST, editor. *Arterial surgery, management of challenging problems*. 1st ed. Stanford: CT, Appleton & Lange; 1996. p. 209-22.
8. Peck JJ, Eidemiller LR. Aortoenteric fistulas. *Arch Surg* 1992;127:1191-3.