

Castleman's disease: a report of two rare cases

Castleman hastalığı: Nadir iki olgu sunumu

Erdal Yekeler,¹ Metin Akgün,² Semra Vural,³ Fazlı Erdoğan⁴

Department of ¹Thoracic Surgery, ³Pathology, Palandöken State Hospital, Erzurum;
Department of ²Chest Diseases, ⁴Pathology, Medicine Faculty of Atatürk University, Erzurum

Castleman's disease is a rare lymphoproliferative disorder, which usually occurs in the chest. The localized form, which is the most common, is often asymptomatic, but can cause nonspecific thoracic symptoms such as cough and dyspnea. Surgical removal is the choice of approach for the management of such cases, in both confirming the diagnosis and curative treatment. A 43-year-old woman who had a history of dry cough for the last six months and a 24-year-old man who had a right anterior chest pain complaint for a year were admitted to our clinic. Thorax computed tomography of cases showed a right hilar well-defined intraparenchymal lesion in the former one and a mass lesion located on the right anterior chest wall in the latter. Surgical intervention was planned in both cases. Histopathological examination of the surgical specimen of both cases revealed hyaline vascular type Castleman's disease. We report two unusual thoracic manifestations of Castleman's disease with chest wall and intraparenchymal location, the latter of which is extremely rare.

Key words: Castleman's disease; intraparenchymal; surgical excision.

Castleman's disease, which is also referred to as giant lymph node hyperplasia, angiofollicular lymph node hyperplasia, lymph node hamartoma, or benign lymph node lymphoma, is a rare disease with two identified forms as localized and multicentric. It was first described by Castleman in 1956.^[1] The disease may occur anywhere along the lymphatic chain but it is most commonly found as a solitary mass in the mediastinum.^[2]

Herein are reported two unusual thoracic locations of Castleman's disease of hyaline vascular type that were surgically removed.

CASE REPORT

Case 1– A 43-year-old woman was admitted with a history of dry cough for the last six months. The findings

Castleman hastalığı, genellikle göğüs boşluğunda görülen, lenf nodu proliferasyonu ile seyreden nadir bir hastalıktır. Yerleşik formu çok daha sık görülür ve sıklıkla semptom vermez, fakat dispne ve öksürük gibi nonspesifik torasik semptomlara neden olabilir. Hem kesin tanı hem de küratif tedavi için cerrahi, seçilecek iyi bir yaklaşımdır. Son altı aydır kuru öksürüğü olan 43 yaşında bayan hastanın ve son bir yıldır sağ göğüs ağrısı olan 24 yaşında erkek hastanın çekilen göğüs tomografilerinde; ilk olguda sağ hilusta parenkim içinde, ikinci olguda ise sağ göğüs ön duvarında düzgün sınırlı, kitle lezyon tespit edildi. Her iki olguda da cerrahi planlandı ve ameliyat sonrası histopatolojik değerlendirmede her ikisi de, hiyalin vasküler tip Castleman hastalığı olarak raporlandı. Bu makalede, Castleman hastalığının çok nadir görülen, parenkim içi ve göğüs duvarı olmak üzere iki intratorasik yerleşimi sunuldu. Bunlardan parenkim yerleşimli olan tipi son derece nadir görülür.

Anahtar sözcükler: Castleman hastalığı; parenkim içi; cerrahi çıkarma.

in the physical exam, her medical history and the laboratory values were unremarkable. The chest X-ray showed a well-defined lesion located in the right hilum (Fig. 1a). The bronchoscopic examination findings were within normal limits. The computed tomography (CT) of the thorax showed a well-defined intraparenchymal lesion on the right side (Fig. 1c). The patient underwent a right thoracotomy. The lesion, which was surrounding the middle lobe artery and extending from the lower lobe parenchyma into the fissure between the middle and the lower lobes, was totally removed. Peroperatively, the lesion was observed to be well-circumscribed and capsulated with increased vascularity and of benign nature. The histopathological examination of the surgical specimen revealed a hyaline vascular type of Castleman's Disease (Fig. 2a).

Received: June 5, 2007 Accepted: July 30, 2007

Correspondence: Erdal Yekeler, M.D. Osmangazi Mah., 230. Sok., Taner Apt., B-Blok, No: 4, 25070 Yıldızkent, Palandöken, Erzurum, Turkey.
Tel: +90 442 - 232 55 55 e-mail: drerdalyekeler@hotmail.com

Case 2– A 24-year-old man was admitted with the complaint of chest pain on the anterior right side for one year. The findings in the physical exam, his medical history and the laboratory values were unremarkable. A CT of the thorax obtained after determining a hilar mass in the chest X-ray (Fig. 1b), showed a massive lesion located on the anterior right chest wall (Fig. 1d). The transthoracic needle aspiration biopsy of the lesion was nondiagnostic. Thus, a surgical intervention was planned. A right thoracotomy was done and the lesion, which was located at the level of the right fourth and fifth ribs, corresponding to the course of the internal thoracic artery, was totally removed (Fig. 2b). The lesion was highly vascular, well-circumscribed and capsulated. The histopathological examination of the surgical specimen also revealed a hyaline vascular type of Castleman’s disease.

DISCUSSION

Castleman’s disease constitutes a clinicopathologic entity represented by a lymph node hypertrophy and is

histologically characterized by angiofollicular lymph-node hypertrophy. Two clinical forms of the disease are known. The first one is a localized form, in which the disease is restricted to one lymph node and the second one is a multicentric or systemic form, in which several sites are involved. Three histological variants have been described: (i) the hyaline vascular, (ii) the plasma cell and (iii) a mixed type.^[3-5] The most common presentation is the localized form and its hyaline vascular type accounts for approximately 90% of the cases.^[6]

Although the majority of the cases occur within the chest, along the tracheobronchial tree in the mediastinum or the lung hilus, it has also been reported in other places such as the neck, pelvis, and abdomen.^[2-4,7] The disease may also, however rarely, be observed in other places than these, as in our cases above. In the literature, according to our best knowledge, there are few reports on chest wall involvement,^[8] while the reports on intrafissural development^[9] and intraparenchymal localization are extremely rare.^[10]

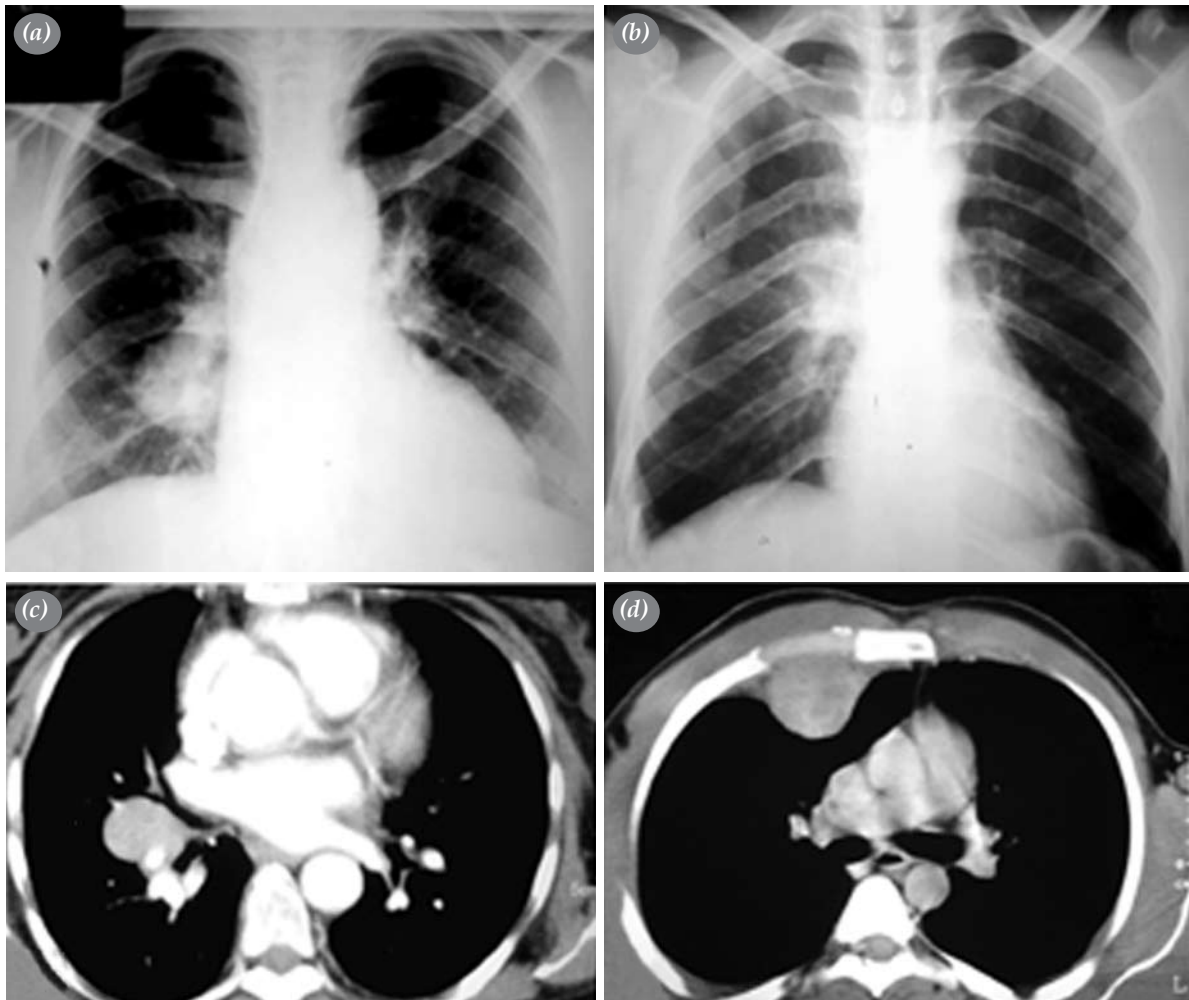


Fig. 1. (a, b) Chest X-rays showed hilar density and (c) Thorax computed tomographies revealed a well-circumscribed, solid mass lesion in pulmonary parenchyma and (d) the chest wall.

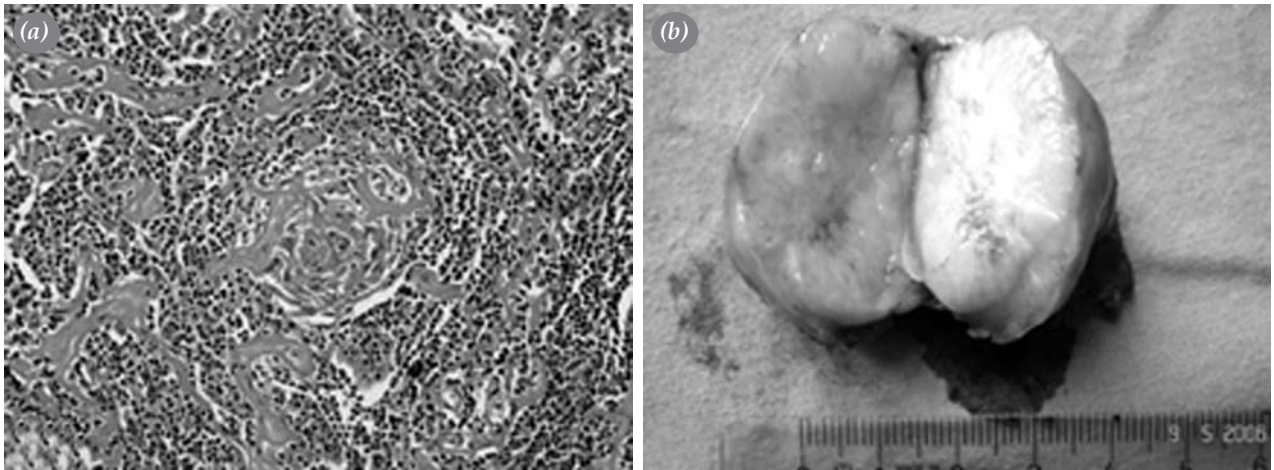


Fig. 2. (a) Histopathological examination revealed Castleman's disease, hyaline vascular type. A hyaline vascular follicle is shown. The mantle zone lymphocytes lie in a concentric ring (so-called onionskin pattern) around the reactive germinal center. There is a proliferation of small blood vessels. **(b)** Macroscopic view, mostly gray and white colored. Highly vascular and well margined solid mass belonging to case 2.

The clinical manifestation of Castleman's disease is highly dependent on the histopathology of the lesion. Castleman's disease can occur at any age, even during the childhood, with a peak frequency during adulthood. There is no sex predilection or identifiable risk factors in the development of the disease.^[2] The tumor is often diagnosed after the onset of nonspecific thoracic symptoms such as coughing, dyspnea, and chest pain caused by tracheobronchial compression, but it can also be incidentally diagnosed in asymptomatic cases. Although the multicentric form is always symptomatic, the localized form is usually asymptomatic. However, cases with localized forms may have some nonspecific complaints such as asthenia, fever and weight loss.^[2,11] Our patients, who had the localized form, also had thoracic symptoms, dry cough, and chest pain at their admission.

The most commonly detected radiological appearance of the localized form, including the chest wall involvement, is a homogenous, well-margined mass with high vascularity.^[6,8] Pleural effusion may be observed. Calcification may sometimes be determined in some cases and it may indicate chronic disease.^[12]

The diagnosis of Castleman's disease is ultimately made by histology, thereby requiring either the removal or a biopsy of the lesion for definitive diagnosis. However, preoperative aspiration biopsy may fail to achieve a positive diagnosis as was shown by previously reported cases^[8] and our second case. In addition, a needle biopsy may not be feasible and it can even be dangerous because of the high vascularization of the tumor, which increases the risk of bleeding. Therefore, such cases may ultimately require surgical exploration.

In contrast to the multicentric form, in which the disease has a more aggressive course with a poorer prognosis and the management of the cases is still problematic, the localized forms are mostly suitable for surgery and have a better prognosis if they are fully resectable wherever they are located.

In conclusion, two unusual thoracic (chest wall and intraparenchymal) manifestations of localized Castleman's disease, of which the latter is extremely rare, have been presented in our report. Although it is rare, Castleman's disease should be considered in the presence of masses that correspond to any lymphatic chain in the differential diagnosis. Preoperative biopsy may be nondiagnostic and it may cause bleeding due to the high vascularization of the lesions. In such cases, surgery seems to be the best option for the confirmation of the diagnosis and the management of the disease.

REFERENCES

1. Castleman B, Iverson L, Menendez VP. Localized mediastinal lymphnode hyperplasia resembling thymoma. *Cancer* 1956;9:822-30.
2. Keller AR, Hochholzer L, Castleman B. Hyaline-vascular and plasma-cell types of giant lymph node hyperplasia of the mediastinum and other locations. *Cancer* 1972;29:670-83.
3. Gökçe M, Okur E, Baysungur V, Yılmaz A, Halezaroğlu S. Castleman hastalığı: 3 olgu nedeniyle. *Türkiye Klinikleri Arch Lung* 2006;7:72-4.
4. Can D, Demir E, Tanaç R, Gülen F, Yenigün A, Soydan S, et al. Localized castleman disease associated with bronchiectasis. *Turkish Respiratory Journal* 2005;6:46-9.
5. Barrie JR, English JC, Müller N. Castleman's disease of the lung: radiographic, high-resolution CT, and pathologic findings. *AJR Am J Roentgenol* 1996;166:1055-6.

6. Frizzera G. Castleman's disease and related disorders. *Semin Diagn Pathol* 1988;5:346-64.
7. İnci E, Mamak A, Dereköylü L, Güvenç MG, Cansız H, Akı H. Hyalen vasküler castleman hastalığı: olgu sunumu. *Türk Otolarengoloji Arşivi* 2003;41:158-61.
8. Rena O, Casadio C, Maggi G. Castleman's disease: unusual intrathoracic localization. *Eur J Cardiothorac Surg* 2001; 19:519-21.
9. Caus T, Leude E, Thomas P, Garbe L, Giudicelli R, Fuentes P. Castleman's disease. An intrapulmonary isolated form with fissural exteriorization. *Presse Med* 1992;21:934-6. [Abstract]
10. Spedini C, Lombardi C, Lanzani G, Di Fabio D, Chiodera PL. Castleman's disease presenting as an asymptomatic solitary pulmonary nodule. *Monaldi Arch Chest Dis* 1995;50:363-5.
11. Herrada J, Cabanillas F, Rice L, Manning J, Pugh W. The clinical behavior of localized and multicentric Castleman disease. *Ann Intern Med* 1998;128:657-62.
12. Mikroulis D, Tsakiridis K, Kaloutsi V, Didilis V. Mediastinal Castleman disease with calcific deposits. *Eur J Cardiothorac Surg* 2004;25:135-6.