

The effects of chlorhexidine gluconate and silver nitrate on rabbit lung: an experimental study

*Klorhekzidin glukonat ve gümüş nitratin tavşan akciğeri üzerindeki etkileri:
Deneysel bir çalışma*

**Ekber Şahin,¹ Şahande Elagöz,² Burçin Çelik,¹ Aydın Nadir,¹ Şule Karadayı,³ Yücel Akkaş,¹
Melih Kaptanoğlu,¹ Şinasi Manduz⁴**

Departments of ¹Thoracic Surgery, ²Pathology, ³Emergency, ⁴Cardiovascular Surgery,
Medicine Faculty of Cumhuriyet University, Sivas

Background: In this study, we investigated the effects of chlorhexidine gluconate and silver nitrate on the lungs and determine their utility in operations for pulmonary hydatid cysts.

Methods: Thirty New Zealand Wistar albino rabbits weighing between 2750 and 3000 grams were used in the study and divided into three groups. In the first (control) group, normal saline (0.09% NaCl); in the second group, silver nitrate (0.5%); and in the third group, chlorhexidine gluconate (0.04%) was administered intrathoracically. Thirty days after the procedure, the tracheobronchial and parenchymal changes in the subjects were evaluated histopathologically. Tracheobronchial changes were evaluated with respect to tracheal pathology whereas peribronchial lymphocytic infiltration and parenchymal changes were evaluated with respect to interstitial lymphocytic infiltration, hemorrhage-edema, fibrosis and pneumonitis.

Results: The rate of interstitial lymphocytic infiltration was higher in the chlorhexidine gluconate group than in the control group, and the rates of fibrosis and fibrin accumulation were higher in the silver nitrate group than in the control group. No statistically significant differences in other parameters were found between the groups.

Conclusion: The results of the study indicate that chlorhexidine gluconate (0.04%) has minimal negative effects on the rabbit lung and tracheobronchial mucosa and is a more reliable agent than silver nitrate.

Key words: Chlorhexidine gluconate; hydatid cyst; pulmonary; silver nitrate.

Amaç: Bu çalışmada klorhekzidin glukonat ve gümüş nitratin akciğerler üzerine olan etkisi incelendi ve akciğer kist hidatik ameliyatlarında kullanılabilirliği değerlendirildi.

Çalışma planı: Çalışmada ağırlıkları 2750 ile 3000 gram arasında değişen otuz sağlıklı Wistar albino Yeni Zelanda tavşanı kullanıldı ve tavşanlar üç gruba ayrıldı. Birinci grupta serum fizyolojik, ikinci grupta %0.5'lik gümüş nitrat ve üçüncü grupta %0.04'lük klorhekzidin glukonat trakea yoluyla verildi. İşlemden 30 gün sonra tavşanlardaki trakeobronşiyal ve parenkimal değişiklikler histopatolojik olarak incelendi. Trakeobronşiyal değişiklikler trakeal patolojiye göre değerlendirildi, oysa peribronşiyal lenfositik infiltrasyon ve parenkimal değişiklikler ise interstisyel lenfositik infiltrasyon, kanama-ödem, fibrozis ve pnömoni açısından değerlendirildi.

Bulgular: İnterstisyel lenfositik infiltrasyon oranı klorhekzidin glukonat grubunda kontrol grubuna göre daha yüksek iken, fibrozis ve fibrin birikimi gümüş nitrat grubunda kontrol grubuna göre daha yüksekti. Gruplar arasında diğer parametrelerde istatistiksel açıdan anlamlı farklılık bulunmadı.

Sonuç: Çalışmanın sonuçları ile %0.04'lük klorhekzidin glukonatın tavşan akciğeri ve trakeobronşiyal mukoza üzerine minimal negatif bir etkisinin olduğu ve gümüş nitrata göre daha güvenilir bir ajan olduğu gösterilmiştir.

Anahtar sözcükler: Klorhekzidin glukonat; kist hidatik; akciğer; gümüş nitrat.

Received: March 2, 2010 Accepted: June 3, 2010

Correspondence: Burçin Çelik, M.D. Ondokuz Mayıs Üniversitesi Tıp Fakültesi Göğüs Cerrahisi Anabilim Dalı, 55139 Samsun, Turkey.
Tel: +90 362 - 312 19 19 / 2701 e-mail: cburcin@hotmail.com

Presented at the 5th Annual Congress of Turkish Thoracic Surgery, May 17-20, 2009 Kuşadası, Aydın, Turkey and awarded with best poster presentation.

Surgery for pulmonary hydatid cyst includes cystotomy, cystotomy + capitonnage, and enucleation in selected cases. The most dreaded complication during surgery is contamination of the thoracic cavity and bronchial system by the cyst.^[1] To prevent thoracic contamination, many surgeons prefer to use agents such as hypertonic saline solution, silver nitrate (SN), betadine as well as scolicidal agents intraoperatively.^[2,3] However, no consensus has been established to date as to the choice of scolicidal agent, its duration of efficacy, and best concentration for use.^[4,5]

Recently, chlorhexidine gluconate (Chx-Glu) has been a common preference in general surgery procedures, and its efficiency has been proven.^[6,7] It has been reported to be safe in surgery for intraabdominal and/or liver hydatid cysts, while it has not been used in surgery for pulmonary hydatid cysts. However, before its use in such operations, it must be ensured that this agent does not impair the lungs and/or bronchial parenchyma.

This experimental study was initially planned to determine the effects of Chx-Glu on rabbit lungs. Silver nitrate, another agent of frequent use was also tested in the study and thus, the study aimed to determine the effects of silver nitrate (AgNO₃) and Chx-Glu administered to the tracheobronchial system, on the lungs and bronchi of the rabbits.

MATERIALS AND METHODS

Permission to conduct the study was obtained from the Ethics Committee of the University before the study was initiated (Date/number: 16.02.2006/71). The study was performed on 30 New Zealand Wistar albino rabbits with a mean weight of 2750-3000 grams. To investigate statistical differences, three groups of rabbits were formed with 10 rabbits in each. In the first (control) group normal saline (0.09%); in the second group, AgNO₃ (0.5%), and in the third group, 0.2 ml Chx-Glu (0.04%) was administered.

Before the administration of agents, each animal was anaesthetized with xylazine 10 mg/kg and ketamine HC 20-30 mg/kg intramuscular (im.). Then, a 1 cm vertical incision was performed. The muscles were retracted by blunt dissection, and the cervical trachea was reached. Using an insulin injector, air was aspirated between the tracheal rings and 0.2 ml of the agent was injected. Finally, the muscles and the skin were sutured en-bloc (Fig. 1). After the procedure, 2.2 mg/kg of carprofen were given daily for three days as analgesic.

The rabbits were sacrificed with 200 mg/kg pentothal administration 30 days after the procedure. Samples from the animals were obtained and were embedded into 10% formaldehyde. The sampling was taken from

three different segments of the distal trachea and pulmonary parenchyma of each animal. For histopathological evaluation, the paraffin blocks of the samples were sliced into sections of 4- μ m thickness, and the sections were stained with hematoxylin-eosin. Parenchymal changes (Hemorrhage-edema, interstitial lymphocytic infiltration, pneumonitis, fibrin accumulation and fibrosis) were semi-quantitatively evaluated between + and +++ (mild +, moderate ++, severe +++); tracheobronchial epithelial and tracheobronchial changes (Peribronchial lymphocytic infiltration) were evaluated as 1 follicle +, 2 follicles ++, 3 and more follicles +++ (Fig. 2) by a pathologist (Table 1). To determine the rate of fibrosis in the parenchyma, Mason's trichrome was used to stain the samples and the avidin-biotin peroxidase method was applied to tracheal biopsy specimens.

Statistical analysis

Statistical Package for Social Sciences (SPSS) for Windows 15.0 version (SPSS, Chicago, Illinois, USA) was used for statistical evaluation. The data were evaluated using Chi-square, Fisher's exact and Kruskal-Wallis tests. The data were expressed as the mean \pm standard deviation. The value $p < 0.05$ was considered to be significant.

RESULTS

There was no statistically significant histological difference in tracheobronchial tissues of two groups. The p value for peribronchial lymphocytic infiltration was 0.621, it was 0.05 for epithelial pathology (Table 1, Fig. 2).

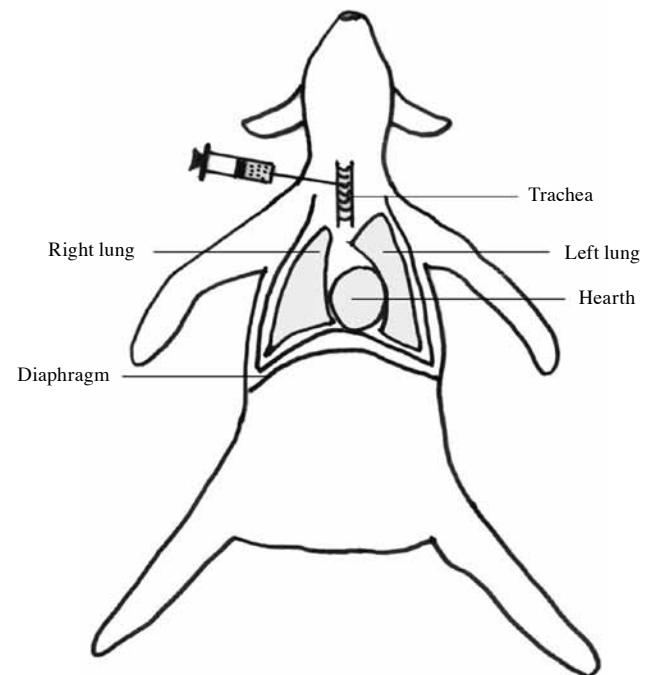


Fig. 1. Intratracheal application of scolicidal agents, schematic view.

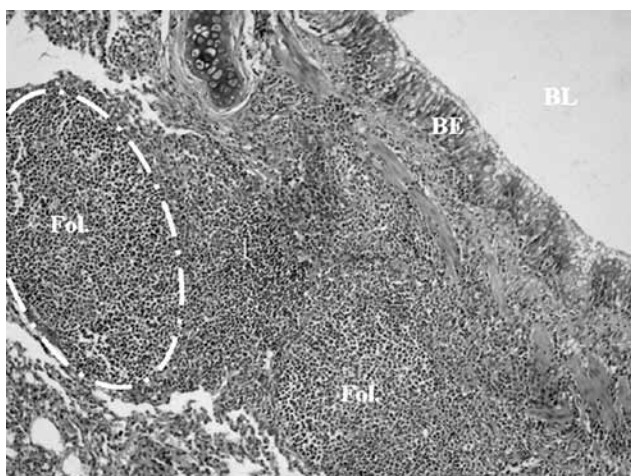


Fig. 2. Ciliary tracheobronchial epithelium on the surface, subepithelial hyalen cartilage, muscle fibers and follicle generated (moderate intense) lymphocytes infiltration showed (H-E x 20). BL: Bronchial Lumen, BE: Bronchial Epithelium, Fol: Follicule.

Evaluation of parenchymal alterations for hemorrhage-edema revealed no statistically significant differences between the groups, although hemorrhage-edema was more common in the AgNO₃ and Chx-Glu groups than it was in the control group. The difference for interstitial lymphocytic infiltration between the groups was statistically significant. The Chx-Glu group was affected more than the control group ($p=0.038$), while the difference between the AgNO₃ group and the control group was not statistically significant (Table 2, Fig. 3).

The difference in the rate of pneumonitis between the groups was not statistically significant, while there was a higher rate of positivity for pneumonitis in the AgNO₃ and Chx-Glu groups. For fibrin accumulation, there was a statistically significant difference between the groups. While the AgNO₃ group was affected more than the control group ($p=0.039$), the difference between the control and Chx-Glu groups was not statistically significant (Fig. 4). The AgNO₃ group had a higher rate of fibrosis than the control group ($p=0.033$); however, the rates of fibrosis in the Chx-Glu and control groups were not statistically significantly different.

DISCUSSION

Hydatid disease continues to be an important endemic problem in many parts of Turkey. The mainstay of treatment for hydatid disease is surgery, but it carries the risk of intraoperative spillage of scolices. Uncontrolled spillage of cyst contents may cause secondary pleural or parenchymal hydatidosis in pulmonary hydatid disease. Numerous scolicedal agents have been used for many years and hypertonic saline is the most frequently used scolicedal agent in Turkey. As complication, hypertonic saline solution may cause hypernatremia. Betadine (10% povidone iodine) is a disinfectant that is used as a scolicedal agent by many surgeons but polyvinylpyrrolidone-iodine can cause renal failure, sterile peritonitis and sclerosing serositis. Its use is restricted to preoperative local antiseptics of intact skin.^[4,7,8]

Chx-Glu is an antiseptic agent with a broad spectrum of activity against gram-positive and gram-negative bacteria and fungi.^[11,6] Recent studies have reported successful results on the use of Chx-Glu as a scolicedal agent in the surgery for intraabdominal hydatid cyst. In one study, Chx-Glu at a concentration of 0.04% was shown to kill all of the protoscolices in five minutes.^[6,7] Use of such a potent agent may reduce recurrence rates of pulmonary hydatid cysts. However, the literature reveals few studies on this issue. Thus the effects of Chx-Glu on the lungs are not clearly known.^[9] This study aimed to determine the efficacy of the use of Chx-Glu in thoracic surgery procedures. In the study, the effects of Chx-Glu on the lungs were studied. Additionally, AgNO₃, an agent of frequent use in thoracic surgery, was studied of which its effects on the lungs are not clearly known.

Orito et al,^[9] in a preliminary study administering Chx-Glu directly into the trachea, observed cyanosis and dyspnea developing in the animals. Although they claimed injecting the agent into the left main bronchus only, the small bronchial structures of rats and administration of the agent at high concentrations may have caused the cyanosis and dyspnea. Neither cyanosis nor dyspnea were observed after the injection of the chemical agents in our study.

Table 1. Histopathological results of tracheobronchial alterations

	Tracheobronchial epithelial tissue		Tracheobronchial alterations									
			Peribronchial lymphocytic infiltration									
	Normal	Pathologic	Normal	1 Follicule		2 Follicules		3 and >3 Follicules				
n	%	n	%	n	%	n	%	n	%			
Group 1 (n=10)	9	90	1	10	6	60	3	30	1	10	0	0
Group 2 (n=10)	8	80	2	20	4	40	1	10	2	20	3	30
Group 3 (n=10)	8	80	2	20	7	70	0	0	2	20	1	10
<i>p</i>		0.05							0.621			

Table 2. Histopathological results of parenchymal alterations

	Parenchymal alterations																			
	Hemorrhage-edema				Interstitial lymphocytic infiltration				Pneumonitis				Fibrin accumulation				Fibrosis			
	Abs.	Mild	Mod.	Sev.	Abs.	Mild	Mod.	Sev.	Abs.	Mild	Mod.	Sev.	Abs.	Mild	Mod.	Sev.	Abs.	Mild	Mod.	Sev.
	n/%				n/%				n/%				n/%				n/%			
Group 1 (n=10)	8/80	2/20	-	-	7/70	3/30	-	-	10/100	-	-	-	10/100	-	-	-	10/100	-	-	-
Group 2 (n=10)	7/70	3/30	-	-	5/50	3/30	2/20	-	7/70	3/30	-	-	5/50	5/50	-	-	5/50	5/50	-	-
Group 3 (n=10)	7/70	3/30	-	-	3/30	6/60	1/10	-	8/80	2/20	-	-	7/70	3/30	-	-	9/90	1/10	-	-
<i>p</i>	>0.05				0.038*				>0.05				0.039**				0.033**			

*: Significant difference between group 3 and group 1; **: Significant difference between group 2 and group 1; Abs: Absent; Mod: Moderate; Sev: Severe.

In our study, Chx-Glu was used at a concentration of 0.04%, two and a half times the minimum concentration used in the study by Orito et al.^[9] The pathological evaluation of the specimens showed that the group that was administered Chx-Glu significantly differed from the control group only for interstitial lymphocytic infiltration. Similar to our findings, in the study by Orito et al.^[9] the group that was injected with Chx-Glu at a concentration of 0.01% showed mild congestion, while the groups that received Chx-Glu at concentrations of 0.1% and 1% showed moderate and severe intraalveolar hemorrhage and congestion. In a case reported by Hirata and Kurokawa,^[10] accidental oral intake of 5% Chx-Glu resulted in development of acute respiratory distress syndrome (ARDS) and death of the patient. This indicates the importance of dose adjustment. In our study, the Chx-Glu group did not significantly differ from the control group for fibrosis, pneumonitis, and fibrin accumulation. In the light of these findings, it was thought

that at a concentration of 0.04%, Chx-Glu did not cause a significant damage in the lungs suggesting ARDS.

In the AgNO₃ group, the rates of fibrosis development and fibrin accumulation were significantly higher than those of the control group. The rates of intraalveolar hemorrhage in both groups were also higher than those of the control group. However, the differences were not statistically significant. In the light of these results, it can be said that Chx-Glu is less toxic than AgNO₃.

Recurrence is still one of the major problems in pulmonary hydatid cyst.^[11] To minimize the rate of the recurrence, there are ongoing investigations for ideal scolicidal agents. Despite several studies on this issue, the concentrations used in some of these studies, and the time and degree of their efficiency are provided in table 3.^[4,6,7,12,13] Table 3 shows that, Chx-Glu has been found to be the most effective scolicidal agent. Surgeons frequently start the procedure upon injection of the scolicidal agent into the cyst before the scolicidal agent shows its full effect. This reduces the efficiency of the

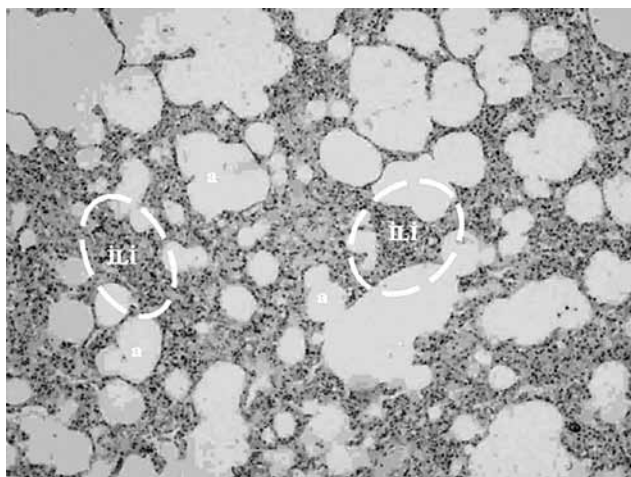


Fig. 3. Lymphocytic infiltration at interstitial zone in lung parenchyma, fibrin, hemorrhage and mild intense lymphocytic infiltration around bronchiole (H-E x 20). ILI: Interstitial lymphocytic infiltration; a: Alveoli.

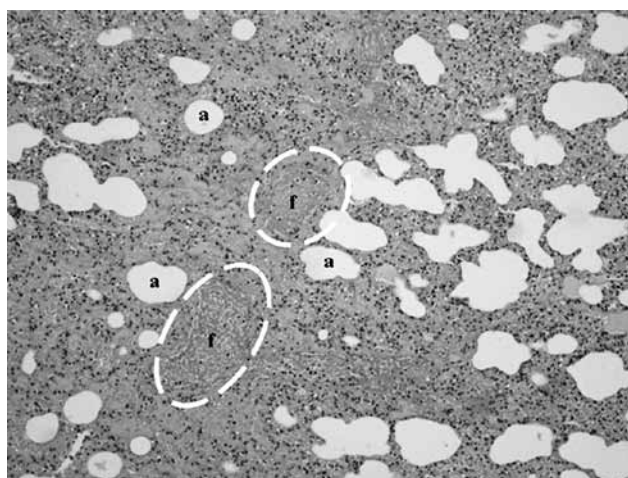


Fig. 4. Wide fibrin mass, leucocytes and nuclear remnants at interstitium showed (H-E x 40). f: Follicule; a: Alveoli.

Table 3. Studies with scolicedal agents in terms of efficiency and duration

	Active substance	Concentration (%)	Duration (minute)	Efficiency (%)
Puryan et al. ^[6]	Chlorhexidine gluconate	0.04	5	100
Hosseini et al. ^[13]	Silver nitrate	0.5	5	93.8
	Glucose	50	5	97.3
Çiftçi et al. ^[4]	Povidone iodine	10	15	100
	Octenidine dihydrochloride	0.1	15	100
Çağlar et al. ^[12]	Hypertonic saline	20	45	100
Topçu et al. ^[7]	Chlorhexidine gluconate	0.04	5	100

agent used. Considering these, an agent of full efficacy that would act in a relatively shorter time will obviously reduce operating time as well as recurrence rates.

In conclusion, our results have shown that at a concentration of 0.04%, Chx-Glu is less toxic than AgNO₃ on the lungs, which is negligible. Lower toxicity and higher availability of Chx-Glu compared to other scolicedal agents are its important advantages. Even at low concentrations, it acts in a shorter time with full efficacy and is a safe scolicedal agent as previously reported. Thus, we believe Chx-Glu may be used to reduce the recurrence rates of pulmonary hydatid cysts.

Acknowledgement

We thank to Ziyet Çınar (Assistant Professor in Cumhuriyet University, Medical School, Department of Biostatistics, Sivas, Turkey) for statistical analysis.

Declaration of conflicting interests

The authors declared no conflicts of interest with respect to the authorship and/or publication of this article.

Funding

This work was supported by the Cumhuriyet University Scientific Research Foundation (CUBAP T-321).

REFERENCES

- Topcu O, Kuzu I, Karayalcin K. Effects of peritoneal lavage with scolicedal agents on survival and adhesion formation in rats. *World J Surg* 2006;30:127-33.
- Sahin E, Enön S, Cangir AK, Kutlay H, Kavukçu S, Akay H, et al. Single-stage transthoracic approach for right lung and liver hydatid disease. *J Thorac Cardiovasc Surg* 2003;126:769-73.
- Tor M, Atasalihi A, Altuntas N, Sulu E, Senol T, Kir A, et al. Review of cases with cystic hydatid lung disease in a tertiary referral hospital located in an endemic region: a 10 years' experience. *Respiration* 2000;67:539-42.
- Ciftci IH, Esmé H, Sahin DA, Solak O, Sezer M, Dilek ON. Effect of octenidine dihydrochloride on viability of proto-scolecetes in hepatic and pulmonary hydatid diseases. *J Natl Med Assoc* 2007;99:674-7.
- Nadir A, Kaptanoglu M. Surgical management of pulmonary hydatidosis. *ANZ J Surg* 2007;77:800-1.
- Puryan K, Karadayi K, Topcu O, Canbay E, Sumer Z, Turan M, et al. Chlorhexidine gluconate: an ideal scolicedal agent in the treatment of intraperitoneal hydatidosis? *World J Surg* 2005;29:227-30.
- Topcu O, Sumer Z, Tuncer E, Aydin C, Koyuncu A. Efficacy of chlorhexidine gluconate during surgery for hydatid cyst. *World J Surg* 2009;33:1274-80.
- Topcu O, Kuzu I, Karayalcin K. Effects of peritoneal lavage with scolicedal agents on survival and adhesion formation in rats. *World J Surg* 2006;30:127-33.
- Orito K, Hashida M, Hirata K, Kurokawa A, Shirai M, Akahori F. Effects of single intratracheal exposure to chlorhexidine gluconate on the rat lung. *Drug Chem Toxicol* 2006;29:1-9.
- Hirata K, Kurokawa A. Chlorhexidine gluconate ingestion resulting in fatal respiratory distress syndrome. *Vet Hum Toxicol* 2002;44:89-91.
- Kayaalp C, Balkan M, Aydin C, Ozgurtas T, Tanyuksel M, Kirimlioglu V, et al. Hypertonic saline in hydatid disease. *World J Surg* 2001;25:975-9.
- Çağlar R, Yuzbasioglu MF, Bulbuloglu E, Gul M, Ezberci F, Kale IT. In vitro effectiveness of different chemical agents on scolices of hydatid cyst. *J Invest Surg* 2008;21:71-5.
- Hosseini SV, Ghanbarzadeh K, Barzin J, Sadjjadi SM, Tanideh N, Mehrabani D. In vitro protoscolicedal effects of hypertonic glucose on protoscolices of hydatid cyst. *Korean J Parasitol* 2006;44:239-42.