

Evaluation of the efficacy of ductus arteriosus stenting in neonates and infants with severe cyanosis until the later stage palliative surgery or total repair time

Ağır siyanoze yeni doğan ve süt çocuklarında duktus arteriozusa stent takılmasının ileri aşama palyatif cerrahi veya total tamir süresine kadar olan dönemdeki etkinliğinin değerlendirilmesi

Abdullah Erdem,¹ Ali Rıza Karacı,² Turkey Sarıtaş,¹ Celal Akdeniz,¹ Halil Demir,¹ Ahmet Şaşmazel,² Ahmet Çelebi¹

Departments of ¹Pediatric Cardiology, ²Cardiovascular Surgery
Siyami Ersek Training and Research Hospital, İstanbul

Background: In this study, we aimed to assess the efficacy and outcome of transcatheter ductus arteriosus stenting in newborns and infants with ductal-dependent or decreased pulmonary circulation.

Methods: Between July 2004 and January 2009, 45 patients with ductus-dependent or decreased pulmonary circulation underwent cardiac catheterization for stent implantation. Forty-seven stents in total were implanted in 42 (93.3%) of these 45 patients. The mean age at the time of the procedure was 66 days (3 days to 1.8 years) and mean weight was 4.4±2.1 kg (2-13.2). Premounted coronary stents of 3, 3.5, and 4 mm in diameter were used to cover the whole length of the ductus.

Results: The stenting procedure was successfully completed in all 42 patients. There was no procedure related death. The mean ductal length was 13.2±3.8 mm (7.8-23) and the mean stent length was 13.9±3.8 mm (8-23). Mean arterial oxygen saturation before stent implantation was 66.0% ±8.1 (42-75) and increased to 85.7%±4.2 (75-95) after stenting. During a mean follow-up of 34.5±14.4 months (12-54), there was a significant reduction in pulse oxygen saturation six months after the procedure (78.8%±8.5; p<0.05). Control cardiac catheterization was performed in 25 (59%) patients at a mean of 8.1 months (2-18) after the initial implantation. Twelve patients (28%) underwent a successful redilatation of the stent with an increase in mean oxygen saturation of 13%±3.6 (8-20). Fourteen of 42 patients have undergone successful biventricular repair and bidirectional cavopulmonary shunt (Glenn operation) was performed in 16. Four patients underwent elective unifocalization of the pulmonary arteries and modified Blalock-Taussig shunt. Of the patients undergoing Glenn operation or total repair surgery, 12 (40%) patients had pulmonary arterioplasty. Four patients were totally cured after stent implantation of the ductus combined with valvotomy and/or valvuloplasty. The remaining four patients died on follow-up.

Conclusion: Stent implantation of ductus arteriosus can be a good alternative to surgery for initial palliation in severely cyanotic newborns and infants until the latter stage palliative surgery or total repair. It is safe and feasible however its efficacy gradually reduces after six months. In selected patients like critical pulmonary stenosis or pulmonary atresia-intact ventricular septum with favorable anatomy it may provide a definitive cure.

Key words: Cyanotic infants and newborn; ductal stenting; surgery.

Amaç: Bu çalışmada duktusa bağımlı veya azalmış pulmoner kan akımı olan yenidoğanlarda ve süt çocuklarında transkateter duktus arteriozusa stentlemenin etkinliği ve sonuçları araştırıldı.

Çalışma planı: Temmuz 2004 - Ocak 2009 tarihleri arasında duktusa bağımlı ya da azalmış pulmoner kan akımı olan 45 hasta transkateter stent takılması amacıyla kardiyak kateterizasyon işlemine alındı. Bu 45 hastanın 42'sine (%93.3) toplam 47 adet stent yerleştirildi. İşlem sırasında olguların yaş ortalaması 66 gün (3 günlük-1.8 yıl), ağırlık ortalaması 4.4±2.1 kg (2-13.2) idi. Bu işlem için duktusun tüm uzunluğunu kaplamak üzere 3, 3.5 ve 4 mm'lik çaptaki önceden balona yüklenmiş koroner stentler kullanıldı.

Bulgular: Kırk iki hastanın tümünde stent yerleştirme işlemi başarıyla tamamlandı. İşleme bağlı ölüm olmadı. Ortalama duktus uzunluğu 13.2±3.8 mm (7.8-23), ortalama stent uzunluğu ise 13.9±3.8 mm (8-23) idi. Stent yerleştirmeden önceki ortalama arteriyel oksijen saturasyonu %66±8.1 (42-75) idi ve stent sonrasında %85.7±4.2'ye (75-95) yükseldi. Ortalama 34.5±14.4 aylık izlem (12-54) sırasında işlemten altı ay sonra oksijen saturasyonunda anlamlı bir azalma saptandı (%78.8±8.5; p<0.05). Stent implantasyonundan ortalama 8.1 ay (2-18) sonra hastaların 25'inde (%59) kontrol kalp kateterizasyonu yapıldı. On iki hastada (%28) yapılan başarılı stent redilatasyonu oksijen saturasyonunu ortalama %13±3.6 (8-20) artırdı. Kırk iki hastanın 14'ünde başarılı biventriküler tamir, 16'sında çift yönlü kavopulmoner şant (Glenn ameliyatı) gerçekleştirildi. Dört hastada pulmoner arterlerin unifokalizasyonu ve modifiye Blalock-Taussig şant ameliyatı gerçekleştirildi. Glenn ameliyatı veya total tamir ameliyatı olan hastaların 12'sinde (%40) pulmoner arterioplasti uygulandı. Dört hastada stent yerleştirilmesi ile birlikte yapılan valvotomi veya valvuloplasti işlemi tam şifa ile sonuçlandı. Diğer dört hasta ise takip sırasında öldü.

Sonuç: Ağır siyanoze yenidoğan ve süt çocukluğu dönemimdeki hastalarda duktus arteriozusa stent takılması, bir sonraki palyatif cerrahi işleme veya total tamir ameliyatına kadar cerrahiye alternatif oluşturabilir. Etkin ve güvenli bir yöntem olmakla birlikte etkinliği altı ay içinde tedrici olarak azalmaktadır. Kritik pulmoner stenozlu veya uygun anatomik yapıya sahip intakt ventriküler septumlu pulmoner atrezili gibi seçilmiş bazı olgularda kalıcı çözüm sağlayabilir.

Anahtar sözcükler: Siyanoze yenidoğan ve süt çocuğu; duktus stenti; cerrahi.

Received: October 19, 2010 Accepted: December 14, 2010

Correspondence: Ali Rıza Karacı, M.D. Dr. Siyami Ersek Göğüs Kalp ve Damar Cerrahisi Eğitim ve Araştırma Hastanesi Pediatrik Kardiyoloji Kliniği, 34668 Üsküdar, İstanbul, Turkey. Tel: +90 216 - 542 44 44 e-mail: arkaraci@hotmail.com

The modified Blalock-Taussig shunt (MBTS) is mostly performed as a palliative operation in complex cyanotic heart disease with reduced pulmonary blood flow before definitive surgery. Despite more than 50 years' experience with MBTS, it has still high morbidity and mortality rates especially in neonates and in early infancy.^[1-4] In early infancy, it seems reasonable to keep the duct open rather than to intervene surgically. In 1992 Gibbs et al.^[5] first described maintaining duct patency by stent implantation during cardiac catheterization. Although early results were discouraging, several encouraging new reports have recently been published about ductal stent implantation with further improvement in balloon and stent technology in the last decade.^[5-11] In this regard, we aimed to assess the medium and long-term outcomes of transcatheter ductus arteriosus stenting in ductal-dependent or decreased pulmonary circulation newborns and infants to reveal the indications, timing, safety, efficacy and duration of transcatheter ductal stenting.

PATIENTS AND METHODS

Between July 2004 and February 2009, 45 patients with duct-dependent or diminished pulmonary circulation underwent cardiac catheterization. A total of 47 stents were implanted in 42 patients. The mean age at the time of the procedure was 66 days (range 3 days to 1.8 years) and the mean weight was 4.4±2.1 kg (range 2 to 13.2 kg). Fifty percent of the patients were neonates. Two patients were above the age of one year. One of these patients had tetralogy of Fallot-pulmonary atresia with increasing cyanosis despite a previous MBTS. The second patient had a diagnosis of pulmonary atresia with intact ventricular septum.

Detailed two-dimensional and Doppler echocardiographic examinations were performed on all patients before catheterization. Twenty-two patients were uni-ventricular- and 20 patients were biventricular-repair candidates. In cases where the patent ductus arteriosus (PDA) originated from the proximal part of the ascending aorta and had tortuosities, sharp bends or stenotic pulmonary arteries, surgical creation of MBTS was preferred.

Prostaglandin E1 infusion was stopped one hour before catheterization in all patients. Cardiac catheterization was performed under deep sedation. After femoral artery and vein cannulation 50 IU/kg intravenous heparin was infused in all patients and continued for 24 hours at 20 IU/kg/h in patients in whom stent implantation was successful. Hemodynamic parameters such as arterial blood pressure and aortic oxygen saturation were measured before and after stent implantation.

Aortic arch angiography in 90° lateral positions in all and 40° right anterior-oblique position in some patients

was obtained to evaluate the morphology of the PDA and pulmonary arteries. After duct size and dimensions were determined, a proper stent 1-2 mm longer than duct length was selected. Ductal stenting was retrograde via the femoral artery in 30 patients and antegrade using the femoral vein in 12 patients. Standard coronary stents (OCCAM: Netherland, EXOS PTCA stent, OSYPKA GmbH, Medizintechnik, Dusseldorf Germany, EUCATECH AG: Rheinfelden Germany) were used.

The follow-up was done by clinical examination, measurement of pulse oxymetric saturation, echocardiography evaluation and repeat cardiac catheterization at six to nine months (earlier if clinically indicated) after stent implantation.

Statistical analysis

The SPSS statistical program for Windows version 15.0 (SPSS Inc., Chicago, Illinois, USA) was used to perform data analysis. Data was expressed as mean ± standart deviation (SD), median, range and frequency percentage. A p value of <0.05 was considered to be statistically significant.

RESULTS

The stenting procedure was successfully completed in 42 of 45 patients (93.3%). It was unsuccessful in three. It was not possible to advance the stent-mounted balloon catheter through the PDA over the guide-wire in two patients. These patients had vertical and tortuous PDAs. In the third patient, the procedure was abandoned due to severe left pulmonary artery stenosis at the level of PDA insertion (Fig. 1).

The mean ductal length was 13.2±3.8 mm (range 7.8 to 23 mm). The mean stent length was 13.9±3.8 mm (range 8 to 23 mm). The great majority of stents implanted were 3.5 mm (n=20) and 4 mm (n=24) in diameter (89%). In three patients 3 mm stents were used. In five patients two stents were implanted in tandem in order to adequately cover the PDA length. The mean procedure time was 72 min (range 30 to 130 min) and mean fluoroscopy time was 22 min (range 9 to 41 min). Mean arterial oxygen saturation before stent implantation was 66.0% ±8.1 (range 42 to 75) and increased to 85.7% ±4.2 (range 75 to 95). The mean difference before and after stent implantation was 19.8% ±7.5, which was statistically significant (p<0.0001).

After the procedure, three patients remained intubated and committed to the ventilator for two days and discharged to the pediatric floor on the third day. The median hospitalization time was five days. There was no procedure-related death. One patient (with stent diameter of 3.5 mm) initially required anticongestive medications due to increased pulmonary blood flow.

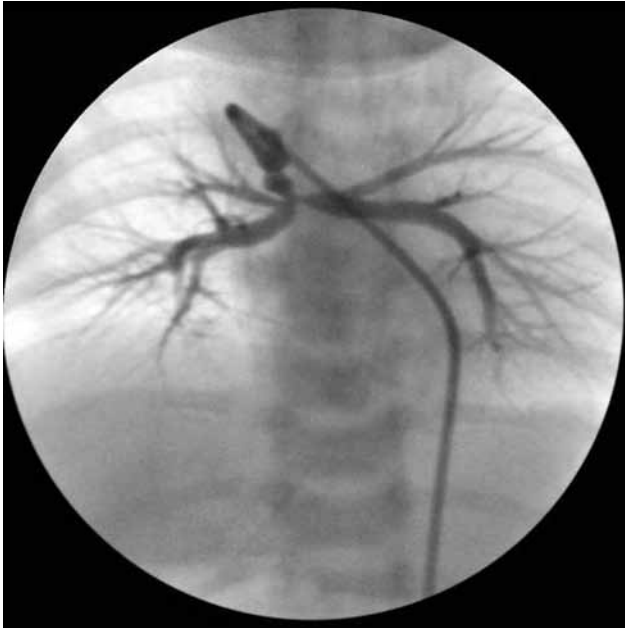

Fig. 1. Vertical and tortuous patent ductus arteriosus with stenosis at proximal part of left pulmonary artery.

Follow-up

During a mean follow-up of 34.5 ± 14.4 month (range 12-54 month), there was a significant reduction in pulse oxygen saturation after six months ($78.8\% \pm 8.5$) ($p < 0.05$). Control cardiac catheterization was performed in 25 (59%) patients at a mean of 8.1 months after the initial implantation (range, 2 to 18 months). Twelve patients (28.5%) underwent successful redilatation of the stent with an increase in mean oxygen saturations of $13\% \pm 3.6$ (range 8 to 20).

Two patients experienced very early reduction in oxygen saturations (2nd and 4th months respectively.) Redilatation of the stenosed stent was performed effectively in one of these patients. Redilatation was not effective in the other patient despite implantation of an additional stent due to stent kinking. A left MBTS was performed surgically.

In three patients with critical pulmonary stenosis and a patient with pulmonary atresia with intact ventricular septum PDA stenting was performed after valvuloplasty and surgical valvotomy (Fig. 2a, b). With improvement of right ventricular compliance over time, a biventricular repair was achieved in these patients without further surgical intervention. Fourteen of 42 patients have undergone surgery for biventricular repair, a bidirectional cavopulmonary shunt was performed in 16, and four patients underwent elective unifocalization of the pulmonary arteries and MBTS. During definitive surgery 12 of 30 patients required pulmonary arterioplasty. Four patients died at follow-up. One patient died because of septicemia forty days after the procedure. The second patient had asplenia and died due to pneumonia three months after. Two patients died after surgery: one had elective total repair and the other after pulmonary artery unifocalization and MBTS placement.

DISCUSSION

Advances in surgical techniques and postoperative care have significantly affected the management of cyanotic congenital heart disease. Primary complete repair is preferred in early infancy instead of palliative

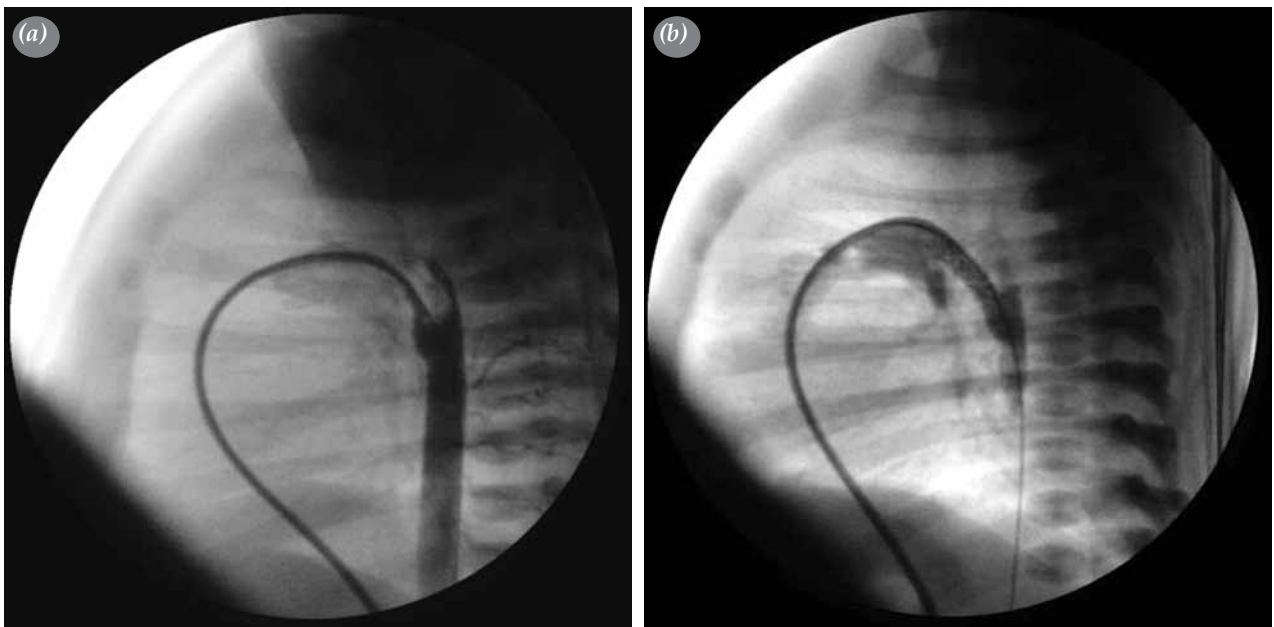


Fig. 2. (a) Lateral view of short and straight duct before stent implantation in a patient with critical pulmonary stenosis and hypoplastic right ventricle. **(b)** Lateral view of short and straight duct after stenting.

surgery. Patients with duct-dependent pulmonary circulation need urgent treatment in the early days of life to ensure pulmonary blood flow before ductal closure. Prostaglandin E1 infusion is generally effective in maintaining PDA patency. After achieving PDA patency, stenting can reduce the hospital stay and can be an alternative to Blalock-Taussig shunts with minimal complications.^[1,8] Both ductal stenting and surgical shunts are the procedures most performed in babies who have no other effective pulmonary blood supply than the duct. Patent ductus arteriosus stenting is as effective as modified BT shunts in promoting global pulmonary artery growth in congenital heart disease with duct-dependent pulmonary circulation.^[11,13,14] Compared to PDA stenting, in MBTS, pleural effusion, chylothorax, phrenic and vagal nerve palsy, and distortion and differential growth of the pulmonary arteries are well known complications.^[2-4] The morbidity and mortality after MBTS is higher in the neonatal period in comparison to childhood ages.^[1-3] On the other hand the stented arterial duct tended to be less durable than a conventional surgical shunt owing to ductal tissue prolapse through the stent struts and intra-stent endothelial hyperplasia, as already reported.^[6,7] Another study regarding endothelial hyperplasia within the stent confirmed that a complete layer of endothelium forms over the stent as early as one month.^[7] Endothelial proliferation becomes thicker, leading to progressive PDA occlusion. Stenosis usually develops within six months to one year after stenting. Surgical interventions such as the Glenn operation for univentricular hearts or total correction in biventricular hearts should be performed as early as possible. However it is possible to dilate the stent in some of these patients successfully to gain more time before surgery. Only very rarely do patients have ductal stent patency for more than two years. Stenosis of pulmonary arteries especially the left pulmonary artery can be seen after PDA stenting. The stent metal grid provokes neointimal proliferation within the stent and also accelerates fibrosis in the ductal tissue encircling the pulmonary arteries.^[12]

Patent ductus arteriosus is usually located between the left pulmonary artery and aorta. This might be the reason for a higher incidence of stenosis in the left pulmonary artery. At the time of surgical repair the PDA should be closed prior to cardiopulmonary bypass. With our growing surgical experience after PDA stenting, it is quite difficult to remove the stent due to its incorporation within the vascular endothelium. It is our practice to leave the stent in place and close it using surgical clips. If the stent protrudes into the pulmonary artery significantly the pulmonary end of the stent is than removed. When there is anatomical narrowing of the left or right pulmonary branch arteries the stenotic segment should be enlarged and reconstructed with a pericardial

patch together with removal of the residual stent grid in the PDA wall. Twelve patients (40%) required pulmonary arterioplasty during corrective surgery.

In conclusion, ductus arteriosus stenting can be a good alternative to surgery for initial palliation especially in infants who will need multiple surgeries. It is safe and feasible but its efficacy gradually lessens after six months owing to ductal tissue prolapse through the stent struts and intra-stent endothelial hyperplasia. In most of these patients stent redilatation is possible and can be done safely. In selected patients with critical pulmonary stenosis or pulmonary atresia-intact ventricular septum with favorable anatomy, PDA stenting with or without pulmonary valvuloplasty or valvotomy may provide a definitive cure. Those with very long and tortuous PDAs are not good candidates for stent implantation. Stenosis of the left or right pulmonary arteries are relative contraindications to PDA stenting but it may be considered especially in very young infants and newborns in whom surgical mortality and morbidity is high after pulmonary arterioplasty and MBTS.

Declaration of conflicting interests

The authors declared no conflicts of interest with respect to the authorship and/or publication of this article.

Funding

The authors received no financial support for the research and/or authorship of this article.

REFERENCES

1. Blalock A, Taussig HB. Landmark article May 19, 1945: The surgical treatment of malformations of the heart in which there is pulmonary stenosis or pulmonary atresia. By Alfred Blalock and Helen B. Taussig JAMA 1984;251:2123-38.
2. Fermanis GG, Ekganki AK, Salmon AP, Keeton BR, Shore DF, Lamb RK, et al. Twelve year experience with the modified Blalock-Taussig shunt in neonates. Eur J Cardiothorac Surg 1992;6:586-9.
3. Tamisier D, Vouhé PR, Vernant F, Lecá F, Massot C, Neveux JY. Modified Blalock-Taussig shunts: results in infants less than 3 months of age. Ann Thorac Surg 1990;49:797-801.
4. Sivakumar K, Shivaprakasha K, Rao SG, Kumar RK. Operative outcome and intermediate term follow-up of neonatal Blalock-Taussig shunts. Indian Heart J 2001;53:66-70.
5. Gibbs JL, Rothman MT, Rees MR, Parsons JM, Blackburn ME, Ruiz CE. Stenting of the arterial duct: a new approach to palliation for pulmonary atresia. Br Heart J 1992;67:240-5.
6. Rosenthal E, Qureshi SA, Tabatabaie AH, Persaud D, Kakadekar AP, Baker EJ, et al. Medium-term results of experimental stent implantation into the ductus arteriosus. Am Heart J 1996;132:657-63.
7. Gibbs JL, Uzun O, Blackburn ME, Wren C, Hamilton JR, Watterson KG. Fate of the stented arterial duct. Circulation 1999;99:2621-5.

8. Gewillig M, Boshoff DE, Dens J, Mertens L, Benson LN. Stenting the neonatal arterial duct in duct-dependent pulmonary circulation: new techniques, better results. *J Am Coll Cardiol* 2004;43:107-12.
9. Alwi M, Choo KK, Latiff HA, Kandavello G, Samion H, Mulyadi MD. Initial results and medium-term follow-up of stent implantation of patent ductus arteriosus in duct-dependent pulmonary circulation. *J Am Coll Cardiol* 2004;44:438-45.
10. Michel-Behnke I, Akintuerk H, Thul J, Bauer J, Hagel KJ, Schranz D. Stent implantation in the ductus arteriosus for pulmonary blood supply in congenital heart disease. *Catheter Cardiovasc Interv* 2004;61:242-52.
11. Hussain A, Al-Zharani S, Muhammed AA, Al-Ata J, Galal OM. Midterm outcome of stent dilatation of patent ductus arteriosus in ductal-dependent pulmonary circulation. *Congenit Heart Dis* 2008;3:241-9.
12. Coe JY, Olley PM. A novel method to maintain ductus arteriosus patency. *J Am Coll Cardiol* 1991;18:837-41.
13. Santoro G, Gaio G, Palladino MT, Iacono C, Carrozza M, Esposito R, et al. Stenting of the arterial duct in newborns with duct-dependent pulmonary circulation. *Heart* 2008;94:925-9.
14. Alwi M. Stenting the ductus arteriosus: Case selection, technique and possible complications. *Ann Pediatr Cardiol* 2008;1:38-45.