

Successful treatment of secondary aortoenteric fistula with a Valdoni-Strong's procedure

Sekonder aortaenterik fistülün Valdoni-Strong yöntemi ile başarılı tedavisi

Murat Akin,¹ Hakan Gökbayır,² Tefvik Tezcaner,³ Kadir Kılıç,² Ersin Özdemir,² Zafer Ferahköşe²

¹Department of General Surgery, Medicine Faculty of Gazi University, Ankara;
Department of ²General Surgery, ³Cardiovascular Surgery, Bayındır Medical Center, Ankara

Secondary aortoenteric fistula is one of the important causes of gastrointestinal bleeding following synthetic graft repair of the abdominal aorta. Secondary aortoenteric fistula is frequently observed after an aneurysm repair (from 0.3 up to 2% in the first 5 years), and associated with high rates of mortality and morbidity. The diagnosis of secondary aortoenteric fistula can be difficult. In this article, we present a case of gastrointestinal bleeding due to secondary aortoenteric fistula, successfully treated with Valdoni-Strong's procedure.

Key words: Gastrointestinal bleeding; secondary aortoenteric fistula; Valdoni-strong's procedure.

Aortoenteric fistulas are abnormal communications between the aorta and the bowel, most frequently resulting from prosthetic graft erosion. Fistulas between major vascular structures and the gastrointestinal tract are classified as either primary or secondary. Primary fistulae occur most commonly between an aortic aneurysm and the distal duodenum, while secondary aortoenteric fistulae (SAEF) occur following erosion of prosthetic material into the bowel after an aortic reconstruction. In 1956, Birch et al.^[1] reported the first SAEF following reconstruction of the abdominal aorta with a prosthetic graft.^[2]

Despite medical developments, SAEF cases are still associated with significant mortality and morbidity rates. The relationship between vascular graft complications and the gastrointestinal tract are appearing with varied clinical scenarios such as gastrointestinal hemorrhage or graft infection without hemorrhage. Here, we report a case of gastrointestinal bleeding due to SAEF treated with a Valdoni-Strong procedure.

Sekonder aortoenterik fistül, abdominal aortun sentetik greft ile tamiri sonrası meydana gelen ciddi gastrointestinal sistem kanamalarının önemli bir nedenidir. Anevrizma tamirinden sonra sekonder aortoenterik fistül sık görülür (ilk beş yılda %0.3'ten 2'ye kadar) ve yüksek morbidite ve mortalite oranları ile ilişkilidir. Sekonder aortaenterik fistülün tanısı zor olabilir. Bu yazıda sekonder aortoenterik fistül nedeniyle gastrointestinal sistem kanaması olan ve Valdoni-Strong yöntemi ile başarılı şekilde tedavi ettiğimiz bir olgu sunuldu.

Anahtar sözcükler: Gastrointestinal kanama; sekonder aortoenterik fistül; Valdoni-strong yöntemi.

OLGU SUNUMU

A 52-year-old man was admitted with the complaints of hematemesis, melena and weakness. The patient had a six-month-old graft at the infrarenal abdominal aorta, placed for saccular aortic aneurysm. At the time of this operation the inferior mesenteric artery was anastomosed to the aortic prosthesis with an end-to-side anastomosis and the graft was surrounded with native dilated aortic wall except for the area of the inferior mesenteric artery within. Because of repeated episodes of fatigue, palpitation, melena and weakness, along with fecal occult blood, the diagnosis was gastrointestinal tract bleeding. On admission, the blood pressure was 110 mmHg systolic and heart rate was 100 beats per minute. Initial laboratory examination revealed hemoglobin 9.8 g/dl white blood cell count of 15200/mm³, urea 26 mg/dl, creatinine 0.9 mg/dl, glucose 108 mg/dl, and protrombin time 19.9 second. Chest radiography and electrocardiogram were normal.

Received: Eylül 20, 2007 Accepted: March 4, 2008

Correspondence: Murat Akin, M.D. Gazi Üniversitesi Tıp Fakültesi Genel Cerrahi Anabilim Dalı, 06500 Beşevler, Ankara, Turkey.
Tel: +90 312 - 202 43 27 e-mail: makin@gazi.edu.tr

Upper gastrointestinal endoscopy demonstrated antral gastritis. An aortoenteric fistula was suggested by technetium-labeled red blood cell scintigraphy. Push-and-pull enteroscopy (double-balloon enteroscopy) was applied to identify the origin of bleeding. Aortic prosthesis was seen at the junction of the second and third part of the duodenum by double-balloon enteroscopy. Abdominal aortography and visceral arteriography showed normal abdominal aortic graft and blocked inferior mesenteric artery. Once the diagnosis of aortoenteric fistula without infection was made, the patient was accepted for surgical exploration. At surgery, a median incision was performed and adhesions were removed. In the retroperitoneal area, the distal duodenum had dense adhesions with the aortic graft at the site of the inferior mesenteric artery anastomosis. After dissection, we exposed the bowel defect and passed the fresh clot blocking between the distal duodenum and aortic graft. An approximately 2 cm² naked aortic graft was visible near the 2-3 cm² perforated third duodenal segment. Graft and surroundings showed no signs of infection (Fig. 1). Because the classical surgical exposure was not adequate for repair of the intestinal defect we decided to repair the defect from the right side and performed a Valdoni-Strong procedure. The duodenojejunal flexure was identified, and the proximal jejunum was retracted caudally while the peritoneum was incised along its left side. The large intestine from the cecum to the midpoint of the transverse colon was extensively mobilized to allow complete rotation of the ileal loops. The secondary root of the small-bowel mesentery was totally mobilized upward as far as the third portion of the duodenum. Division of the peritoneum lateral to its second and third part exposed the duodenum and the ligament of Treitz was divided along the anterior cranial aspect of the third and fourth portions of the duodenum (3-4 D). The 3-4 D and related mesentery could then be easily moved to the right of the superior mesenteric artery. Intestinal continuity was restored by

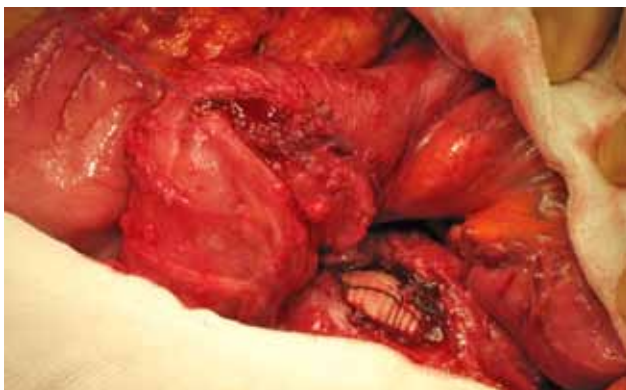

Fig. 1. Near the 2-3 cm² perforated and third duodenal segment were appeared.

an end-to-end duodenojejunal anastomosis.^[3] The graft over the aorta was covered with Dacron mesh (Fig. 2) by a cardiovascular surgeon.

The patient was discharged on the first postoperative week without any complication. On the second postoperative week wound healing seemed enough and no infection was observed. One-year check-up revealed no problem related to the diseases.

TARTIŞMA

Secondary aortoenteric fistula is a rare but fatal complication following abdominal aortic surgery. The incidence of SAEF after an aneurysm repair is relatively frequent (0.3 to 2%) in the first five-years, and associated with high rates of mortality and morbidity. The diagnosis can be difficult. A high index of suspicion is critical for successful diagnosis. The most frequently employed diagnostic investigation for SAEF is endoscopic examination, which is the procedure of choice for diagnosis and to exclude other causes of upper gastrointestinal bleeding.^[4,5] However, demonstration of the fistula is rare. Other conventional diagnostic tools of SAEF include abdominal computed tomography, aortography, and selective angiography, endoscopy with push enteroscopy, a wireless capsule endoscopy and technetium-labeled red blood cell scintigraphy.^[3]

There are two traditional approaches for the treatment of SAEF removal of the aortic prosthesis with aortic stump closure accompanied by extra-anatomic

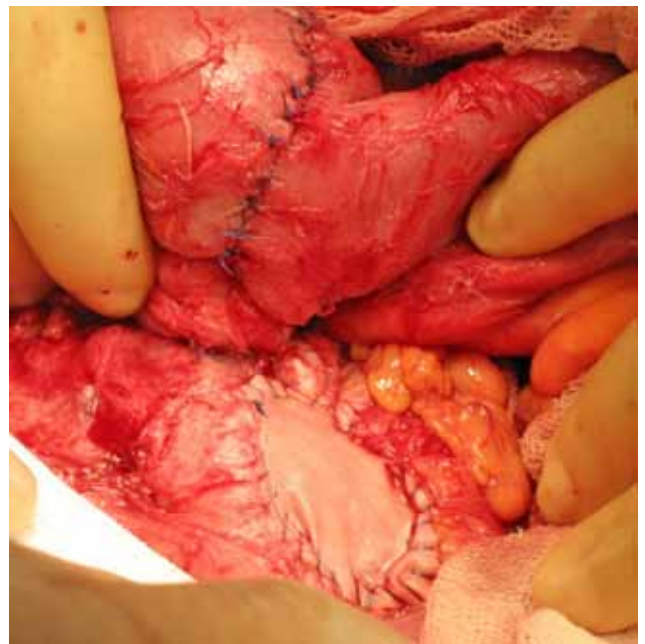


Fig. 2. Intestinal continuity was restored by an end-to-end duodenojejunal anastomosis. The graft over aorta was covered with Dacron mesh.

bypass and in-situ replacement of infected prosthetic graft. A literature review of studies analyzing this approach from the 1950s to the mid-1990s showed an average mortality of 36-48%.^[6-8] Endovascular treatment of SAEF provides another treatment option that may be particularly valuable in patients whose co-morbidities would preclude open surgery.^[7] The major problem with this technique is the high probability of prosthetic infection.

In our case, the defect in third duodenal segment was rather big (approximately 2-3 cm²). Since classical surgical exposure was not adequate for repair of the intestinal defect we decided to repair the defect from the right side and performed a Valdoni-Strong procedure. This procedure is a major surgery that can be applied with great success in appropriate cases. This surgical alternative should be taken into consideration for the patients with SAEF injury.

Declaration of conflicting interests

The authors declared no conflicts of interest with respect to the authorship and/or publication of this article.

Funding

The authors received no financial support for the research and/or authorship of this article.

REFERENCES

1. Birch L, Cardwell ES, Claytor H, Zimmerman SL. Suture-line rupture of a nylon aortic bifurcation graft into the small bowel. *AMA Arch Surg* 1956;73:947-50.
2. Yoshimoto K, Shiiya N, Onodera Y, Yasuda K. Secondary aortoenteric fistula. *J Vasc Surg* 2005;42:805.
3. Tocchi A, Mazzoni G, Puma F, Miccini M, Cassini D, Bettelli E, et al. Adenocarcinoma of the third and fourth portions of the duodenum: results of surgical treatment. *Arch Surg* 2003;138:80-5.
4. Maternini M, Tozzi P, Vuilleumier H, Von Segesser LK. Intra vascular ultra sound: one more tool to diagnose aorto-duodenal fistula. *Eur J Vasc Endovasc Surg* 2006; 32:542-4.
5. Limani K, Place B, Philippart P, Dubail D. Aortoduodenal fistula following aortobifemoral bypass. *Acta Chir Belg* 2005;105:207-9.
6. Kuestner LM, Reilly LM, Jicha DL, Ehrenfeld WK, Goldstone J, Stoney RJ. Secondary aortoenteric fistula: contemporary outcome with use of extraanatomic bypass and infected graft excision. *J Vasc Surg* 1995;21:184-95.
7. Shapiro M, Addis MD, Ellozy SH, Carroccio A, Teodorescu VJ, Marin ML. Successful endovascular treatment of bleeding aortoenteric fistula: a case report. *Ann Vasc Surg* 2006; 20:817-9.
8. Cendan JC, Thomas JB 4th, Seeger JM. Twenty-one cases of aortoenteric fistula: lessons for the general surgeon. *Am Surg* 2004;70:583-7.